

HC 2CCN Z

[www.libtool.com.cn](http://www.libtool.com.cn)

[www.libtool.com.cn](http://www.libtool.com.cn)

J. B. Williams

[www.libtool.com.cn](http://www.libtool.com.cn)

[www.libtool.com.cn](http://www.libtool.com.cn)

[www.libtool.com.cn](http://www.libtool.com.cn)

**HANDBOOK  
OF  
DISEASES OF THE RECTUM**

[www.libtool.com.cn](http://www.libtool.com.cn)

[www.libtool.com.cn](http://www.libtool.com.cn)

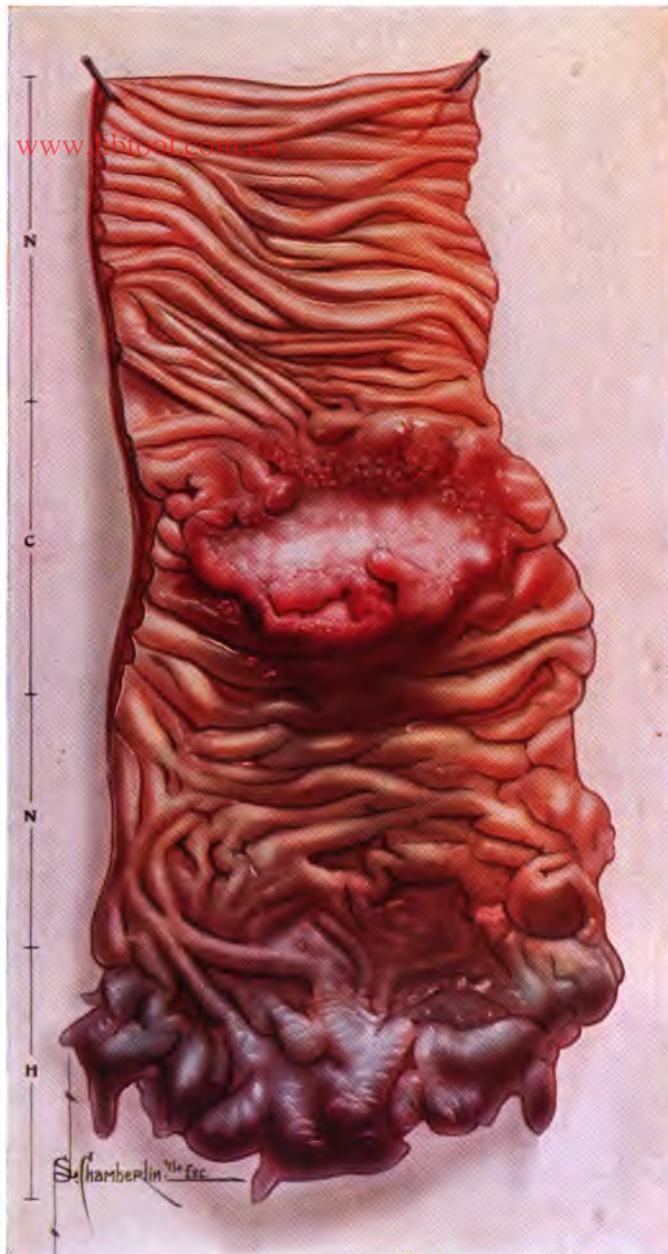


PLATE I.

Cancer of the rectum complicating prolapsing hemorrhoids. Illustrating the importance of proctoscopic examination in all cases of apparently minor anorectal conditions.

- C. Cancer.
- N. Normal rectal mucous membrane.
- H. Hemorrhoids.



# HANDBOOK OF DISEASES

OF THE

# RECTUM

BY

LOUIS J. HIRSCHMAN, M.D., F.A.C.S.

VICE-CHAIRMAN, SECTION ON GASTRO-ENTEROLOGY AND PROCTOLOGY, A.M.A.; EX-PRESIDENT AMERICAN PROCTOLOGIC SOCIETY; PROFESSOR OF PROCTOLOGY, DETROIT COLLEGE OF MEDICINE; PROCTOLOGIST, HARPER HOSPITAL; MAJOR, M.C., U.S.A. (HONORABLY DISCHARGED), DETROIT, U.S.A.

*WITH TWO HUNDRED TWENTY-THREE ILLUSTRATIONS,  
MOSTLY ORIGINAL, AND FOUR COLORED PLATES*

THIRD EDITION REVISED AND REWRITTEN

ST. LOUIS  
C. V. MOSBY COMPANY

1920

[www.libtool.com.cn](http://www.libtool.com.cn)

COPYRIGHT, 1913, 1920, BY C. V. MOSBY COMPANY.

16. J. 16.

*Press of*  
*C. V. Mosby Company*  
*St. Louis*

To the Memory of my Father  
**Frederick Louis Hirschman, M. D.,**

A country doctor whose untimely death was a sacrifice to the duties of that overworked and wholly unappreciated class of our profession—the Country Doctor; this work is affectionately dedicated by

The Author

[www.libtool.com.cn](http://www.libtool.com.cn)

## PREFACE TO THIRD EDITION

The kind reception accorded the previous editions of this work necessitated a new edition several years ago. The author was at work on this task when this country entered the World War. His early departure on overseas duty with the American Expeditionary Forces disrupted his plans. Now that we are again at peace with the world, the revision has come to its completion.

So many of the methods described have been so satisfactorily employed by the members of the profession that the few changes in technic are merely refinements. A large number of new illustrations have been added to bring these out in more detail. The whole text has been made as free from technical terms as is possible in a work of this type. The scope of this volume has been kept within its original limitations while the field of local anesthesia continues to broaden. This, it would seem, is ample justification for the original publication of this work.

The author wishes to express his grateful appreciation to those members of the profession whose insistence is responsible for this edition and to the publishers and all others whose cooperation has always been loyally bestowed.

LOUIS J. HIRSCHMAN.

Kresge Building  
Detroit, Michigan.

## PREFACE TO SECOND EDITION

The very generous reception which was given this book when first published was the best evidence that the profession was in need of such a work.

The field of local anesthesia in anorectal surgery is well established, and in surgery generally is rapidly extending. The importance of a clear understanding of the diagnosis and treatment of anorectal diseases has forced itself upon the faculties of medical colleges and universities, with the result that an increasing number are giving regular courses in proctology.

With the endeavor to make this work more valuable to the general practitioner, and to the student, who is the general practitioner of the future, this work has been completely revised. Operative technic has been further simplified, new diagnostic methods added, the use of quinin and urea anesthesia described; the value of radiography in proctology illustrated by many plates; numerous new illustrations, including two new color plates, have been added to more clearly assist the reader to follow out the various procedures described in the text.

In the preparation of this edition the author wishes to extend his thanks to Dr. P. M. Hickey, Roentgenologist to Harper Hospital, who made all of the radiographs, and to the artists Tom Jones of St. Louis, and Norman Saxon Chamberlin of Detroit.

The author also wishes to express his renewed appreciation of the efforts of all those who assisted in no small degree in making the first edition possible.

LOUIS J. HIRSCHMAN.

## PREFACE TO FIRST EDITION

In presenting this book to the medical profession, the author does so with the feeling that it will be of some assistance to that great mass who were as unfortunate as he in their early college training in the special field of proctology. Diseases of the rectum and anus have been, and still are, in a great many colleges, dismissed with a single lecture or two, delivered as a part of the course on general surgery. The young graduate in medicine leaves his Alma Mater with a hazy idea that occasionally patients may suffer from "piles or fistula," and an operation under general anesthesia is their only hope of relief.

The fact that the profession as a whole has been so remiss in the treatment of patients suffering from rectal diseases has left the field in the past to the quack and the irregular.

A few earnest practitioners, however, in different parts of the country, gradually discovered that there was something more to rectal diseases than the treatment of "piles and fistula" and began the scientific study of the lower bowel with the result that today the special field of proctology is firmly established with conscientious workers in all parts of the world. The results of the work of some of these men have been given to the world in the shape of most complete textbooks on the subject. In many of these works, however, the subject has been treated from the standpoint of the specialist in rectal diseases, and written for those who wish to follow that line of practice.

With the introduction of local anesthesia into the treatment of diseases of the rectum and anus, a new field of work has been opened. Those patients suffering from many diseases of this region, who have sought the advice and care of the irregular and the advertising quack, have done so on account of their dread of hospitals, general anesthesia, and "the knife."

In order that the general practitioner may be qualified to diagnose and treat his patient who is suffering from anorectal diseases as scientifically and as successfully as he does affections of other organs and localities, the author presents the results of his experiences in the treatment of anorectal diseases.

The diagnosis of disease originating in this region has been dwelt upon to emphasize the importance of early examination. Illustrations, for the most part original, have been used wherever it has been thought necessary to supplement the text for the sake of clearness.

Non-surgical methods are described in those conditions where they have been found of value, and the technic of operative measures under local anesthesia has been made as simple as possible. Only those conditions which are amenable to treatment in office practice have been discussed, and the limitations of office treatment clearly set forth. For information regarding those operative measures that are only applicable under general anesthesia, and the consideration of those diseases whose treatment requires confinement in bed, the reader is referred to the several complete works on proctology that are now available.

Those physicians living and practicing in the Southern states, particularly, will appreciate the inclusion in this work of a chapter on Dysentery. The author has been exceedingly fortunate in securing the services of a man to prepare this chapter, than whom there is no one better posted on the subject: Dr. John L. Jelks, of Memphis, Tenn., President of the American Proctologic Society.

Inasmuch as a very important index to the condition of the entire digestive tract and its functions is found in the excretions; and the fact that the examination of the stools, which is fully as important as the urinary analysis, has been too long neglected, a chapter on the examination of the feces has also been included. Dr. George W. Wagner, of Detroit, Attending Physician to Harper Hospital, Gastroenterologist to the German Polyclinic, and Clinical Professor of Medicine in the Detroit College of Medicine, has kindly contributed this chapter, and the author considers himself extremely fortunate in securing the assistance of so well qualified a man.

To the above named gentlemen; to Dr. Robert C. Jamieson, of Detroit, Dermatologist to Harper Hospital Polyclinic, who made the excellent photographs under the author's direction; to Mr. James T. Nolan, the artist of Western Reserve University Medical Department, of Cleveland, O., who made all of the drawings; to the J. F. Hartz Co., of Detroit, who furnished the illustrations of many of the surgical instruments; to the publishers for their hearty and willing cooperation; and lastly, to the many members of the medi-



cal profession through whose courtesy the author has been able to treat the large number of cases, the results of his experience with them having furnished the basis for the preparation of this work—the author extends his sincere and heartfelt thanks.

Besides the results of his own experience, the author has availed himself of the privilege of consulting many of the recent works and textbooks on the subject of proctology, among which may be mentioned those of Tuttle, Gant, Matthews, Martin, Ball, Cripps, Wallis, and Hertz, as well as many articles by other authors appearing in the current literature of the day.

If the author has succeeded in so simplifying the diagnosis and treatment of many of the more common diseases of the rectum and anus that this work will be of some assistance to the busy general practitioner in his everyday work, and has assisted in even a small degree in broadening the scope of the use of local anesthesia in this field, he will feel that he has accomplished all that he set out to do. This modest work does not pretend or aspire to take the place of a textbook on the whole subject of proctology, but if it will find a place on the physician's desk as a working handbook, the author feels that it will fill a long-felt want.

LOUIS J. HIRSCHMAN.

[www.libtool.com.cn](http://www.libtool.com.cn)

## CONTENTS

### CHAPTER I

#### ANATOMY

Anus—Anal Canal—Rectum—Levator Ani—Ischiorectal Fossa—Sigmoid Colon—Blood Supply—Lymphatics—Nerve Supply . . . . .	21-33
---	-------

### CHAPTER II

#### SYMPTOMS WHICH SHOULD CALL ATTENTION TO THE RECTUM

Pain—Tenderness—Spasm—Bleeding—Itching—Protrusions—Elevations —Discharge—Constipation—Diarrhea—Altered Stools—Sacral Back- ache—Shooting Pains down the Limbs—Crampy, Painful, and Scanty Menstruation—Urinary Disturbances—General Disturbances —Anemia—Restlessness in Children—Foreign Body . . . . .	34-39
--	-------

### CHAPTER III

#### EXAMINATION OF THE PATIENT

Rooms and Furniture—Examination . . . . .	40-69
---	-------

### CHAPTER IV

#### CONSTIPATION AND OBSTIPATION

Physiology of Defecation—Etiologic Factors—Diagnosis—Treatment— Obstipation . . . . .	70-105
--	--------

### CHAPTER V

#### FECAL IMPACTION

Causes—Symptoms—Diagnosis—Treatment . . . . .	106-109
---	---------

### CHAPTER VI

#### PRURITUS ANI

Causes—Diagnosis—Treatment . . . . .	110-126
--------------------------------------	---------

### CHAPTER VII

#### ANAL FISSURE AND ULCER

Cause—Diagnosis—Treatment—Anal Ulcer . . . . .	127-143
--	---------

### CHAPTER VIII

#### ABSCESS OF THE ANORECTAL REGION

Tegumentary Abscess—Subtegumentary or Marginal Abscess—Sub- mucous Abscess—Ischiorectal Abscess . . . . .	144-156
--	---------

## CHAPTER IX

## ANAL FISTULA—ANAL SINUS

Varieties of Fistula—Simple Complete Fistula—External Sinus—Internal Sinus—Submucous Tract—Submucous or Muco-cutaneous Fistula—Injection of Bismuth Paste—Anal Fistula in the Tuberculous Patient . . . . .	157-182
---	---------

## CHAPTER X

## HEMORRHOIDS

Varieties—Causes—Symptoms—Diagnosis—Treatment . . . . .	183-227
---	---------

## CHAPTER XI

## RECTAL POLYPI—HYPERTROPHIED ANAL PAPILLÆ—CRYPTITIS

Polypus—Hypertrophy of the Anal Papillæ—Cryptitis . . . . .	228-239
---	---------

## CHAPTER XII

## PROCTITIS AND SIGMOIDITIS

Acute Proctitis and Sigmoiditis—Chronic Proctitis and Sigmoiditis . . . . .	240-252
---	---------

## CHAPTER XIII

## DYSENTERY

General Considerations—Acute Catarrhal Dysentery or Sporadic Bacillary Dysentery—Diphtheritic Dysentery—Secondary Diphtheritic Dysentery—Amoebic Dysentery—Chronic or Secondary Amoebic Dysentery . . . . .	253-293
---	---------

## CHAPTER XIV

## PROLAPSE OF THE RECTUM IN CHILDREN

Etiology—Symptoms—Diagnosis—Treatment . . . . .	294-301
---	---------

## CHAPTER XV

## TECHNIC OF THE USE OF LOCAL ANESTHESIA IN THE TREATMENT OF ANORECTAL DISEASES

Anesthetic Agents—Instruments—General Technic—Technic in Special Cases . . . . .	302-320
--	---------

## CHAPTER XVI

## LIMITATIONS OF LOCAL ANESTHESIA AND OFFICE TREATMENT AND INDICATIONS FOR OTHER MEASURES

General Contraindications to Local Anesthesia—Cancer of the Rectum—Ulceration of the Bowel—Stricture of the Rectum—Rectal Abscesses—Anal Fistula—Hemorrhoids—Prolapse of the Rectum—Removal of Concretions—Fistulæ Communicating with other Organs . . . . .	321-332
--	---------

## CHAPTER XVII

## THE FECES AND THEIR CLINICAL EXAMINATION

General Characteristics of Feces—Clinical Examination of the Stools— Microscopic Examination—Chemical Examination—Clinical Signifi- cance of Test—Animal Parasites—Character of Feces in Certain In- testinal Affections . . . . .	333-360
Symptom Index . . . . .	361-363
Index of Authorities . . . . .	365-366
Index . . . . .	367-378

www.libtool.com ILLUSTRATIONS

Plate I. Cancer of the rectum complicating prolapsing hemorrhoids, Frontispiece	
Plate II. Blood vessels of the rectum . . . . .	Facing page 32
Plate III. Giant sigmoid colon . . . . .	Facing page 78
Plate IV. Section of intestine below ulceration . . . . .	Facing page 272
FIG.	PAGE
1. Rectum and anal canal in the male . . . . .	22
2. Rectum hardened in formalin . . . . .	24
3. Proctoscopic view of rectal valves . . . . .	26
4. Muscles and nerves of the male pelvic outlet . . . . .	28
5. Simple form of instrument sterilizer . . . . .	41
6. Small instrument and dressing sterilizer . . . . .	41
7. Operating-table . . . . .	42
8. Electric magnifying headlight . . . . .	43
9. External inspection . . . . .	44
10. Method of applying lubricant from collapsible tube . . . . .	45
11. Incorrect method of digital examination . . . . .	46
12. Correct method of digital examination . . . . .	47
13. Vaginal eversion of the anus . . . . .	48
14. Another method of everting anus . . . . .	49
15. Amount of possible eversion of anal tissues . . . . .	50
16. Method of examining the coccyx with one hand . . . . .	51
17. Rectoabdominal bimanual examination . . . . .	52
18. Rectoabdominal palpation . . . . .	53
19. Palpation of rectum through posterior vaginal wall . . . . .	53
20. Ischiorectal abscess . . . . .	54
21. Squatting position . . . . .	55
22. Three-ounce, all-rubber bulb syringe . . . . .	55
23. Knee-elbow position . . . . .	56
24. Knee-shoulder position . . . . .	56
25. Author's anoscope with oblique opening . . . . .	57
26. Author's adjustable fenestrated anoscope . . . . .	57
27. Silver wire probe . . . . .	58
28. Long alligator forceps . . . . .	58
29. Kelly anoscope . . . . .	59
30. Method of using author's fenestrated anoscope . . . . .	60
31. Author's modification of Martin proctoscope . . . . .	61
32. Tuttle pneumatic proctoscope . . . . .	61
33. Exaggerated lithotomy position . . . . .	62
34. Kelly sigmoidoscope . . . . .	63
35. Sigmoidoscope with author's tilting obturator . . . . .	63
36. Adjustable proctoscopic mirror . . . . .	64
37. Inverted or Hanes' position . . . . .	64
38. Improvised arrangement for obtaining inverted position . . . . .	65

FIG.	PAGE
39. Imperforate anus in one-year-old child . . . . .	66
40. Atresia ani vaginalis (complete) . . . . .	67
41. Atresia ani vaginalis (incomplete) . . . . .	68
42. Normal segmentation of colon up to splenic flexure . . . . .	71
43. Overdistention of ascending cecum and transverse colon . . . . .	72
44. Megacolon . . . . .	74
45. Megacolon, after removal . . . . .	76
46. Coloptosis with angulation and adhesion of transverse colon . . . . .	77
47. Bismuth meal passing from ileum to cecum . . . . .	80
48. Whole colon injected with bismuth . . . . .	81
49. Ptosis of cecum . . . . .	82
50. Ptosis of cecum . . . . .	83
51. Hypertrophy of pelvic colon due to adhesions . . . . .	88
52. Hypertrophy of transverse colon . . . . .	89
53. Congenital dilatation of pelvic colon and rectum in five-year-old boy . . . . .	91
54. Spastic descending and pelvic colon . . . . .	92
55. Stricture at recto-sigmoidal juncture . . . . .	93
56. Stricture near splenic flexure due to carcinoma . . . . .	94
57. Author's dilating rectal massage bag . . . . .	95
58. Author's dilating rectal massage bag (deflated and inflated) . . . . .	95
59. Position for author's method of rectal massage . . . . .	97
60. Author's four-inch operating proctoscope . . . . .	101
61. Author's rubber ligature carrier . . . . .	101
62. Author's angular rectal scissors . . . . .	101
63. Technic of author's operation for rectal valvotomy . . . . .	102
64. Author's rubber ligature operation . . . . .	103
65. Pruritus ani . . . . .	111
66. Pruritus ani, showing excoriation . . . . .	112
67. External hemorrhoids with pruritus ani . . . . .	114
68. A simple and satisfactory rectal dressing . . . . .	121
69. Sharp-pointed scissors curved on the flat . . . . .	122
70. T-forceps . . . . .	122
71. Ball's operation for pruritus ani—lines of incision . . . . .	123
72. Ball's operation for pruritus ani—dissecting the flap . . . . .	124
73. Ball's operation for pruritus ani—area of anesthesia . . . . .	125
74. Krouse's radiating incisions for Ball's operation . . . . .	126
75. Typical site of anal fissure . . . . .	127
76. Traumatic fissure . . . . .	128
77. Anal fissure with sentinel pile . . . . .	129
78. Anal fissure, showing sentinel pile . . . . .	130
79. Multiple anal fissure . . . . .	131
80. Anal fissure from crypt of Morgagni . . . . .	132
81. Applying ointment to anus from lead tube . . . . .	133
82. Application of carbolic acid at point of puncture . . . . .	134
83. Injection of anesthetic for fissurectomy at usual site . . . . .	135
84. Injection of anal fissure . . . . .	136
85. Anesthesia and sphincteric relaxation complete for fissurectomy . . . . .	137

FIG.	PAGE
86. Fissure grasped ready for excision . . . . .	138
87. Simple incision of fissure . . . . .	139
88. Sharp-toothed or pronged forceps . . . . .	140
89. Anal fissure complicating internal hemorrhoids . . . . .	140
90. Author's technic for incision of anal fissure . . . . .	141
91. Posterior anal ulcer . . . . .	142
92. Operation for excision of anal ulcer . . . . .	143
93. Anorectal abscesses . . . . .	145
94. Circumanal ulceration, infective . . . . .	146
95. Characteristic sitting posture in anorectal disease . . . . .	148
96. Proctoscopic view of submucous abscess . . . . .	151
97. De Vilbiss rectal speculum . . . . .	152
98. Line of incision for ischioanal abscess . . . . .	153
99. Anorectal fistula—anal sinus . . . . .	157
100. Direct complete anal fistula . . . . .	160
101. Angular fistulous tract . . . . .	160
102. Glass syringe for injecting bismuth paste into fistulous openings . . . . .	161
103. Injection of fistulous tracts with bismuth paste . . . . .	162
104. Radiograph of simple direct complete fistula . . . . .	163
105. Complicated complete fistula . . . . .	164
106. Multiple fistula communicating with urethra . . . . .	165
107. Soft silver probe passed through complete fistula . . . . .	166
108. Grooved director . . . . .	167
109. Principal instruments for anorectal surgery under local anesthesia . . . . .	168
110. Fistula with three external openings . . . . .	169
111. Incision for simple direct anal fistula . . . . .	170
112. Soft silver probe passed through fistula . . . . .	171
113. Author's technic for removing fistulous tract . . . . .	173
114. Multiple anorectal fistulæ . . . . .	174
115. Excision of fistulous tract . . . . .	175
116. Fistulous area dissected clean . . . . .	175
117. Wound lightly packed with dry gauze . . . . .	176
118. Extent to which dissection must be carried in multiple fistulæ . . . . .	178
119. Technic of ligature operation for fistula . . . . .	179
120. Silver wire looped through fistula and fastened . . . . .	180
121. Author's cryptotome with adjustable handle . . . . .	181
122. Interno-external hemorrhoids . . . . .	184
123. Section of interno-external pile . . . . .	184
124. Acute external thrombotic hemorrhoid . . . . .	185
125. Ulcerating acute thrombotic hemorrhoid . . . . .	187
126. Acute thrombotic hemorrhoids of unusual size . . . . .	188
127. External thrombotic hemorrhoids . . . . .	188
128. External cutaneous hemorrhoids . . . . .	189
129. Granulomata (syphilitic) . . . . .	190
130. Single prolapsing internal hemorrhoid . . . . .	191
131. Prolapsing internal hemorrhoids . . . . .	192



FIG.	PAGE
132. Prolapsing internal hemorrhoids . . . . .	193
133. Prolapsing internal hemorrhoids . . . . .	194
134. Prolapsing internal hemorrhoids exposed ready for operation . . . . .	195
135. Bivalve rectal speculum . . . . .	196
136. Circumanal injection of anesthetic completed . . . . .	196
137. Showing complete anesthesia and sphincteric relaxation . . . . .	197
138. Injection of interno-external hemorrhoid . . . . .	199
139. Injection of prolapsing hemorrhoid . . . . .	200
140. Prolapsing interno-external hemorrhoids anesthetized . . . . .	201
141. Distention completed, showing internal hemorrhoids presenting . . . . .	202
142. Injection of prolapsing pedunculated internal hemorrhoids . . . . .	203
143. Perfect exposure of operative field . . . . .	204
144. Grasping hemorrhoid with author's hemorrhoid forceps . . . . .	205
145. Author's hemorrhoidal forceps . . . . .	206
146. Passing submucous ligature . . . . .	207
147. Ligature tied with a long and a short end . . . . .	208
148. Rectal retractor modified from Sims' speculum . . . . .	209
149. Author's blunt-pointed ligature carrier . . . . .	209
150. All ligatures tied in situ . . . . .	210
151. Internal hemorrhoid anesthetized . . . . .	211
152. Excision of hemorrhoidal tissues, conserving mucosa . . . . .	212
153. The blood supply controlled by four ligatures . . . . .	213
154. Long end of ligature tied in needle . . . . .	214
155. All hemorrhoids ligated ready to be sutured . . . . .	215
156. Long ends of ligatures tied to short ends . . . . .	216
157. Edges in position for suturing . . . . .	217
158. Technic of suturing . . . . .	218
159. Completing the suturing . . . . .	219
160. Skin closure . . . . .	221
161. Operation completed . . . . .	222
162. Distention of external hemorrhoids with sterile water . . . . .	223
163. Anal polyp . . . . .	229
164. Rectal polypus . . . . .	230
165. Specimen of multiple colonic polyposis . . . . .	232
166. Specimen from total colectomy for multiple polyposis . . . . .	233
167. Hypertrophy of anal papillæ and crypts of Morgagni . . . . .	234
168. Hypertrophy anal papillæ . . . . .	235
169. Proctoscopic view of hypertrophied anal papillæ . . . . .	236
170. DeVilbiss spray tube . . . . .	241
171. Author's rectal spray tube . . . . .	242
172. Spraying rectum in knee-shoulder position . . . . .	243
173. Ulcer of the rectum . . . . .	244
174. <i>Amœba histolytica</i> . . . . .	263
175. <i>Amœba coli mitis</i> . . . . .	264
176. Slough of mucous membrane . . . . .	268
177. Edge of intestinal ulcer . . . . .	269

FIG.	PAGE
178. Dysenteric ulceration on the valves of Houston . . . . .	270
179. Photograph of case . . . . .	275
180. The Jelks' irrigating tube . . . . .	286
181. Position for irrigation of colon with Jelks' tube . . . . .	287
182. Position for introduction of colon tube . . . . .	289
183. Method of application of solutions to rectum and sigmoid . . . . .	291
184. Method of spraying rectum and sigmoid . . . . .	292
185. Prolapse of the rectum, third degree . . . . .	295
186. Prolapse of the rectum, first degree . . . . .	297
187. Aseptic all-glass hypodermic syringe . . . . .	307
188. Aseptic all-metal syringe . . . . .	307
189. First step—application of carbolic acid . . . . .	309
190. Point of puncture for injecting local anesthetics . . . . .	310
191. Quadrants of the anus . . . . .	311
192. Amount of distention for anesthetizing sphincters . . . . .	312
193. Point of puncture for anesthetizing sphincterian nerves . . . . .	313
194. Producing dilatation of sphincters with vibrator . . . . .	314
195. Amount of dilatation of sphincter . . . . .	315
196. Anesthesia and relaxation produced by the technic outlined . . . . .	316
197. Wales rectal bougie . . . . .	319
198. Proctoscopic view of carcinoma . . . . .	323
199. Carcinoma after removal by operation . . . . .	324
200. Cancer of the rectum, with multiple fistulae . . . . .	325
201. Cancer of the rectum . . . . .	326
202. Cancer of the rectum, interior view . . . . .	327
203. Sulphid of bismuth crystals from the stools . . . . .	335
204. Collective view of the feces . . . . .	336
205. Muscle remnants in feces . . . . .	339
206. Steele's modification of Strassburger's fermentation apparatus . . . . .	340
207. Mucus shreds . . . . .	341
208. Mucus shreds after the addition of acetic acid . . . . .	341
209. Hematoidin crystals from alcoholic stools . . . . .	343
210. Acholic stools . . . . .	343
211. Gallstones . . . . .	346
212. <i>Amœba coli</i> . . . . .	348
213. <i>Balantidium coli</i> . . . . .	348
214. <i>Ascaris lumbricoides</i> . . . . .	350
215. <i>Oxyuris vermicularis</i> . . . . .	351
216. <i>Oxyuris vermicularis</i> . . . . .	352
217. <i>Ankylostomum duodenale</i> . . . . .	353
218. <i>Trichocephalus dispar</i> . . . . .	354
219. <i>Trichina</i> . . . . .	355
220. <i>Anguillula stercoralis</i> . . . . .	355
221. Head of <i>Tœnia solium</i> . . . . .	356
222. <i>Tœnia saginata</i> . . . . .	357
223. Head of <i>Bothriocephalus latus</i> . . . . .	358

# DISEASES OF THE RECTUM

## CHAPTER I

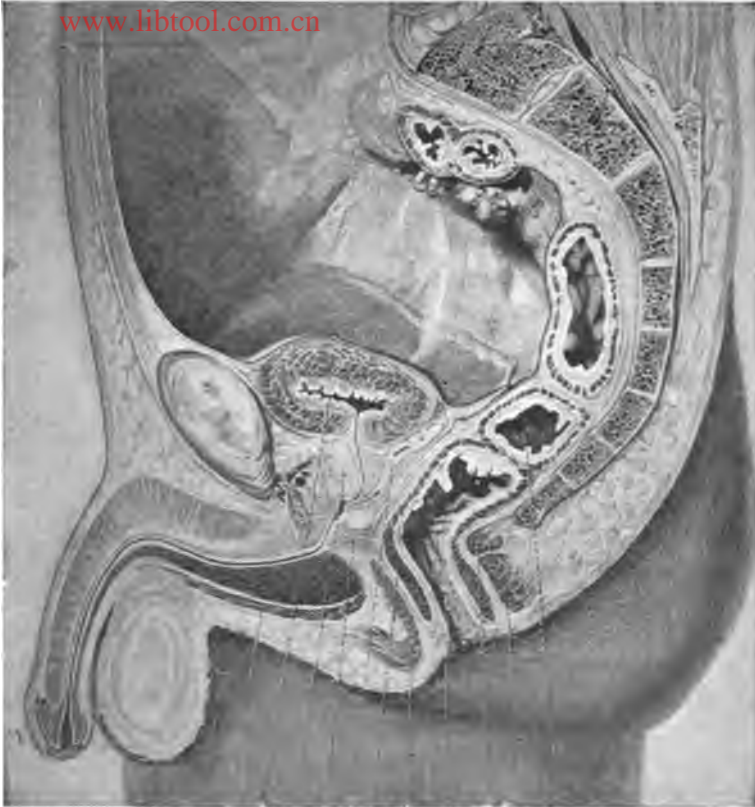
### ANATOMY

It is not the intention in a work of this scope to go into minor anatomical details in the description of the anus and rectum. It is essential, however, that one who intends to treat even the most common and uncomplicated diseases of the anus and rectum should have a practical working knowledge of the gross anatomy of the anorectal region.

In reversing the usual order of describing these organs, the author starts with the anus first, because it is to the anal orifice that one's attention is first directed in proceeding to examine or operate for diseased conditions affecting these organs. It appears to the author, therefore, that the anatomy of these organs should be described in the order in which they are met: from without, inward.

### ANUS

The anus is an oval aperture, longitudinal when in repose, situated at a point equidistant from the tuberosities of the ischii, and about one inch anterior to the tip of the coccyx. In the female it is situated a little more anteriorly than in the male. The anus is surrounded by integument which is slightly darker than the surrounding skin. The skin around the anus is arranged in radiating folds caused by the contraction of the *corrugator cutis ani* muscle. The circumanal integument contains sweat glands, sebaceous glands, and hair follicles. The circumference of the anal orifice varies from an inch to an inch and three quarters, but it may be dilated to a circumference five or six times greater.



B.C. . . . . . R.  
 B. . . . . . S.E.  
 P. . . . . . P.R.  
 R.U. . . . . . A.  
 S.V. . . . . .  
 S.I. . . . . .  
 S.E.

Fig. 1.—Rectum and anal canal in the male—longitudinal section. (Section made by Professor A. F. Dixon of a formalin-hardened male pelvis.)—After Ball.

- B. C. Bulbocavernosus muscle.
- B. Bladder.
- P. Prostate gland.
- R. U. Rectourethralis muscle.
- S. V. Seminal vesicle with ejaculatory duct below.
- S. I. Internal sphincter muscle.
- S. E. External sphincter muscle.
- A. Anus.
- P. R. Puborectalis muscle, around which the rectum bends sharply, to be continued into the anal canal.
- R. Rectum.

## ANAL CANAL

The anal canal extends from the point at which the sides of the anal aperture first appose to the linea dentata or lower edges of the semilunar valves, which guard the openings of the crypts of Morgagni. Its depth varies from two thirds of an inch to an inch and a quarter. It is lined by a membrane composed of thin transitional epithelium, gradually changing in histological formation from the stratified cells of true skin at the anus to the goblet-cells of mucous membrane at its juncture with the rectum at the linea dentata, or anorectal line. Surrounding the lining membrane is one of cellular tissue, and beneath this the muscular layer composed of the external sphincter, a few fibers of the levator ani, and the lower portion of the internal sphincter. The dimensions of the anal canal, when in repose or dilated, are slightly smaller than those of the anus itself in like condition. The lining membrane presents to the eye a pinkish-red shining appearance, in some cases a more or less purplish hue (Fig. 1).

**External Sphincter Muscle.**—This is the most important muscle with which we have to deal from a surgical point of view, and is the principal muscular structure which goes to form the anal canal. It is composed of circular and longitudinal fibers. The longitudinal arise from the lower end and posterior aspect of the coccyx, and surrounding the anus in an elliptical manner, meet and are inserted into the central tendon of the perineum. The circular fibers are more superficial, entirely surrounding the anal canal. The muscle is normally in a state of contraction, keeping the anus closed, and it is of great importance in the voluntary control of the act of defecation. Its nerve supply is derived from the *third* and *fourth sacral* and *superficial branch* of the *internal pudic* and a filament of the *fifth* and *sixth sacral*, known as the *lesser sphincterian nerve*. This nerve is of extreme importance in the production of local anesthesia for the dilation of the anus. It enters the external sphincter on either side at a point at the juncture of the lower and middle third of the anus.

At the upper limit of the anal canal at its juncture with the lower portion of the rectum are situated the *anal papillæ* and *crypts of Morgagni*. The papillæ appear as a more or less distinct line of small saw-tooth-like triangular projections which en-

www.libtool.com.cn

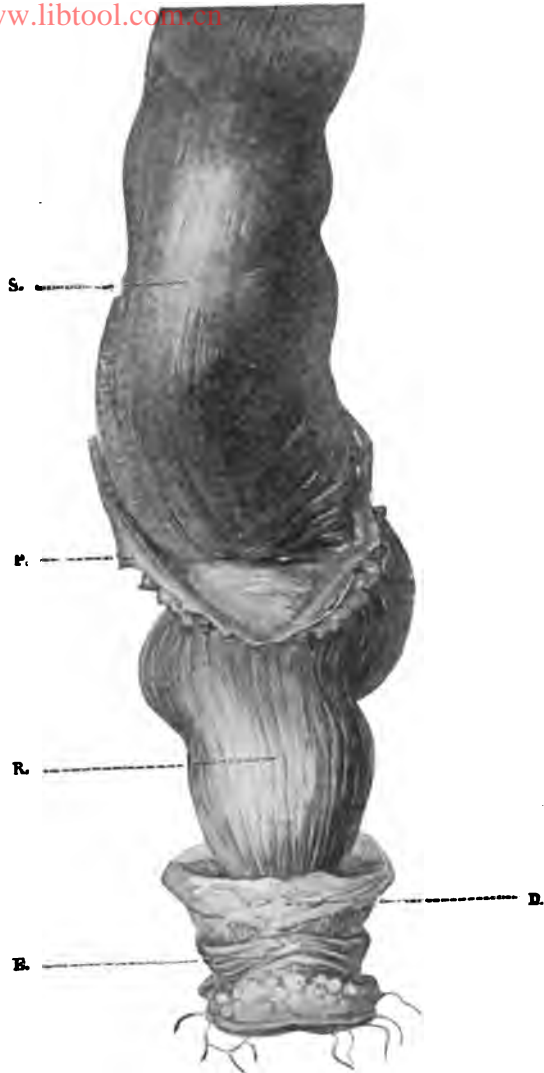


Fig. 2.—Rectum hardened in situ with formalin and then dissected out.—After Ball.

- S. Sacral curve of rectum
- P. Peritoneum cut at reflexion from bowel.
- R. Portion of rectum uncovered by peritoneum.
- D. Pelvic diaphragm.
- E. External sphincter.

circle the anal canal. This line is called the *linea dentata*, or *anorectal line*. Just behind these papillæ are found the openings of the crypts of Morgagni. The anal papillæ and crypts of Morgagni are of especial interest because they are often the seat of inflammatory conditions which present symptoms often out of all proportion to the size of the lesion causing them.

The blood and lymphatic supply will be taken up later.

## RECTUM

The rectum is a hollow, tubular organ varying in length from five to seven inches, and extending upward from the anorectal line to the rectosigmoidal juncture (Fig. 2). When empty, its anterior and posterior walls appose, and a cross-section would show a transverse slit. The rectum is usually understood to be that portion of the lower end of the large intestine which extends from the left sacroiliac symphysis to the anorectal line. Instead of it being a straight canal, as its name indicates, it is curved backward from the anorectal line, following the hollow of the sacrum, curving forward at the promontory, where it joins the lower portion of the sigmoid flexure. Some authors describe the rectum as that portion which extends from the anorectal line to the third sacral vertebra, which includes that portion which is not covered by peritoneum, the part above this being called the lower end of the pelvic colon, or sigmoid colon. Inasmuch as this latter division has not been accepted as yet, the author will consider the rectum as described in all of the standard textbooks on anatomy.

We will consider the rectum as divided in two portions: the upper or peritoneal portion; and the lower or that portion below the third sacral vertebra, the extraperitoneal. Thomas Charles Martin divides the rectal cavity into first, second, and third rectal chambers, each chamber corresponding to that portion below one of the rectal valves or folds of Houston.

The rectum is composed of four coats, being from within outward: the mucous, submucous, muscular, and serous. The muscular coat is composed of both circular and longitudinal fibers. At the lower portion of the rectum and extending down to the *white line of Hilton* in the anal canal, the circular muscular fibers

are more numerous and thrown together into what is known as the *internal sphincter muscle*. The mucous membrane is gathered together in folds which converge at the anorectal line, ending at the crypts of Morgagni. These folds are known as the *columns of Morgagni*. With the patient in the knee-shoulder position and the rectum inflated, the circumference of the organ when dilated will vary from five to ten inches. With the rectum inflated certain definite crescentic folds will be seen standing out from the rectal wall, encircling it for from one third to two thirds of its circumference. They appear at definite points and are usually three in number. One extremity appears attached lower to the rectal wall than the other, and they are arranged in such a manner that on procto-

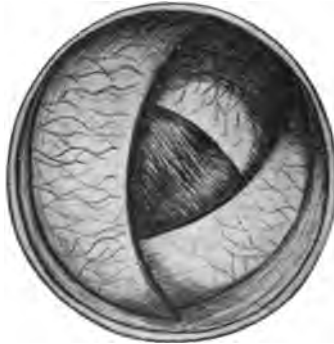

Fig. 3.—Proctoscopic view of the rectal valves—semidiagrammatic.

scopic view they give the effect of three projecting ledges arranged in the form of a spiral; the second being attached an inch to an inch and a half above the middle of the first; and the third at a point about the same distance above the middle of the second (Fig. 3). The first *rectal valve*, or *fold of Houston*, as it is called, is situated more often on the left lateral wall of the rectum opposite the location of the prostate gland, while the third is at or below the rectosigmoidal juncture. These valves are not simple folds of mucous membrane, but contain muscular fibers and blood-vessels and present all the characteristics of a typical anatomical valve. They are of considerable interest and importance because of the fact that, when they are infiltrated, thickened, or enlarged, they offer more or less



obstruction to the passage of the fecal current and ulcerations concealed on their upper surfaces are often overlooked, whose discovery would clear up the etiology of many cases of so-called diarrhea.

### LEVATOR ANI MUSCLE

Except the external sphincter muscle this is the most important muscle with which we have to deal (Fig. 4). With the external sphincter, this muscle practically controls the act of defecation. During defecation the levator ani and external sphincter muscles are relaxed, and the feces are extruded by the involuntary action of the muscular coats of the bowel, assisted by the voluntary compression and contraction of the abdominal muscles. The internal sphincter, in all probability, does not act as a sphincter at all, but co-operates in the peristaltic movement of the internal muscular coat of the intestine. When the fecal mass is extruded, the anterior portion of the upper portion of the anal canal is fixed by the rectourethralis muscle, which is a definite muscular band by which the anterior surface of the bowel at the juncture of the rectum and the anus is connected with the urethra. The puborectalis portion of the levator ani then compresses the sides and draws the posterior portion of the opening toward the pubis.

The external sphincter then completes the evacuation and closes the anal canal.

The levator ani, as described by Thompson and Ball, is composed of three main portions, the iliococcygeus, pubococcygeus, and puborectalis.

**Iliococcygeus.**—Although definitely attached to the ilium in many lower animals, in man this takes origin from the spine of the ischium and from a portion of the obturator fascia, roughly indicated by a white line which extends in a curve from the spine of the ischium to the back of the pubis. Although in older text-books this white line is described as a tendinous origin of the levator ani, recent observations tend to show that but few, if any, of the muscular fibers are actually attached to it, and that it is merely a thickening of the pelvic fascia. From this origin the iliococcygeus extends in a fan shape to be inserted into the side of the sacrum and coccyx; it is thin and in part membranous, and must be regarded as a degenerated muscle whose primary function in connection with

the tail is lost, but in virtue of whose position contributes to the formation of the pelvic floor. It has no direct relation to the rectum.

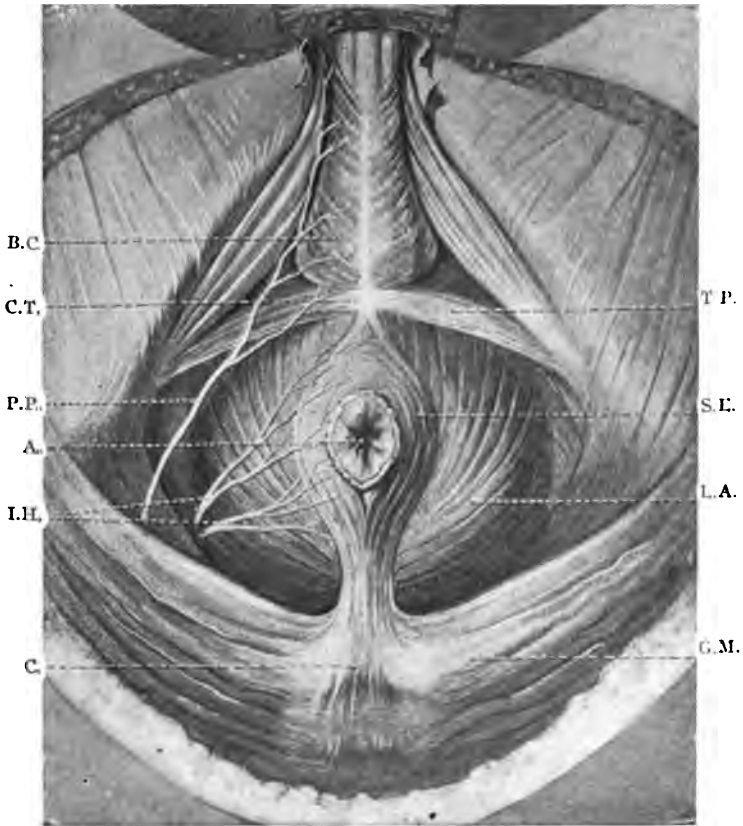


Fig. 4.—Muscles and nerves of the male pelvic outlet—After Ball.

- T. P. Transversus perinei muscle.
- S. E. External sphincter muscle.
- L. A. Levator ani muscle.
- G. M. Gluteus maximus muscle.
- C. Coccyx.
- I. H. Inferior hemorrhoidal nerve.
- A. Anus.
- P. P. Posterior superficial perineal nerve.
- C. T. Central tendinous point of perineum.
- B. C. Bulbocavernosus muscle.

**Pubococcygeus.**—This arises from the back of the pubis, and also from the obturator fascia, where usually its fibers blend with those of the iliococcygeus; from the origin the fibers pass almost hori-

zontally back, overlapping the iliococcygeus, closely related to the rectum (and vagina), to be attached to the coccyx and anococcygeal ligament. A few of the anterior fibers descend in front of the rectum to the perineal body, while lateral fibers are continued down into the aponeurotic sheath which surrounds the anal canal, in which the longitudinal fibers of the external coat of the rectum terminate.

**Puborectalis, or Sphincter Recti.**—This is the name given by Holl to an important band of fibers of the pubococcygeus, which, instead of being inserted into the coccyx and its ligamentous connections, is continuous with the fibers of the same muscle on the other side, forming a strong muscular cord around the lateral and posterior aspects of the upper opening of the anal canal. The fibers of the puborectalis muscle arise from the back of the pubis on either side, under cover of the pubococcygeus, and pass between the layers of this muscle, with more or less inter-change of fibers, to the back of the rectum, where they are continuous with the fibers of the same muscle on the other side. It is the most muscular portion of the levator ani, and when removed from a formalin-hardened body leaves a deep groove posteriorly where the rectum turns abruptly into the anal canal. According to Thompson, although traces of this muscle are found in some lower animals, it is only in the anthropoids that we find a muscular sling strongly developed for the first time, which in man has become evolved into such an important structure.

### LIGAMENTS

The chief ligaments that assist in supporting the rectum are the *anococcygeal* and *lateral* ligaments. The anococcygeal is a cord-like ligament which extends from the tip of the coccyx to a point near the juncture of the anus and rectum on its posterior surface. Attached to it are some of the more superficial fibers of the external sphincter. Upon either side of the rectum, just beneath the lateral reflections of the peritoneum, are connective-tissue attachments known as the lateral ligaments of the rectum. It is important to remember that they contain the middle hemorrhoidal vessels.

### RELATIONS OF THE RECTUM

The upper half of the rectum is almost entirely surrounded by *peritoneum*. In front the peritoneum dips down between the rectum and bladder, forming what is known in the male as the *rectovesical pouch*; in the female the uterus and vagina take the place of the bladder, and the pouch is known here as *Douglas' pouch*. The distance between the anus and the deepest point of dipping of this pouch is of great importance in the surgery of this region, and the distance varies, according to the measurements of different authors. The average distance is given as four inches. Cripps, after careful measurements of a large number of cadavers, gives the distance as  $2\frac{1}{2}$  inches when the bladder and rectum are emptied, and  $3\frac{1}{2}$  inches when both are distended. From this lowest point on the anterior surface of the rectum, the peritoneum gradually invests more and more of the rectum until its upper portion at the posterior wall of the rectum is about  $1\frac{1}{2}$  inches higher than the anterior. Where the two folds of peritoneum come together behind the rectum, they form a complete mesentery which is continuous with that of the sigmoid.

Other relations of the rectum are in front with the *bladder*, *seminal vesicles*, *vas deferens*, *urethra*, and *prostate* in the male; and the *vagina*, *uterus*, and *adnexa* in the female. Posteriorly it lies against the hollow of the *sacrum* and the *coccyx*. Laterally its upper portion is oftentimes in close contact with coils of the *small intestine* when they descend into the pelvis. On either side of the lower half of the rectum are located the *ischiorectal fossæ*.

### ISCHIORECTAL FOSSA

The ischiorectal space, or fossa, is a triangular space filled with loosely organized connective tissue and fat, situated on either side of the rectum between it and the tuberosity of the ischium. The apex of the cavity is directed upward and the base toward the perineum.

Gant describes these fossæ as follows:

“Their depth varies from one and a half inches in front to two inches behind, and at their lowermost and broadest part they are a little more than an inch in width. Internally these spaces are in relation to the external and internal sphincters, coccygeus,

and levator ani muscles; externally with the tuber ischii and obturator fascia; anteriorly with superficial and perineal fasciæ; and posteriorly with the border of the gluteus maximus muscles, the investing fascia of which is continuous with the great sacro-sciatic ligament. Within a sheath formed by the obturator fascia are to be found the internal pudic artery, veins, and nerves. The inferior hemorrhoidal vessels and nerves pass through the central portion of the ischiorectal fossæ on their way to the anal canal to which they are distributed, while in the anterior portion of these spaces are the superficial perineal vessels and nerves. The fat and connective tissue filling these spaces act as elastic supports for the rectum and are largely responsible for the lateral walls of the rectum remaining in contact. These fossæ are of surgical importance because of the frequency with which abscesses and fistulæ are found in this locality.”

### SIGMOID COLON

The sigmoid colon is that portion of the large intestine extending from its juncture with the rectum at the left sacroiliac symphysis to a point opposite the crest of the ileum where it becomes continuous with the descending colon. It derives its name of sigmoid colon or flexure from its double curve. It is entirely a peritoneal organ and is attached by a mesentery which is known as the *mesosigmoid*. Its average length is from 18 to 20 inches. When empty, the greater portion of the sigmoid colon lies in the left iliac fossa, and a portion of it may dip down into the pelvis. When filled, it usually extends over and occupies the right iliac fossa as well as the left. It is composed of four coats corresponding to those of the rectum, and in addition has on its outer surface directly opposite to its mesenteric attachment a longitudinal muscular band. Its narrowest portion is at its juncture with the rectum. On account of the length of its mesocolon, the sigmoid is of importance because of its tendency in some cases to prolapse or become invaginated into the rectum.

### BLOOD SUPPLY (Plate II)

The arteries of the rectum are the *superior*, *middle*, and *inferior hemorrhoidal*, and occasionally a branch from the *middle sacral* and

the *vesical*. The largest and most important vessel is the *superior hemorrhoidal*, which is a direct continuation of the *inferior mesenteric*. This vessel, which is situated at the posterior portion of the rectum, slightly to the left of the median line, passes down from the mesentery of the sigmoid colon to the upper portion of the rectum at a point about 4 to 4½ inches from the anus. It here divides into two main branches, the right and left, which almost immediately subdivide into three or four smaller branches, which run down the rectum almost to the anus, connected by a number of anastomotic branches, some of which pass in through the muscular coat of the bowel to the submucous coat where they end in a number of terminal branches, one being usually found in each of the columns of Morgagni. The *middle hemorrhoidal artery* arises from the *internal iliac* and enters the rectum on either side through the lateral ligament, where it breaks up into a number of branches, which supply the outer coats of the bowel but not the mucous membrane. The *inferior* or *external hemorrhoidal* arises from the *internal pudic*, and passing through the ischioanal fossa, is distributed to the muscles of the anal canal. This artery supplies the cutaneous portion of the anus, the skin surrounding the margin of the anus, but not the mucous membrane.

**Venous Supply.**—The veins of the rectum follow the arteries. The *superior hemorrhoidal* vein returns the blood from the rectum into the *inferior mesenteric* vein and directly to the *portal circulation*. Like the rest of the portal system, the superior hemorrhoidal vein is not supplied with valves. The *middle* and *inferior hemorrhoidal* veins return the blood from the anus and circumanal region by way of the *internal iliac* into the general venous circulation. The *hemorrhoidal plexus* is composed of a large number of anastomosing veins situated in the submucous and subcutaneous tissues of the anal canal, and is emptied largely by the superior hemorrhoidal veins.

## LYMPHATICS

The lymphatic vessels from the mucous membrane of the rectum proper communicate with a number of small glands known as the *postrectal* glands, lying between the rectum and the sacrum, from which lymphatic vessels pass up into the *mesentery* of the *sigmoid*. The lymphatics from the skin of the anus and circumanal region com-

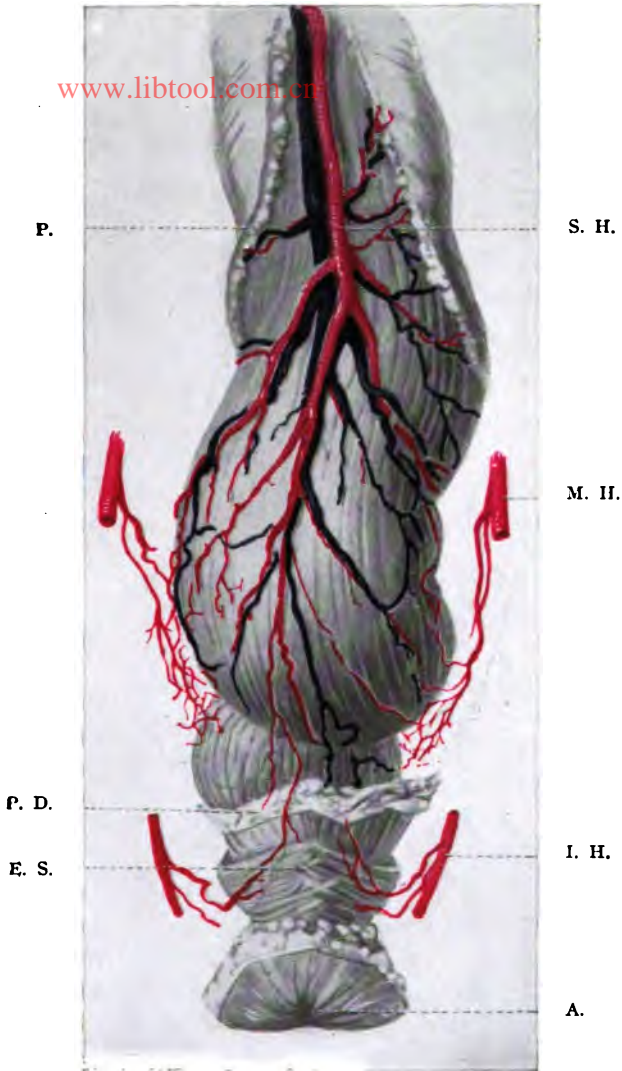


PLATE II.

Blood-vessels of the rectum.—After Ball.

- S. H. Superior hemorrhoidal artery.
- M. H. Middle hemorrhoidal artery.
- I. H. Inferior hemorrhoidal artery.
- A. Anus.
- E. S. External sphincter muscle.
- P. D. Pelvic diaphragm.
- P. Cut edge of peritoneum.

[www.libtool.com.cn](http://www.libtool.com.cn)



municate by the inner surface of the thighs with the *inguinal* glands. An important point to remember in this connection is that early involvement of the *inguinal* glands would indicate disease, either *malignant* or *infectious*, situated in the anal region, while *malignant* or *infectious* diseases of the rectum proper would extend to and infiltrate the *presacral* or *postrectal*, *lumbar*, and *mesenteric* glands.

### NERVE SUPPLY

The *rectum* is *not* supplied with *sensory nerves*, particularly in its upper half. The *anus* and *anal canal* and *lower portion* of the *rectum*, on the contrary, are *liberally supplied*. This accounts for the comparative *absence of pain* when the *rectum* proper is diseased, and the *intense suffering* caused by lesions in the *anal canal*. The sensory nerves of the anus are derived from the *sacral plexus*. The external sphincter muscle receives its nerve supply by branches from the *sacral plexus*, especially the *third* and *fourth nerves*. The *lesser sphincterian nerve of Morestin*, which is one of great importance in the production of local anesthesia for the dilatation of the external sphincter, is described by Tuttle as: "A filament coming off from the fifth and sixth sacral nerves which passes down the hollow of the sacrum through the levator ani muscle and the rectococcygeus ligament, finally reaching the posterior superficial surface of the external sphincter muscle." The levator ani is also supplied by branches from the *sacral plexus*. While the anus and rectum both receive their nerve supply from the *sympathetic* and *cerebrospinal* systems, the principal nerve supply of the rectum proper is *sympathetic*, it receiving branches from the *mesenteric*, *sacral*, and *hypogastric plexuses*. From the *cerebrospinal* system it is supplied by some filaments from the *third*, *fourth*, and *fifth sacral nerves*.

## CHAPTER II

### SYMPTOMS WHICH SHOULD CALL ATTENTION TO THE RECTUM

It has been estimated that one patient out of every seven is suffering from some disease, the relief of which would be assisted, or entirely accomplished, by the treatment of pathological conditions discovered only upon rectal examination. Many patients consult a physician, whose localized pain, swelling, hemorrhage, discharge, tenderness, irritation, or other symptoms call attention at once to the anorectal region. Many other symptoms, however, of a more general character—such as disturbances of digestion, menstruation, and the functions of urinary organs, as well as headache, backache, sciatica, joint pains, anemia, and sometimes even asthma and acne vulgaris—are more remote evidences of diseases originating within the confines of the lower bowel.

**Pain.**—This is the most frequent symptom which causes a patient to seek a physician's aid. It may be located at the anal orifice, in the anal canal, or the lower two inches of the rectum. It may be sharp, coming on suddenly, paroxysmal, burning, throbbing, or of a dull aching character. The character of the pain and the time of its onset with relation to the bowel movement are important, as they, of themselves, are often clues to the diagnosis. Sharp, acute pain, of a cutting, burning, or stinging quality, coming on with the stool or following it, almost invariably points to some lesion in the anal canal. Sudden, darting pains, occurring in the intervals between stools, also point to the same region for their origin. Pain of a throbbing character indicates acute, or subacute, inflammatory conditions. These may be integumentary, perianal, or perirectal abscesses. In these latter conditions, a rise in temperature will be noted, and the blood examination will show a leucocytosis. Pain of a dull aching character, whether intermittent or constant, may be caused by hemorrhoids, prolapse, polypus, fistula, ulceration of the rectum, benign growths—such as rectal adenoids—or malignant disease.

Many diseased conditions of the rectal cavity may progress to an astonishing degree without causing any local pain on account of the lack of sensory innervation of this region. Pain, however, referred to other portions of the body—such as the sacrum, uterus, vagina, bladder, urethra, penis, scrotum, or down the sciatic nerves, or up into the inguinal region—is frequently caused by pathological conditions in the rectum, which cause no local pain whatever.

**Tenderness.**—Tenderness in the circumanal region usually points to abscess formation or fistula. Tenderness of the anus indicates inflammatory conditions or ulceration.

**Spasm.**—This is caused by anything which irritates the sphincter muscles. Anal fissure, ulcer, or abscess, as well as hypertrophied papillæ, or foreign bodies, are the usual causes of anal spasm.

**Bleeding.**—This is one of the most frequent symptoms accompanying diseases of the anus and rectum, and it is one of the symptoms above all others which should call for complete examination of the anus, rectum, and sigmoid. Bleeding is more common in adults than in children. It may be very profuse, or slight, as simply a drop or two. It usually occurs during defecation, but may occur during the intervals as well. The blood may be discharged either liquid or clotted. It may be pure, or mixed with mucus, pus, feces, or other débris. Fresh blood discharged from the anus is usually from a local hemorrhage, but may have descended from the sigmoid or colon. The darker in color the blood, the higher in the bowel its source. Rectal hemorrhage may be caused:

1. By local disease.
2. By traumatism.
3. Following operation.

The cause of the last is so evident that it will not be considered, and trauma will simply be mentioned. The local diseases of the rectum which may cause hemorrhage are:

1. Internal hemorrhoids.
2. Prolapse.
3. Fissure.
4. Ulceration.
5. Stricture.
6. Malignant disease.
7. Proctitis.

8. Fecal impaction.
9. Polyposis.
10. Villous growths.
11. Chaneroids and chancres.
12. Condylomata.

Other diseases causing local rectal hemorrhage are:

1. Dysentery, amebic or bacillary.
2. Intussusception.
3. Embolism of mesenteric artery.
4. Congestion of the portal vein.

The general systemic diseases, such as malaria, scurvy, tuberculosis, typhoid fever, and others, which may during their course give rise to bloody stools, are not considered in this work because the diseased condition is very evident long before the hemorrhage presents itself. It may be mentioned, however, that the passage of some mucus streaked with blood in typhoid fever is often a warning signal of impending hemorrhage, and perforation.

The type of hemorrhage characteristic of the various conditions will be taken up as each variety is discussed in its respective chapter. The author has seen so many cases of cancer of the rectum, which had gone on to almost complete occlusion of the rectum and involvement of other organs, whose lives might have been saved if proper and complete examination of the rectum had been made when hemorrhage first manifested itself, that he is constrained to lay great stress on the importance of this symptom. *Rectal hemorrhage, no matter how slight, should never be taken for granted as diagnostic of hemorrhoids or any other disease, but should call for a complete examination, the technic of which will be explained in the following chapter.*

**Itching.**—Itching of the anus, or of the perineum, scrotum, or vulva, is a frequent accompanying symptom of many anal and rectal diseases. In fact it may occur with any of them. The degree and severity of the itching vary from a slight feeling of uneasiness and irritation, a mild pricking sensation following stools, to the most intense, persistent, aggravating condition characteristic of the more severe types of pruritus ani. Many constitutional diseases, such as diabetes and uric acidosis, predispose the patient to itching of any part of the body. When such a

patient has a diseased condition of any part of the anorectal region, however slight, he usually develops pruritus ani in addition to his other symptoms. In the author's experience, almost every case showing itching as the predominating symptom has been demonstrated to have had its origin in some local diseased condition of the anorectal region.

**Protrusions.**—While the most common protrusion of which the patient complains is some variety of hemorrhoids, it should be borne in mind that there are several other conditions made manifest by protrusion at the anal orifice, among which may be mentioned: prolapsus, polypi, hypertrophied papillæ, and cancer. In questioning a patient regarding a protrusion, one should find out whether it appears with the stools or not; whether straining efforts are necessary to produce it, or whether it appears spontaneously; whether it can be replaced, and if so, whether easily or not. One should inquire as to their number, whether they tend to remain outside of the sphincter, and whether or not their appearance or replacement is accompanied by pain.

**Elevations.**—Elevations found in the perianal region may be smooth and rounded, rough, hard, or soft and fluctuating, and are caused by external hemorrhoids, abscesses, lipomata, condylomata, or the external openings of fistulæ. A rounded elevation occurring at one side of the anus, accompanied by pain of a throbbing character with some rise of temperature, will be found due to a marginal or ischioanal abscess. A hard, rounded protuberance, occurring suddenly at the anal margin, accompanied by intense throbbing pain, will be found to be an acute thrombotic external hemorrhoid. A cluster of small rough elevations at the anal opening, usually posterior, is almost always condylomata.

A small papular elevation anywhere in the perianal region from which a purulent discharge exudes is almost invariably the external opening of a fistula. These are either single or multiple.

**Discharge.**—A history of discharge from the anus should always suggest anoscopic and proctoscopic examination. Hemorrhage has already been described above. While *mucus* may be caused by any irritation, acute or chronic, and accompanies practically all forms of rectal disease, it may originate in some inflammatory condition of the colon. The sigmoid should therefore always be explored when a mucous discharge is observed. *Purulent*

discharge may come from colitis, but more often points to abscess, internal sinus or "blind fistula," rectal ulceration, or malignant disease. The *odor* which accompanies the discharge caused by the last-mentioned condition is almost diagnostic in itself. Many patients who complain of pruritus, or local irritation of the anal region, will also complain of the *moisture* of the parts. It is well to bear in mind the possibility of disease of the Morgagnian crypts as the origin of this symptom.

**Constipation.**—No case of constipation, particularly of the chronic variety, should ever be treated until a complete examination has been made. So many cases of so-called constipation, which is purely a functional condition, are in reality due to mechanical causes. Coloptosis, floating kidney, prolapse, stricture, hypertrophied rectal valves, enlarged prostate, uterine displacements, adhesions, rectocele, perineal lacerations, fecal impaction, and many other diseased conditions often act in a purely mechanical way, causing obstipation, which can only be discovered after proper examination.

**Diarrhea.**—Chronic diarrhea *per se*, or alternating with constipation, so frequently occurs as a symptom of carcinoma and ulceration, that these diseases should be excluded by examination before treatment is commenced. Persistent diarrhea, unaccompanied by colic and pain, occurring in an apparently healthy individual, is very suggestive of beginning malignant disease. An apparent diarrhea may be the involuntary passage of normal stools, due to a weakened condition of the sphincters caused by previous injury, or beginning *tubes dorsalis*, or other spinal disease. This latter condition is called sphincteric ataxia.

**Altered Stools.**—Deviations from the normal appearance of the stools are often very suggestive, the large, hard stool of prolonged fecal retention giving a vastly different meaning than the narrow tape-like or pipe-stem stool of stricture. The color, consistency, and amount of the stool, as well as the appearance of blood, pus, or mucus with the movement, as has been noted above, are all of importance.

**Sacral Backache.**—This is often the only subjective symptom of beginning malignant disease. It often accompanies internal hemorrhoids, prolapse, impaction, and various benign growths. It is a symptom which should always call for rectal examination.

Many obstructive conditions of the sigmoid, as well as sigmoiditis and fecal impaction, will often cause a sense of weight or constriction in the pelvis. When this occurs in females, and diseases of the uterus or adnexa are excluded by gynecological examination, the sigmoidoscope should be used.

**Shooting Pains Down the Limbs.**—These, particularly on the left side, may accompany all forms of rectal disease. Sciatica has been so perfectly simulated by rectal ulcer that diagnosticians have been repeatedly led astray. This is often the predominating symptom in lateral ulcer of the rectum. Ischiorectal abscess, particularly of the left fossa, frequently causes pains shooting down the limbs.

**Crampy, Painful, and Scanty Menstruation.**—This, occurring in women who have perfectly normal genital organs, will be found upon rectal examination to be due in many cases to ulceration of the anterior rectal wall, fissure, or hemorrhoids.

**Urinary Disturbances.**—Frequent and painful urination, pressure symptoms in the bladder, pain and burning at the vesical neck, enuresis: all may be due to a number of anal and rectal diseased conditions. Fissure and ulcer are the most frequent causes of bladder irritability.

**General Disturbances.**—Loss of appetite, impaired digestion, nausea, headache, sallow complexion, and fever are frequently some of the symptoms of a focal infection or an autointoxication caused by some interference with the functions of the lower bowel, whose cause will be found upon rectal examination.

**Anemia.**—Persons suffering from anemia should always be questioned as to the existence of rectal hemorrhage, as not infrequently the loss of blood from internal hemorrhoids or ulceration is so extensive as to account for the anemic condition.

**Restlessness in Children.**—When children are restless at night and are continually picking at the nose or scratching the anus or genitals, an examination of the rectum will often disclose the presence of pinworms.

**Foreign Body.**—The history of the swallowing of a foreign body, such as a pin or fishbone, followed in a few days by anal pain or tenesmus, should call for a rectal examination, and the offending cause of the trouble will be found not infrequently protruding from the mouth of one of the Morgagnian crypts.

## CHAPTER III

### EXAMINATION OF THE PATIENT

#### **ROOMS AND FURNITURE**

The first and most important consideration is the location and arrangement of the examining-room. The ideal suite of offices should include, besides a reception room, a consultation room, a laboratory, a toilet, an examining or operating-room, and a resting or recovery room. The last two rooms should be situated at some distance from the reception room and should be separated from the other rooms by walls which are soundproof. It is not a pleasant prospect for a patient in the reception room, nervously awaiting his or her turn, to overhear through flimsy plaster or glass partitions the recital of another's ailments, or the apprehensive exclamations of a high-strung or hysterical patient on the operating table. Where a glass partition is all that separates the operating room from the reception room, those in waiting are often treated to a shadowgraphic representation of the performance going on within.

One who expects to do minor surgery and treatment work should equip himself properly for the same. A properly fitted out and furnished operating-room should be provided, which could serve as an examining-room as well. The room should be large enough so as not to be uncomfortably crowded with the furniture and paraphernalia necessary, and yet small enough to be compact. The floor should be of tile or granolithic material so as to be watertight and easily cleansed. The walls should be tiled, enameled, or treated with some material that will stand scrubbing. All corners should be rounded off, and as little woodwork as possible should enter into its construction.

The location of the suite will depend largely upon the location of the building itself, but where there is a choice, it will depend upon whether the strongest light is desired in the forenoon or afternoon. Heavy shades should be provided so that the operating or examining-room may be darkened when artificial light is



to be used. The walls and everything in the room, as far as possible, should be white. White gives the patient an impression of cleanliness at once; and the slightest soiling is so conspicuous that they must be kept clean.

The necessary furniture consists of a surgical table, or chair, which can be adjusted to various positions; an aseptic glass and




Fig. 5.—A simple form of instrument sterilizer for office use.



Fig. 6.—A small instrument and dressing sterilizer. This is a very simple and popular form of steam sterilizer. The dressing for an office operation may be sterilized in the trays above the boiling instruments.

metal instrument case; glass-top instrument table; revolving stool; sterilizer (Figs. 5, 6), with stand; foot tub; enameled bowls and dressing basins, pail, compressed-air tank, and plumbing, electric-light wiring, and other fixtures, according to the ideas of the individual.

If it is not possible to have a toilet room adjoining the operat-

ing-room, a commode should be added to the equipment. A retiring or ~~recovery room is~~ almost a necessity as well.

The author prefers an examining-table to a surgical chair. He believes that it is not more distasteful to the patient to get up on a table to be examined than it is to be seated in a chair




Fig. 7.—Operating-table. This is a light but strong all-metal operating-table, particularly adapted for office work. It may be thrown into any position that either a surgical chair or table can be.

and by the turn of a crank to be jerked or jarred, or flopped into position. Surgical chairs are cumbersome and always getting out of order, and are not to be compared with a nice, clean operating-table of enameled iron which can be adjusted to any posi-

tion required (Fig. 7). Hair-stuffed cushions covered with white rubber and ~~not exceeding one~~ inch in thickness are placed on top of the table. The cushions should be thick enough so as to counteract the hardness of the table, and yet not so thick that the patient's buttocks sink down into them.

Plenty of clean white sheets should be always on hand, and the examiner will find it more comfortable and cleanly to wear a white linen or duck coat, or a surgical gown. The author has found the electric headlight very useful where the interior of the rectum is to be examined, and believes it so far superior to



Fig. 8.—Electric magnifying headlight. This is a very simple, inexpensive, and very satisfactory electric headlight. It may be used either on the street current or vest-pocket battery. It is very light, compact, and can be so adjusted that the light is brought between the operator's eyes. There is a condensing lens which assists in focusing, thus greatly increasing its efficiency.

the head mirror and lamp that he no longer uses the latter (Fig. 8).

While it is extremely desirable to have such an equipment, as has been described above, a very satisfactory examination can be made on any sort of a table or bed with the aid of a good light. The technic which the author uses will be described, not because it will be found the best by all practitioners, but because he has found it the best and most satisfactory in his experience.

### EXAMINATION

The patient should first be asked into the consulting-room, and in order to put him at his ease, he should be allowed to tell his

story of his ailments in his own way. As he mentions symptoms or salient points which are pertinent, they should be noted down for use in questioning him later. When he has finished, he should be questioned in a more systematic manner, and his history noted on a special blank or card kept for the purpose. The various symptoms brought out in this way will often suggest a tentative diagnosis, but as has been stated in the preceding chapter, nothing should be taken for granted and a complete rectal examination in-

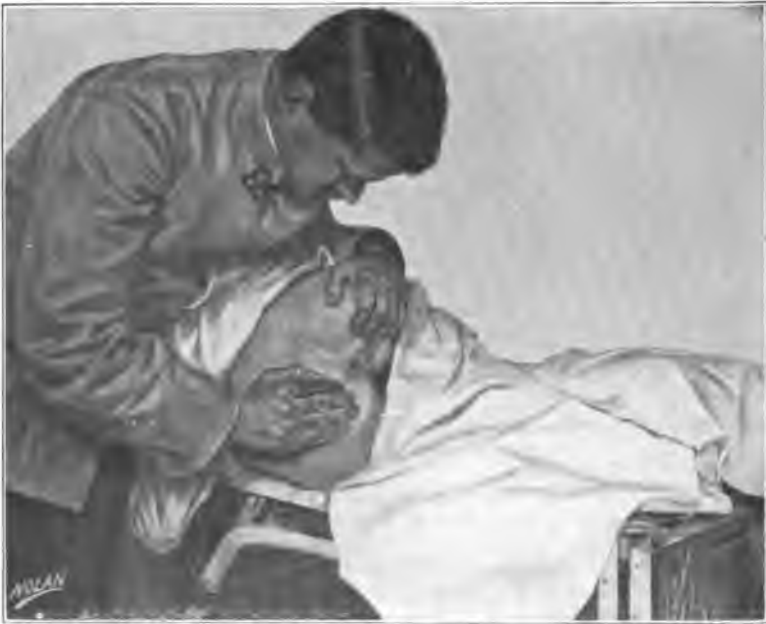

Fig. 9.—External inspection. This drawing well illustrates the posture of both examiner and patient, and shows the extent to which the anus may be dilated by traction of the skin of the buttocks.

sisted upon. The patient is then taken into the examining-room and prepared for the examination. All clothing, corsets, tight waistbands, or anything which constricts, or has a tendency to interfere with respiration, or to crowd the abdominal organs or intestines out of place, should be loosened or removed. The patient is then placed on the table in the left lateral or Sims position and covered with sheets in such a manner that there is never any unnecessary exposure (Fig. 9).

With the patient so placed as to get good daylight, or by the aid of the headlight, the anus, perineum, buttocks, and the genital organs are carefully examined. Discolorations, protrusions, elevations, swellings, abrasions, cracks, skin eruptions, crusts, scars, discharge, or any other abnormal appearance of the parts should be carefully noted.

**Digital.**—With the patient in the same position, digital examination is next in order. It is well to have in readiness a bowl of some antiseptic solution, preferably one which will not attack steel instruments. The author has found a 1:10,000 solution of mercuric iodid the most satisfactory. Its germicidal power is equal to that of the bichlorid in the strength of 1:2,000.

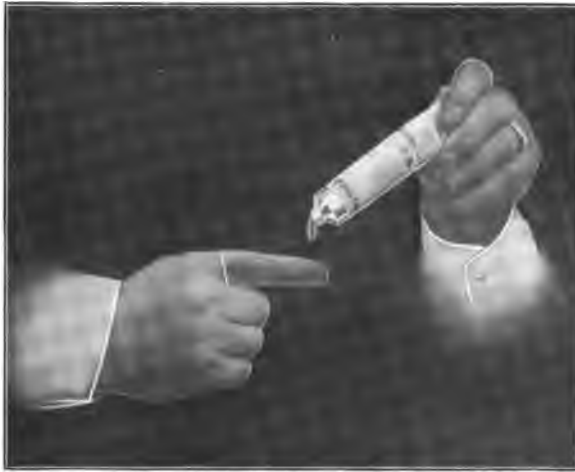

Fig. 10.—Method of applying lubricant from collapsible tube to examining finger protected with a rubber finger cot.

Rubber gloves or finger cots should always be used in digital examination. The examining finger protected by the finger cot should always be well lubricated before an examination is attempted (Fig. 10). There are a number of excellent commercial lubricants on the market, such as Hartz's "Lubra-Septol" and Van Horn's "K-Y," but sterile vaselin or oil will be found to answer the purpose almost as well. The lubricant used by the author and which has given him perfect satisfaction is prepared as follows:

℞ Hydrargyri oxyeyanidi .....	0.240
Glycerini .....	20.
Tragacantha .....	3.
Aquæ .....	100.
Dispense in two-ounce collapsible lead tubes.	

The posture of the patient for digital examination is very important. The old method of having a patient simply bend or lean over a chair or table, then inserting the index finger (Fig. 11), is not nearly so satisfactory, comfortable, or thorough to either examiner or patient as the *lateral* or *Sims* position (Fig. 12). The patient in the Sims position is relaxed and at ease,

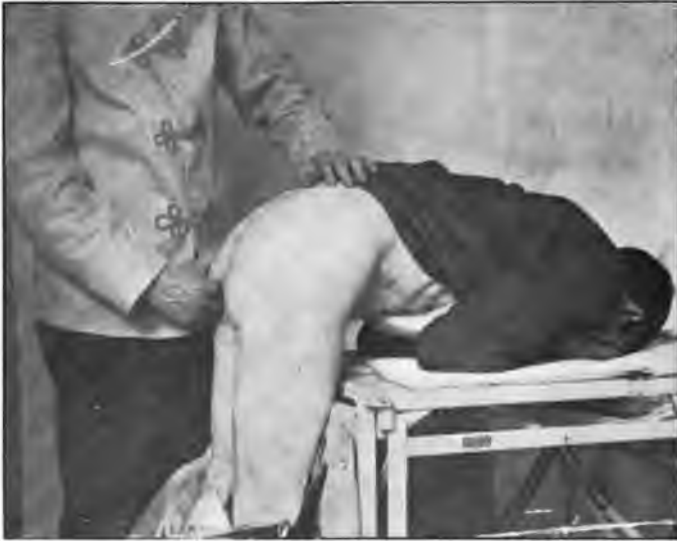

Fig. 11.—Incorrect method of digital examination. This method was deemed the only proper method of making a digital examination of the anus and rectum. Contrast this with the following illustration.

and the parts are presented in such a manner as to give the clearest view and produce the most satisfactory results.

The wearing of a glove or thin-rubber finger cot is done for several reasons. In the first place, it protects the wearer from infection. It also prevents the soiling of the finger with fecal material, pus, or discharge with their disagreeable odors. It does not interfere with the sense of touch, which can be educated to extreme delicacy even with the cot. From the patient's standpoint it is

much more desirable—the smooth rubber covering over the finger enabling it to enter much more easily than the unprotected finger, and there is no danger of irritating sensitive areas with the finger nail. If one wishes to make a digital examination, and a finger cot is not available, the nail of the examining finger should be closely trimmed, and the crevices under and around it filled by scratching the surface of a bar of soap. The rest of the finger nail should be covered with soapsuds, vaselin, or whatever lubricant is handy. After the examination, the lubricating material

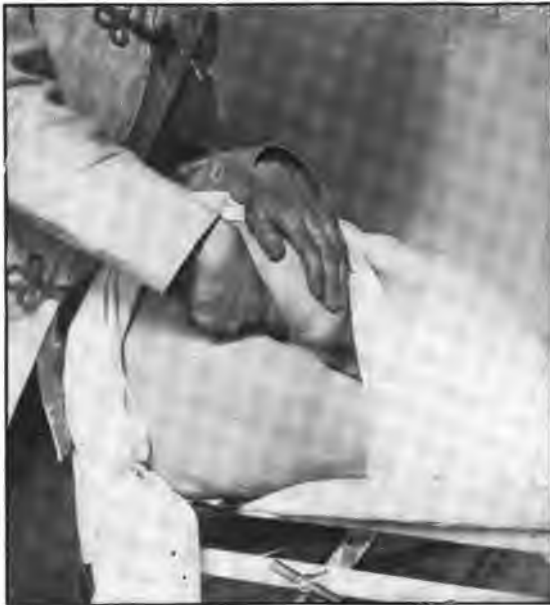

Fig. 12.—Correct method of digital examination. With the patient in the lateral or Sims position, the examiner standing behind the patient, digital exploration of the anus and rectum can be accomplished with much more thoroughness, satisfaction, and comfort to both.

should be wiped from the finger with a dry cloth or absorbent cotton before washing the hands.

The position of the patient and the examiner as well is shown in the accompanying illustration (Fig. 12). The protected and lubricated finger, which is usually the index finger of the right hand, is pressed against the anus with the flexor surface toward the posterior commissure, and the patient is asked to bear down.

The finger is first entered pointing anteriorly until the sphincters have been passed, and then passed backward and upward in the posterior direction. As the finger enters, it should be gently turned from side to side sweeping over all the surfaces of the anal canal and lower rectum. Any increase or decrease in the normal resistance of the sphincter muscles should be especially noted. Increased resistance is due to the presence of a stricture or some painful lesion. Diminished or absence of normal resistance is due to injury to the sphincters, congenital defect, or beginning

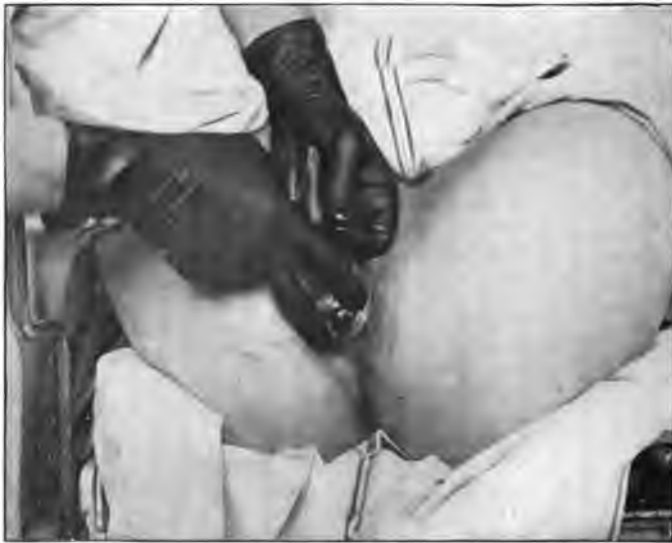

Fig. 13.—Vaginal eversion of the anus. This method is useful in examining the anterior wall of the anus, and lower rectum in female patients, particularly those who have borne children and who have lax perineums.

*tabes dorsalis* or other spinal disease. Sphincteric ataxia is often one of the earliest warning signals of *tabes dorsalis*. Any change from the normal, soft, velvety feeling of this region—such as elevations, depressions, or indurations—should be carefully noted. The location of the feces is also important, particularly where symptoms of interference with normal defecation are presented. It is therefore important not to give an enema before the first digital examination. Unless one wishes to determine conditions high up in the rectum, or to make a rectoabdominal examination, one should



not feel too high in searching for the source of painful rectal symptoms. ~~Most of these disease~~ conditions will be found within the first two inches from the anal outlet. Often, in inserting the finger, the various lesions are pushed up into the rectum, giving the impression that they are higher than they actually are. It is with the withdrawal of the finger, therefore, that more valuable information is often obtained than on its introduction.

Where the sphincters are so sensitive or tightly contracted as to prevent digital examination being accomplished without great

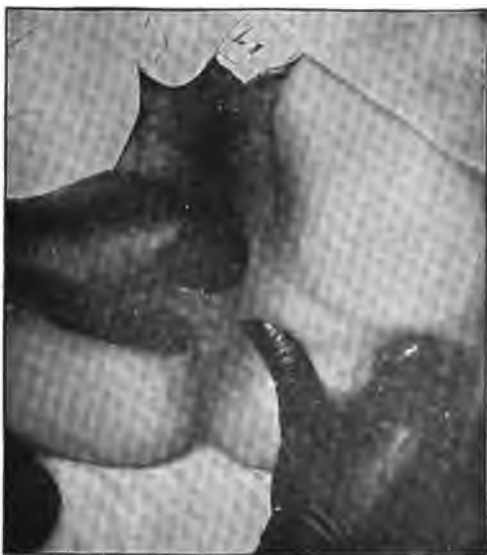

Fig. 14.—Another method of everting the anal tissues for inspection.—From Crossen: *Diagnosis and Treatment of Diseases of Women*.

pain to the patient, dilatation of the sphincters by means of local anesthesia should be employed. The technic of local anesthesia is fully described in Chapter XV, to which the reader is referred.

In women much valuable information can be gained oftentimes by *vaginorectal* examination, which is accomplished either by the index finger in the rectum and the thumb in the vagina; or by using the index finger of the left hand in the vagina while the right is in the rectum. Often in women where the perineum is lax, the anus may be *everted* by downward and outward pressure

of the index finger of the right hand in the vagina, while the anus is spread between the index finger and thumb of the left hand (Figs. 13, 14, 15).

The *lithotomy* position, while in most cases not nearly so satisfactory for complete ocular inspection of the external parts or the use of the anoscope—nor as comfortable for the patient—has its place in the examination of the patient suffering from ano-

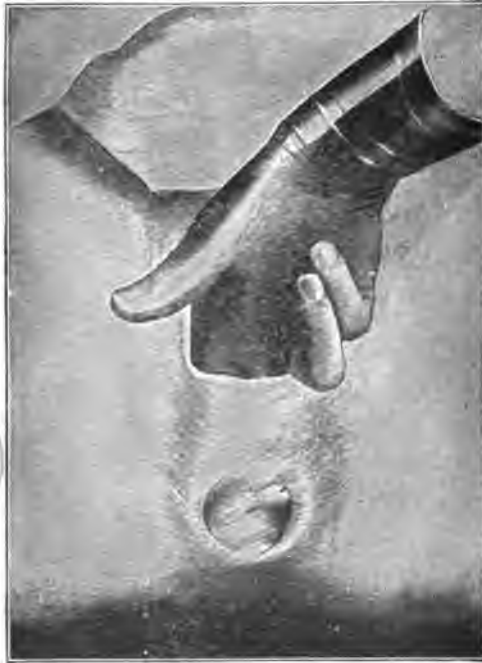

Fig. 15.—Indicating the amount of possible eversion of anal tissues where the pelvic floor is lax, as in multiparæ.—Dudley: Practice of Gynecology.

rectal diseases. If for some reason or other the patient is not comfortable in the lateral position, which will occasionally be the case in those who suffer from rheumatism or some other joint affection; or on account of an unusual amount of adipose tissue the patient's buttocks cannot be well separated in the lateral position, the lithotomy position will be found much more satisfactory. The patient is asked to lie flat upon the table after the clothing has been removed, and a sheet thrown over him. The knees are



flexed upon the thighs, the thighs upon the abdomen, and the patient's buttocks pulled well down to the edge of the table. The legs are kept in this position either by an assistant or by the use of a Kelly leg holder or Clover's crutch, or by the stirrups or leg holders which accompany the average surgical table. In this position the perineal space and the perianal region can be inspected and palpated, and in the case of a female patient, examination of the genital organs carried out at the same time. In this position also the condition of the prostate and seminal vesicles of the male can be made out, and oftentimes the extent and direction of a fistulous tract determined more satisfactorily than in the lateral position. The condition of the coccyx can be determined with the

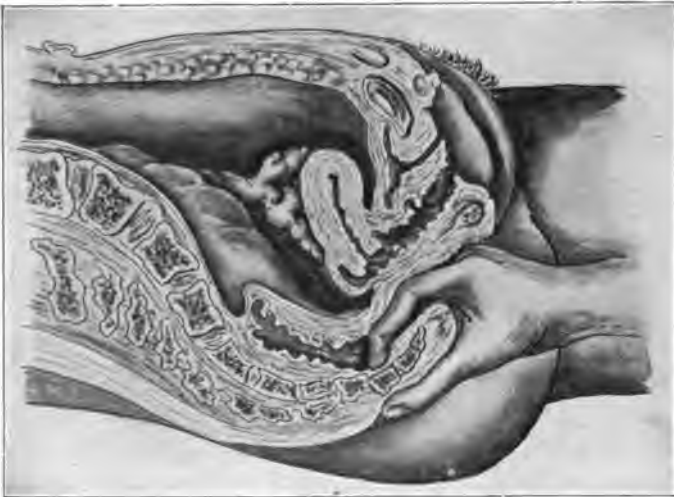

Fig. 16.—Method of examining the coccyx with one hand. This may also be done with one hand over the region of the coccyx, posterior to and above the anus, and the index finger of the other inside of the rectum.—Hirst: Diseases of Women.

patient in the lithotomy position by inserting one finger into the rectum with the other hand over the region of the coccyx, or by inserting the forefinger into the rectum with the thumb of the same hand over the location of the coccyx on the outside (Fig. 16).

With the patient in the *lithotomy* position, bimanual abdomino-vaginal, and abdominorectal examinations are accomplished (Figs. 17-20). It is a good, safe plan to include both of these methods in the routine examination of every patient, because very fre-

quently unsuspected or beginning diseased conditions in the pelvis and abdomen are discovered before they have given rise to subjective symptoms. In any case presenting the symptoms of sacral backache, weight in the pelvis, the passage of blood or pus with the stool, or diarrhea, abdominorectal palpation, with the right index finger inserted as high as possible in the rectum, and the left hand over the right and left iliac fossæ and above the pubes, is imperative.

The *squatting* position (Fig. 21), or the position assumed by the aboriginal races in defecation, is oftentimes of great value in

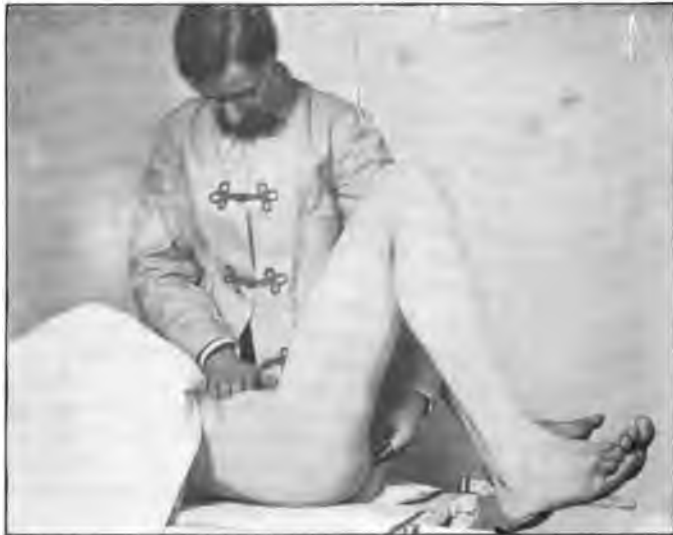

Fig. 17.—Posture and method of making rectoabdominal bimanual examination.

the diagnosis of those conditions made manifest by protrusions from the anal orifice. The patient is asked to remove his clothing and to squat as if he wished to defecate. It is best to place a shallow basin or receptacle underneath him lest, during his straining efforts, feces, pus, blood, or discharge may escape. The patient is then asked to bear down or strain; when in this position, prolapsing internal hemorrhoids, polypi, or prolapse of the rectum or anus will be brought into view in a very satisfactory manner.

**Internal Inspection.**—Before proceeding to internal inspection,

the rectum should be emptied by means of an enema of soapsuds and water. If one's office equipment does not include an irrigator, a two-quart fountain syringe will answer very nicely. Another very simple method is to use a three or four-ounce, soft-tipped, all-rubber bulb syringe, known as the ear-and-ulcer syringe (Fig.

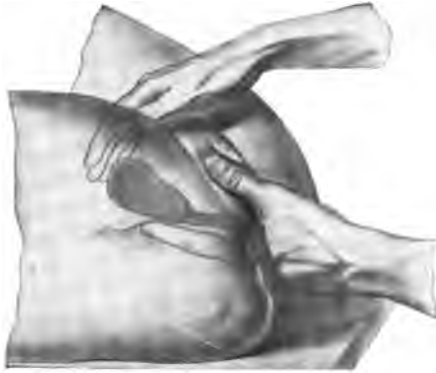

Fig. 18.—Method of rectoabdominal palpation. The position of both hands in relation to the uterus and vagina is well shown.—Montgomery: *Practical Gynecology*.

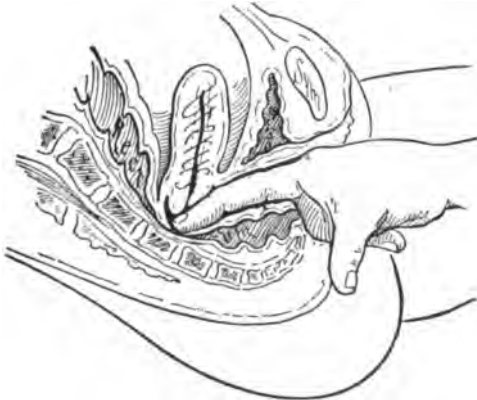


Fig. 19.—Palpation of rectum through posterior vaginal wall.—Ashton: *Practice of Gynecology*.

22). With the patient in the lateral or Sims' position a pint or more of solution can be gently injected, and the rectum cleansed in a very satisfactory manner—the patient being allowed to rise and go to the toilet to expel it.

Internal inspection of the anus, rectum, and sigmoid is best

accomplished with the patient in the *knee-shoulder* position. The patient, who has been lying in the Sims' position, is asked to kneel on the table and to maintain the kneeling position while the examiner brings the left shoulder down to the table flush with the knees. The patient should not be allowed to rest on the elbows as the trunk must present enough of an inclined plane to allow atmospheric dilatation of the rectum, when the examining

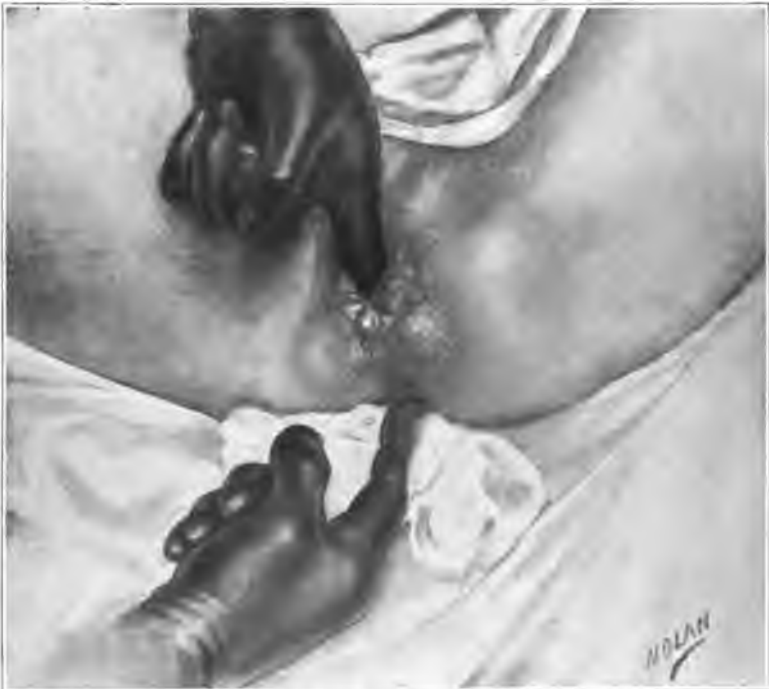

Fig. 20.—Ischio-rectal abscess. This illustration, besides showing the point of swelling and fluctuation of the abscess, illustrates the method of bimanual palpation in the examination and diagnosis of the condition. At the posterior commissure of the anus will be seen a small external hemorrhoid as well.

instruments are inserted, and allow the other abdominal organs to fall away from the rectum. The accompanying illustrations clearly show the difference between the correct and incorrect postures (Figs. 23, 24).

Oftentimes the internal opening of a fistula can be determined by the injection through its external opening of a solution of 25



Fig. 21.—Squatting position. This position shows the natural posture for defecation, and is useful in extruding prolapsing conditions.



Fig. 22.—Three-ounce, all-rubber bulb syringe. Useful in irrigating, and in giving enemata when an ordinary irrigator is not available.

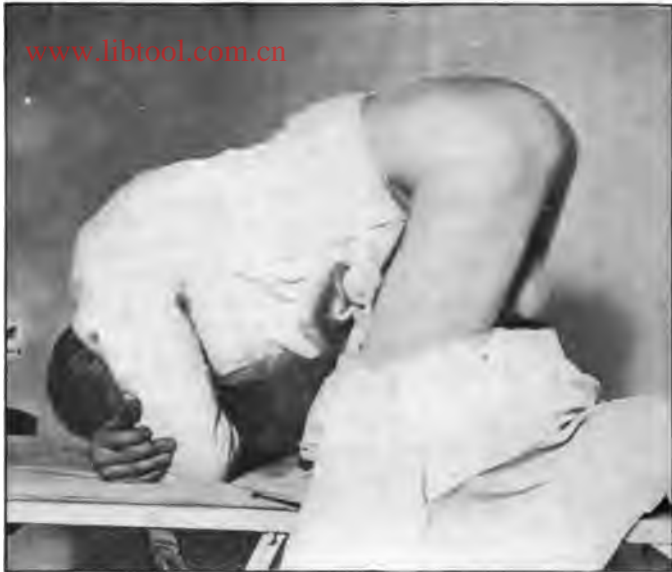

Fig. 23.—Knee-elbow position. This position is often mistakenly employed in proctoscopy, and should not be confused with the knee-shoulder position, as depicted in the following illustration.

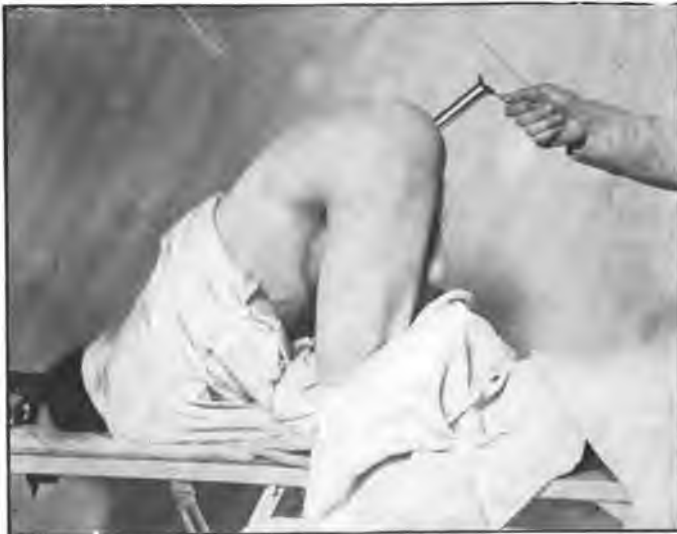

Fig. 24.—Knee-shoulder position. This is the correct posture for proctoscopic examination. By comparing this with the preceding one, it will be seen that in the knee-shoulder position much more of an inclined plane is produced. Note the direction in which the proctoscope is introduced.



per cent peroxid of hydrogen. Upon examining through the proctoscope, while injecting, the internal opening can be easily located by the appearance of the bubbling peroxid solution. Solutions of methylene blue or milk of magnesia or bismuth paste

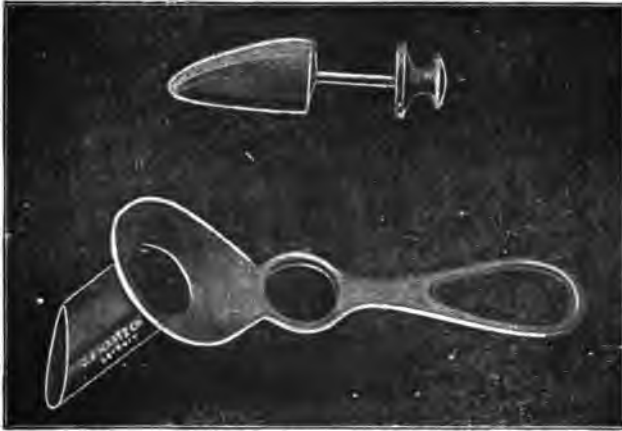


Fig. 25.—Author's anoscope with oblique opening and slanting obturator.



Fig. 26.—Author's adjustable fenestrated anoscope. This instrument is provided with a closed extremity; has a fenestrum  $1\frac{1}{8}$  inches long by  $\frac{1}{2}$  inch wide; and can be revolved so that the fenestrum can be placed at any angle in relation to the handle.

can also be used in like manner for a similar purpose. The injection of fistulous tracts with bismuth paste, as advocated by Emil Beck (Chap. IX), is of the greatest value in the production of stereoscopic radiographs. This is the refinement of diag-

nostic technic in the location of all of the ramifications of an anal fistula. [www.libtool.com.cn](http://www.libtool.com.cn)

For internal inspection of the anal canal, the lateral or Sims position is sufficient.

**ANOSCOPY.**—The instruments required for inspection of the anal canal, or anoscopy, are: a cylindrical anoscope, whose internal opening is oblique, and containing an obturator tapering to a



Fig. 27.—Soft, flexible, silver wire probe. (Made easily by fusing probe points on ordinary suture wire.)



Fig. 28.—Long alligator forceps. These are made in different sizes, ranging from 9 to 14 inches in length, and are very useful in proctoscopic and sigmoidoscopic examination.

blunt round extremity (Fig. 25); the tapering, adjustable fenestrated anoscope with closed extremity (Fig. 26); a fine flexible probe (Fig. 27), made of pure silver; and a pair of dressing forceps (Fig. 28). An ordinary Kelly anoscope (Fig. 29) is also oftentimes very useful.

Bearing in mind from the digital examination the location of the lesions in the anal canal, the fenestrated anoscope, well lubricated, with the opening turned so as to be opposite the lesion

when entered, is pressed against the anus and gently inserted while the patient is bearing down against it (Fig. 30). If an opening is detected, this may be explored with the soft-silver probe, which may be bent easily at any angle, care being taken to use no force and to handle it with extreme gentleness and delicacy. In some cases, the instrument with the oblique opening is used in preference, its opening giving nearly twice the field of the ordinary circular opening of the Kelly instrument. The Kelly anoscope, however, is useful in exposing conditions which prolapse—the patient being asked to strain and bear down while the instrument is being withdrawn.

By doing so, prolapsing hemorrhoids, prolapse of the anus or rectum, polypi, or papillæ are brought out into view. If the view




Fig. 29.—Kelly anoscope. Useful in prolapsing conditions.

is obscured, at any time, a bit of cotton should be taken up with the dressing forceps to cleanse the parts.

The *knee-shoulder position* is by far the most satisfactory in the author's experience for examination of the rectal cavity and most of the sigmoid. Not only does the atmospheric pressure balloon out the rectum to its fullest capacity, but this position also removes the pressure of other abdominal organs from the rectum by allowing them to fall away.

**PROCTOSCOPY.**—The only instruments required for proctoscopy or ocular inspection of the rectal cavity are: a cylindrical proctoscope, from four to six inches in length and from three quarters to seven eighths of an inch in diameter, and a pair of long alligator forceps. (Fig. 28.) In an emergency, a very fair inspection of the

rectal cavity may be had without any instruments whatever. The technic of *proctoscopy without instruments* is as follows:

With the patient in the knee-shoulder position, the index finger of the right hand, protected by a finger cot, and well lubricated, is gently inserted, and the sphincter massaged; then the index finger of the left hand, similarly protected and lubricated, is introduced back to back with the finger in the rectum. The in-



Fig. 30.—Posture and method of using the author's fenestrated anoscope, for examining the anal canal.

roduction of the second finger should be done slowly and gently and with a massage-like motion. When it has been introduced to an equal depth with its fellow, that is, up to the second joint of the finger, the fingers should be gently separated. The atmospheric air then rushes in with an audible hiss, and the rectum balloons out so that it can be examined with the aid of the electric headlight or reflected light from the head mirror.

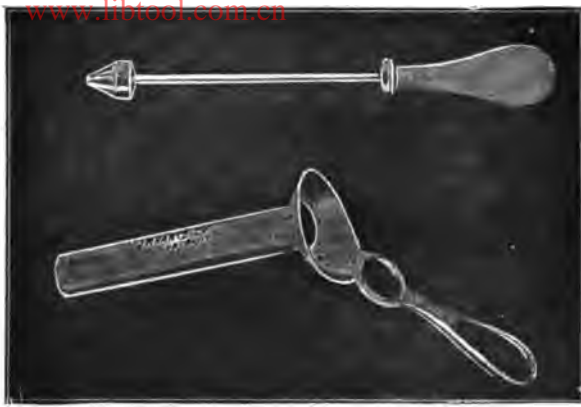


Fig. 31.—Author's modification of the Martin proctoscope, provided with a metal obturator with conical extremity, which contains an air vent running through its entire length. It is  $\frac{3}{8}$  inch in diameter and 6 inches long.



Fig. 32.—Tuttle pneumatic proctoscope.

With this method, however, one cannot see behind the rectal valves or folds of Houston, and it is only of value where a suitable examining instrument is not at hand and the lowermost portion only of the rectal cavity is to be explored.

The *technic of proctoscopy* is as follows:

With a proctoscope whose outside diameter does not exceed the diameter of the operator's index finger, all parts of the rectal cavity can be successfully explored, and its introduction causes no more pain or discomfort than digital examination. The in-

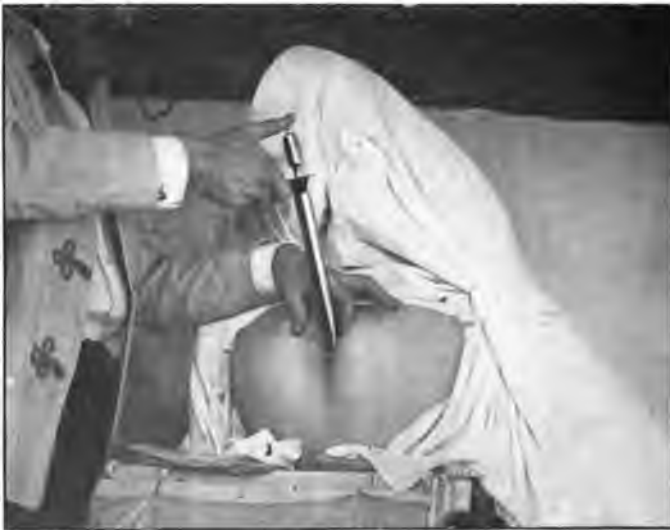

Fig. 33.— Exaggerated lithotomy position. Illustrating posture of the patient and technic of introduction of the sigmoidoscope.

strument used by the author is a modification of that devised by T. C. Martin (Fig. 31). It is five and one-half inches long from the edge of the flange to the tip of the obturator. Its outside diameter is three quarters of an inch. It is provided with an obturator made of metal, with a conical extremity which fits it very snugly. The obturator is channeled so as to allow the ingress of air during its introduction. With the patient in the knee-shoulder position, the well-lubricated proctoscope is pressed against the anus, pointing in the direction of the patient's umbilicus, and the patient asked to bear down, as in the act of

defecation. While he is doing so, the proctoscope is inserted gently, first downward and forward, until the anal canal has been passed; when it is tilted upward and backward and the rectal cavity is entered without difficulty. By asking the patient to bear down during the introduction of the instrument, the patient forces his anus down over the proctoscope, as it were, and introduction is




Fig. 34.—Kelly sigmoidoscope. This is made in sizes varying from 8 to 14 inches in length.

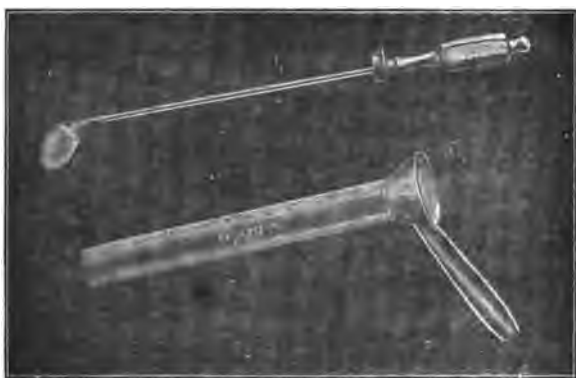


Fig. 35.—Sigmoidoscope provided with the author's tilting obturator. The tilting obturator is of value in the insertion of the sigmoidoscope, allowing it to round the sacral curve with greater facility.

accomplished with much ease. Holding the proctoscope in the left hand, the obturator is withdrawn with the right. Inspection of the entire rectal cavity can then be accomplished with as much ease and completeness as the examination of the nose or throat. The proctoscope should always be entered to its fullest length before the obturator is withdrawn.

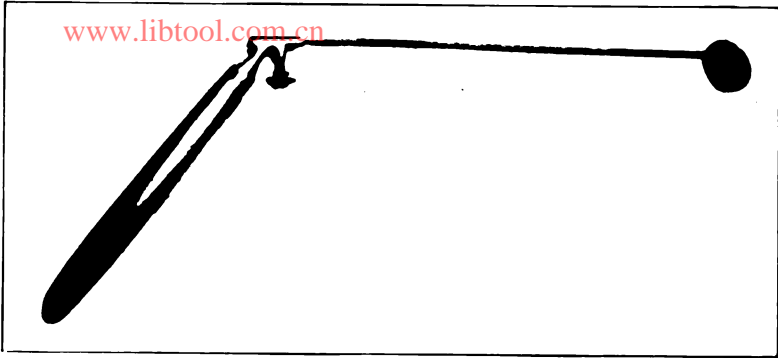


Fig. 36.—Adjustable proctoscopic mirror.

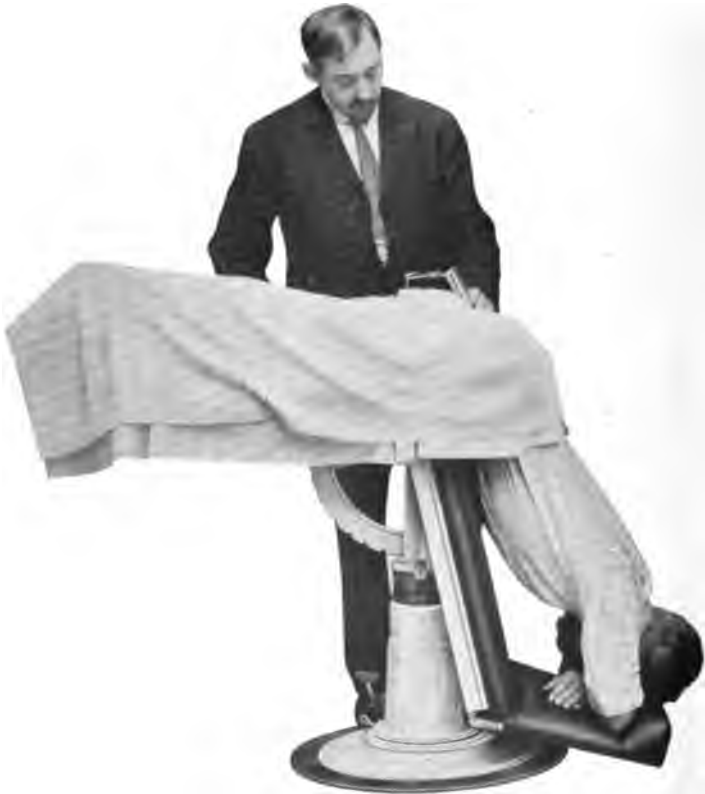

Fig. 37.—Inverted or Hanes position.



After examining the uppermost part of the rectum, and noting the appearance and condition of the rectosigmoidal juncture, it is slowly withdrawn, the examiner in the meanwhile noting the condition of the lining membrane of the rectum, the rectal valves, and the anal canal until the instrument is completely withdrawn. If, upon the withdrawal of the obturator, the opening of the proc-



Fig. 38.—Improvised arrangement with ordinary operating table and pillow on floor for obtaining inverted position.

toscope seems closed by a wall of rectal mucous membrane, by manipulating the instrument so that its inner extremity is moved to one side or the other, the obstruction will often be found to be one of the rectal valves, or folds of Houston; and on pushing this to one side with the instrument, a new field is exposed to view. With the proctoscope in position, the size, density, and thickness of the rectal valves can be noted by means of a probe or applicator

bent at a right angle; ulcerations of the rectal wall, their extent and severity, noted; then on condition of the circulation of the rectum; the presence of polypi—in fact, any deviation from the normal, smooth, pearly pink appearance of the mucous membrane of the normal rectum easily made out by this method of examination. The condition of the upper surfaces of the rectal valves and the inner aspect of the anal canal can be accurately determined by

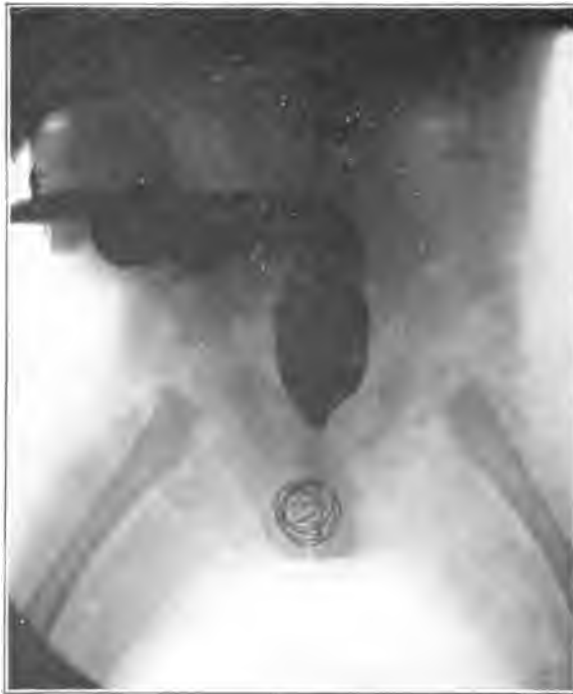

Fig. 39.—Imperforate anus in one-year-old child. Injected with bismuth through inguinal anus, which was made when child was forty-eight hours old. Coil of wire indicates normal anal site.

the use of a small laryngoscopic mirror mounted on a long flexible handle (Fig. 36). While the proctoscope is in position, local applications to diseased areas, sprays, insufflations, and other therapeutic measures, when indicated, may be carried on under the direct guidance of the eye. The alligator forceps are useful for swabbing out the rectum and obtaining tissue for microscopical examination.

SIGMOIDOSCOPY.—The *exaggerated lithotomy position* (Fig. 33), also sometimes known as the *genitourinary position*, is very useful when it is necessary to examine the sigmoid flexure. This position is secured by putting the patient in the lithotomy position, as above described, and then slowly lowering the head of the table so as to leave the buttocks somewhat higher than the patient's shoulders. This puts the patient in a sort of semi-Trendelenburg position with the thighs and knees flexed. In this position it will

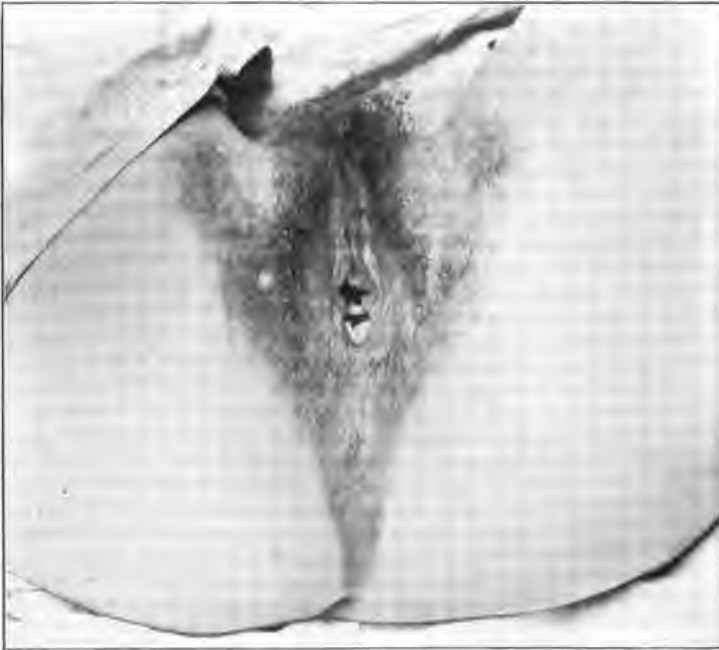


Fig. 40.—Atresia ani vaginalis (complete). Photograph of author's case. This illustrates a case of complete absence of the anus with the rectum emptying itself through the vagina. The patient was 25 years old and did not know until shortly before consulting the author that she was different from other people. She had partial control of her fecal movements by an overdevelopment of her sphincter vaginae. At the normal location of the anus was found a rudimentary external sphincter. The case was operated on by the author, the vaginal opening closed, and the rectum brought down to the normal anal site, with the result that the patient has an apparently normal anus with good control. The above photograph well shows the septum separating the rectal opening into the vagina from the upper vaginal canal.

be found comparatively easy to introduce the sigmoidoscope and secure atmospheric dilatation of the sigmoid flexure.

The instruments necessary for the ocular inspection of the sig-

moid flexure, or sigmoidoscopy, are sigmoidoscopes varying in length ~~from nine to fourteen~~ inches, and from five-eighths to an inch in circumference, and the long alligator forceps. The instrument devised by Kelly (Fig. 34) is very serviceable, but its employment has been made much easier by the use of an obturator whose projecting extremity tilts so as to allow of easier introduction in rounding the curve of the sacrum. Tuttle has

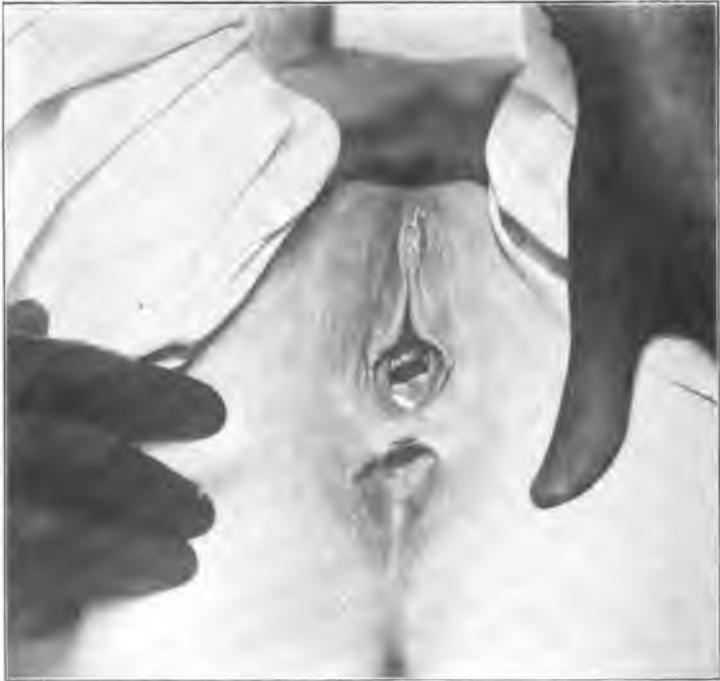

Fig. 41.- Atresia ani vaginalis (incomplete). This photograph, taken from one of the author's cases, differs from the preceding in that, while the patient passed her stools through the vaginal opening, the anus was not entirely occluded, there being a small anovaginal fistula. This patient was 23 years old, and had a remarkably well developed sphincter vaginae, and was able to control well her fecal movements through the vulvar orifice. This case was likewise operated on, and the rectum restored to its normal position with a good functional and cosmetic result. The external sphincter muscle was more fully developed in this case than in the preceding one, and control followed much more rapidly.

devised such an instrument, as has also the author (Fig. 35). The only instrument required is a long alligator forceps for use in swabbing out the sigmoid cavity and for the purpose of removing tissue for microscopical examination. Sigmoidoscopy

may be accomplished with the patient in the knee-shoulder position, but ~~much more~~ <sup>more</sup> satisfactory results are obtained from the employment of the exaggerated lithotomy position. Dr. Granville S. Hanes, of Louisville, Ky., has introduced the inverted position for sigmoidoscopy (Figs. 37, 38).

The use of the pneumatic sigmoidoscope is of the highest value in the diagnosis of all lesions or diseased conditions located above the rectosigmoidal juncture. The Tuttle instrument (Fig. 32) or any of its modifications will be found very useful.

**Examination for Congenital Defect or Malformation.**—Before leaving the subject of examination of the patient, the author would advise his readers to carefully examine every patient to make sure that there is not present some congenital defect or malformation of the anus or rectum (Fig. 39). Every infant at birth should be examined by the attending obstetrician to make sure that the anorectal canal is patent, as imperforate anus, while said to occur but once in 10,000 cases, seems to the author, in his own experience and that of his professional friends with whom he has consulted, to have occurred far more frequently. If imperforate anus is not recognized, the child will die in either a few hours or days if the condition is not remedied, and even then, the operation is attended with a very high mortality; or nature will occasionally form a new outlet for the escape of the feces. In girls this happens more frequently through the vagina, and in male infants through the scrotum, bladder, or urethra. Five cases have come under the author's notice in which girls were allowed to grow to womanhood with congenital defects so serious as to preclude the possibility of marriage until remedied. In two (Fig. 40) there was a complete absence of an anal orifice, in one (Fig. 41), an aperture about one fifth of the normal size. In all of these cases, defecation took place through the false opening into the vagina. In the other two, a portion of the stools passed through both openings.

## CHAPTER IV

### CONSTIPATION AND OBSTIPATION

Constipation is, and always will be, one of the most common conditions affecting the human race. Some writer has put it that "every other man and every woman is constipated." While this statement may be somewhat of an exaggeration, it is a fact nevertheless, that constipation, or at least some interference with normal defecation, is the most common and most prevalent affection of the human race.

No patient who comes into the office of the average physician is turned away more quickly with a single prescription for some drug or combination of drugs than the constipated individual. This patient whose condition is one whose diagnosis cannot be made without a careful inquiry into his history, habits, and mode of living; and without a most careful and complete local examination of the organs most involved, is the one, above all others, who is suffering from infrequent, irregular, or incomplete excretions from his alimentary tract, and loosely classified as the *constipated* patient.

Because of thoughtless, careless, or unscientific medication by practitioners who are either "too busy" to give the patient the proper time for a careful consideration of his case, or because of a lack of knowledge on the part of the practitioner who has been graduated from college without any training in the methods of rectal and sigmoidal examination, or the treatment of diseases of the intestinal tract, particularly of the large bowel, the majority of patients suffering from so-called constipation have been driven to self-medication by means of proprietary cathartic preparations, and have been lost to the legitimate practitioner of medicine. Many a patient has become a slave to cathartics and enemata, and has exhausted the laxative properties of one preparation after another, because of the fact that when he did consult his physician he was

given a prescription for "A. S. & B. pills," or "a dose of salts" every morning, and that was all there was to his treatment.

Constipation may be defined as the voiding of insufficient

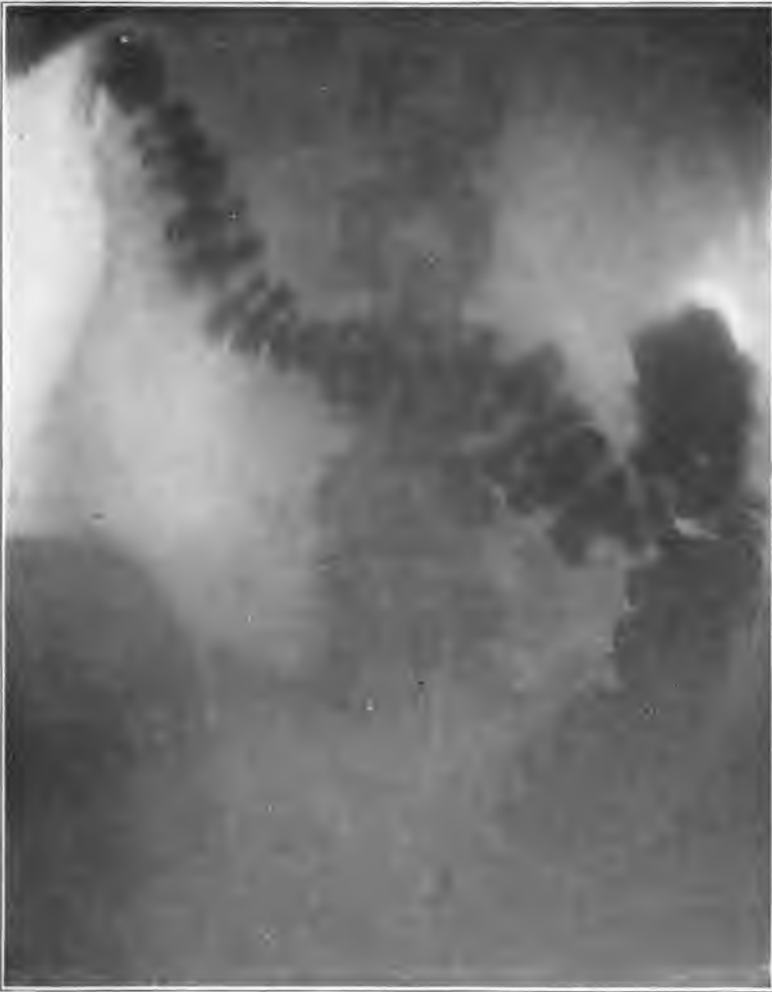

Fig. 42.—Showing normal segmentation of colon up to splenic flexure. Descending colon contracted and atrophied.

amounts or the abnormally prolonged retention of fecal material in the intestinal canal. Murray suggests that constipation should be defined as "The abnormal retention of waste products in the

human system." Constipation, in contradistinction to obstipation, is due to purely functional diseases or conditions of some portion of the intestinal tract. Obstipation, on the other hand, is a condition in which there is a sufficient quantity of fecal material,

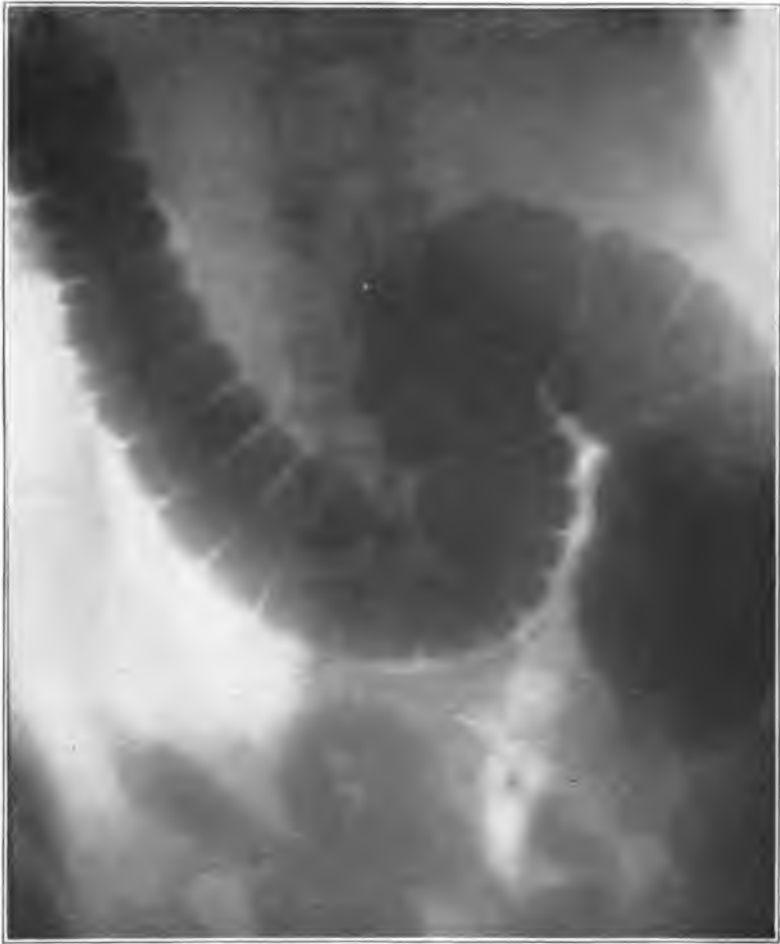

Fig. 43.--Tremendous overdistention of ascending, cecum, and transverse colon, due to obstruction at splenic flexure.

and a normal functional activity; but in which some deformity, growth, flexion, constricture, or foreign body in the intestinal canal offers a mechanical obstruction to the passage of the fecal



current. These two conditions are so frequently confounded in the mind of ~~the average practitioner~~ that the distinction must be always borne in mind; for the treatment of these conditions, while they may present similar symptoms, is entirely different.

Constipation is really but a relative condition. One individual may have two or three passages daily and still be constipated, while another individual may have but one passage a week and this condition be normal for him.

Constipation in itself is not a disease but merely a symptom of a great many diseased conditions, but is so often the only apparent or "foundation" symptom of which the patient complains, that its discussion as a separate disease entity is deemed proper.

Obstipation is caused by such mechanical conditions as malformations of the intestinal canal, stricture, adhesions, pressure from the pregnant uterus and the various abdominal tumors, angulation, enteroptosis, stenosis of the ileocecal valve, fecal impaction, the presence of foreign bodies, hypertrophied rectal valves, prolapse of the rectum or sigmoid, large hemorrhoids, enlarged prostate, lacerated perineum, and hypertrophied or contracted sphincters.

Chronic constipation is a condition which affects a large proportion of all the patients treated by every practitioner of medicine. It is a condition which is brought about by our modern, so-called "strenuous life." We find it in the infant and in the nonagenarian. It is due to a great many factors, and in order that one may understand it more fully, the author will review some points in the physiology of peristalsis and defecation.

### PHYSIOLOGY OF DEFECATION

Up to the last moment at which the fecal mass is expelled from the anus, the ingested materials are carried through the intestinal tract by what is known as peristaltic action.

Recent studies of intestinal peristalsis, by means of repeated radiographs made of the large and small intestines after the ingestion of a bismuth meal, have given us some new light on the normal movements of the intestines. We know that it takes the contents of the small bowel four hours to travel from the pylorus to the cecum, the distance traversed being twenty-two and one-half feet in the average case. From the ileocecal valve to the

rectosigmoidal juncture the rate of progress is much slower, the average time being from fourteen to twenty hours. It will be

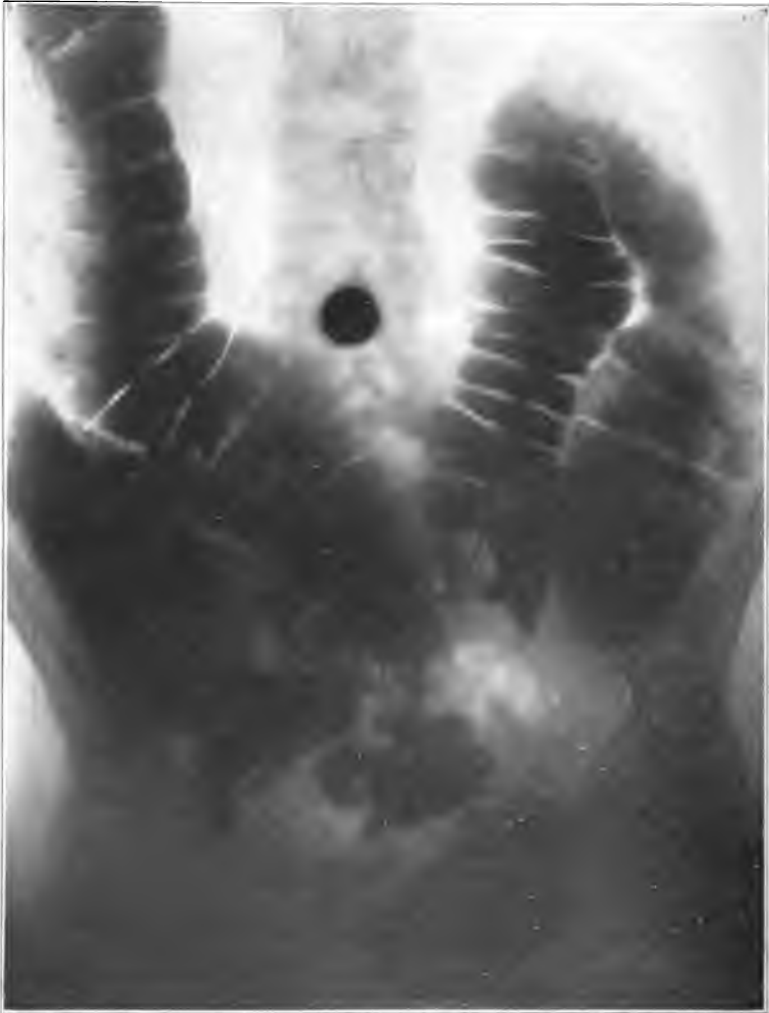

Fig. 44.--Megacolon, or hypertrophy of entire colon, with adhesions of prolapsed transverse colon in right iliac fossa.

noted, therefore, that the waste products of ingested food should normally be expelled approximately twenty-four hours after the meal. Retention longer than that period would make the indi-

vidual either a constipated or an obstipated patient, depending on the cause of this retention.

After the food has entered the stomach and the albuminoids are converted into peptones, it passes through the pylorus into the small intestine. As the stomach contents pass through the pyloric valve, they are acid. The secretions in the small bowel—the bile and the pancreatic juice—being alkaline when the acid contents are poured into the small intestine, coming in contact with the alkaline intestinal secretions, a stimulation, or irritation, is caused, which produces a wave of muscular contraction, or peristalsis, called segmentation.

At the same time that the chemical reaction of the stomach contents on those of the intestine is going on, certain gases are created. These gases serve to distend and increase the caliber of the bowel, and by this distention still further stimulate muscular contractions. These gases are not abnormal but serve a most useful purpose. It is when they are in too great quantities, and too severe peristalsis and consequently too great distention of the intestinal canal are produced, that they are harmful. They then cause atony or paralysis of the circular muscle-fibers and loss of muscular tone. These gases are largely reabsorbed by the blood-vessels or discharged from the anus. If these gases in their downward passage meet any obstruction, they are forced backward into the stomach and may be discharged in this direction. The role of so-called hormones in the physiology of defecation has by no means been conclusively proved.

Another very important source of stimulation to the coats of the bowel is the harsh, indigestible particles of food, familiarly called "ruffage," which are not acted upon by the digestive secretions. These also irritate the mucous lining of the bowel, and stimulate the contraction of the circular muscular fibers of the small intestine. Of no small importance is the stimulus caused by the to-and-fro movement imparted to the bowel by the movements of respiration. The upward and downward excursions of the diaphragm impart to the small bowel in particular, but also to the transverse colon, a movement which stirs up and churns, as it were, the intestinal contents. The respiratory movements change the position of the bowel, and help to keep the intestinal contents on the move. It can be easily seen, therefore, how any article of clothing, or pos-

ture assumed, or certain occupations which restrict and prevent the full expansion of the chest will interfere with the intestinal functions and assist in causing constipation.

The intestinal contents are fluid until they reach the iliocecal valve. In the cecum they become less fluid, and having to travel against the

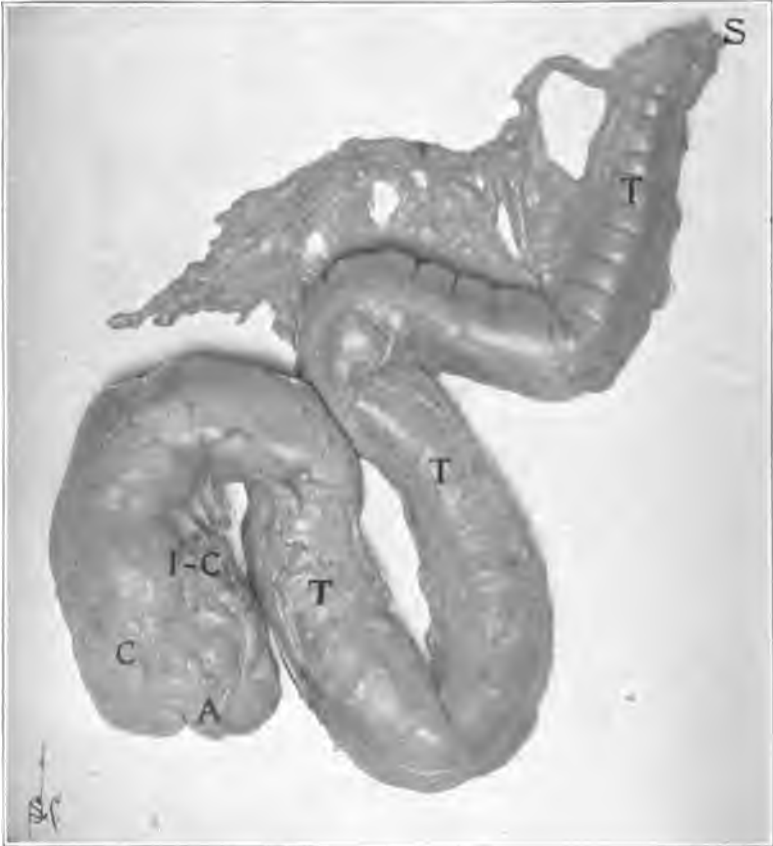

Fig. 45.—Specimen shown in Fig. 44 after removal.

force of gravity, their movement in the large bowel is checked. Remaining, as they do, in this portion of the bowel for fourteen to twenty hours, the fluid constituents are gradually absorbed, and the nearer to the sigmoid the feces, the more solid they become. The mucous membrane of the colon is thicker and not so sensitive as that

of the small intestine and requires more stimulation; consequently the stools are more solid in this portion of the bowel. If, however, an excessive amount of vegetable fiber and indigestible material is present, the colon tends to become overstimulated, overdistended,

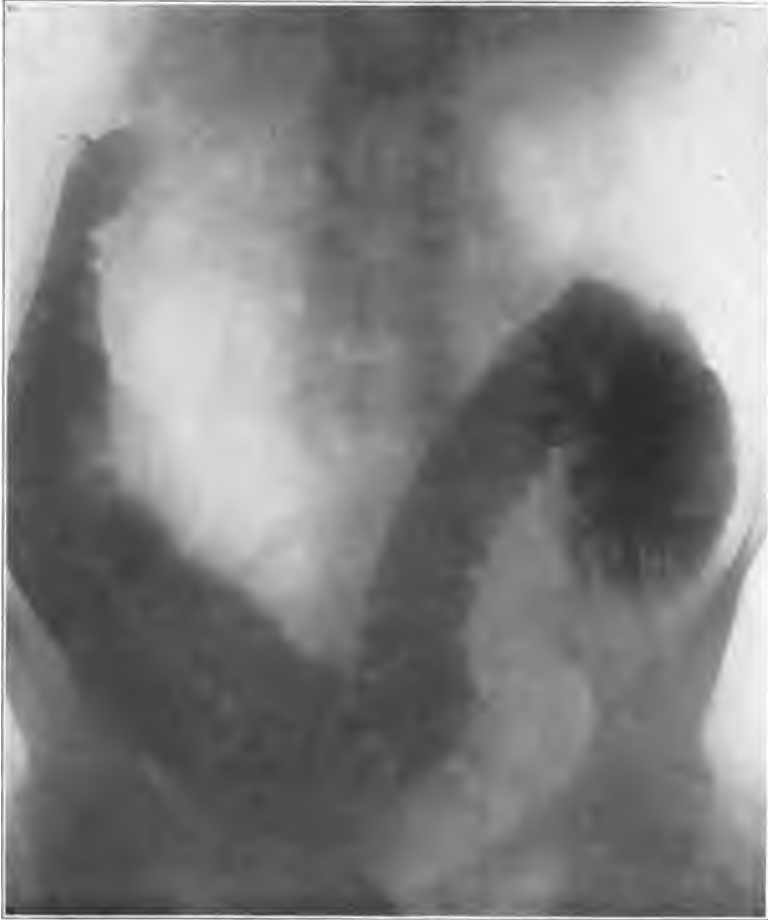

Fig. 46.—Coloptosis with angulation and adhesion of transverse colon—accentuation of splenic flexure.

and atonic; the fecal mass moves very slowly, and chronic constipation, and sometimes fecal impaction, results. The fecal material, when it reaches the sigmoid, rests until ready to be passed out through the rectum and anus, as a fecal movement.

This reabsorption of the toxins mentioned above, which toxins are in solution, causes an autotoxemia, which in itself is responsible for the symptoms improperly called "bilious." The large intestine is, in fact, one of the most important foci for all of the symptoms now known to be due to "focal infection." Among these symptoms may be enumerated rheumatism, neuritis, dizziness, vertigo, headache, loss of appetite, foul breath, mental sluggishness, a lack of ambition, nausea, and in some cases periodic attacks of vomiting, and a general feeling of fatigue and listlessness. The liver is more often upset by the absorption of toxic material from the large bowel through the portal circulation than are the so-called syndrome of biliousness and so-called torpid liver causes of constipation. Bile is not nearly so important a factor in normal peristalsis and defecation as was formerly thought. Its presence does not stimulate peristalsis in the small intestine to any appreciable degree. In fact, its presence is not necessary for the production of peristalsis or defecation. It is merely the excretion of the liver containing the waste products remaining after the liver's performance of its more important functions of detoxifying poisons that enter the body by way of the gastrointestinal tract; to store up some of the excess of fat taken as food, and to release it when the external supply becomes deficient; to store up glycogen and to convert it into glucose and liberate it as required by the system; to assist in the metabolism of the proteins to the extent at least of forming urea or ammonia compounds, and other minor functions. The poor old liver has trouble of its own without being blamed for all of the cases of constipation in the world.

The argument advanced by some, that the administration of a laxative, which by increasing the flow of bile and by unloading the liver, empties the bowel, thereby relieving the symptoms of autointoxication, is conclusive proof that the liver is at fault in the matter, loses its force entirely when we recall that many cases of autotoxemia are relieved by the mechanical cleansing action of an enema or colon flush. This, of course, acts without the assistance of the so-called natural purgative bile. The erroneously named "liver pill" accomplishes the same result by its purgative action, without regard to the fact of its having a cholagogic action or not. The fact that bile is not essential to normal defecation is illustrated very nicely in the normal intestinal peristalsis and defecation, taking place in patients

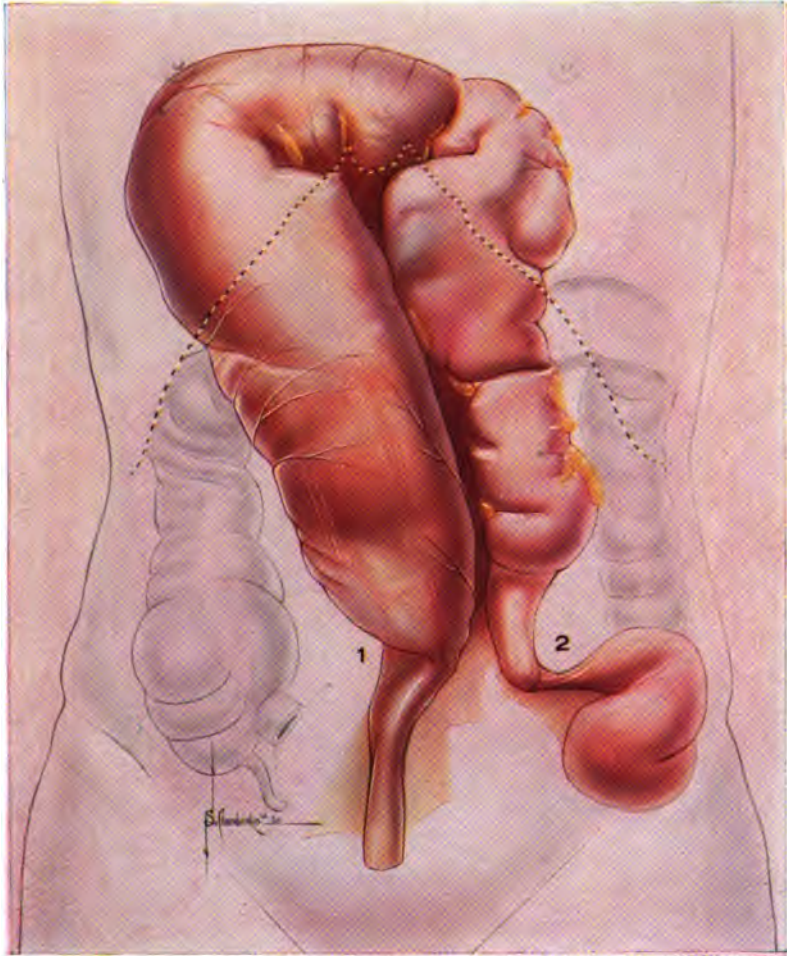


PLATE III.

Giant sigmoid colon. This case illustrates the extreme limits to which dilatation of the colon will go.

1. Volvulus at juncture of descending and sigmoid colons.
2. Volvulus at restosigmoidal juncture.

(From the anatomical laboratory of the Detroit College of Medicine, through the courtesy of Dr. F. N. Blanchard.)

[www.libtool.com.cn](http://www.libtool.com.cn)



suffering from a permanent biliary fistula, and who have no bile in the intestinal tract at all.

### ETIOLOGIC FACTORS

It can readily be seen that anything which interferes with the proper development and exercise of the intestinal musculature will interfere with the proper movement of the intestinal contents and with their expulsion at the proper time. In the first place, enough fluids must be taken daily into the system to keep the intestinal contents in solution and to properly supply the various organs of the body. On the other hand, people who do not drink sufficient water suffer from constipation because of the reabsorption of fluids from the intestinal tract and resulting hard and dry stools. People who drink great quantities of water *with their meals* do not sufficiently masticate and drown their stomach contents; undigested particles of food are sent through the pylorus with large quantities of greatly diluted gastric juice; the feeble acid reaction of this mixture does not cause the proper reaction with the alkaline intestinal contents; the proper amount of gases is not evolved, and quantities of intensely irritating food particles are passed down the small bowel. This is another cause of loss of tone.

It is a well-known fact that carnivorous animals are constipated, while the herbivorous animals have full and frequent bowel movements. Realizing this fact, it therefore behooves us to see that a sufficient quantity of ruffage or vegetable material, which will leave undigested fiber in sufficient quantities to produce stimulation of the muscular fibers of the bowel, such as corn, cabbage, celery, carrots, beet tops, lettuce, spinach, watercress, endive, kale, and other green vegetables, as well as seed vegetables and fruits, is incorporated in our daily regimen. The dietary should also contain a sufficient quantity of mineral salts, particularly sodium chlorid, which are natural laxatives. It should also contain sweets within reasonable limits, because of the gas development which they cause, bearing in mind the fact that carbon dioxid gas is one of our best laxatives. Above all, the food must not be concentrated; it must give sufficient bulk to the stool so that it will properly fill and distend the bowel, give it work to do, and thereby produce the proper stimulation to contraction, which is distention. The value of oatmeal, whole wheat

bread, and bran lies in the quantity of cellulose in the husk, which is a very important element in the stimulation of the mucous lining of the bowel. People who frequent the quick-lunch counter and who devour a full meal in ten minutes do not properly masticate their

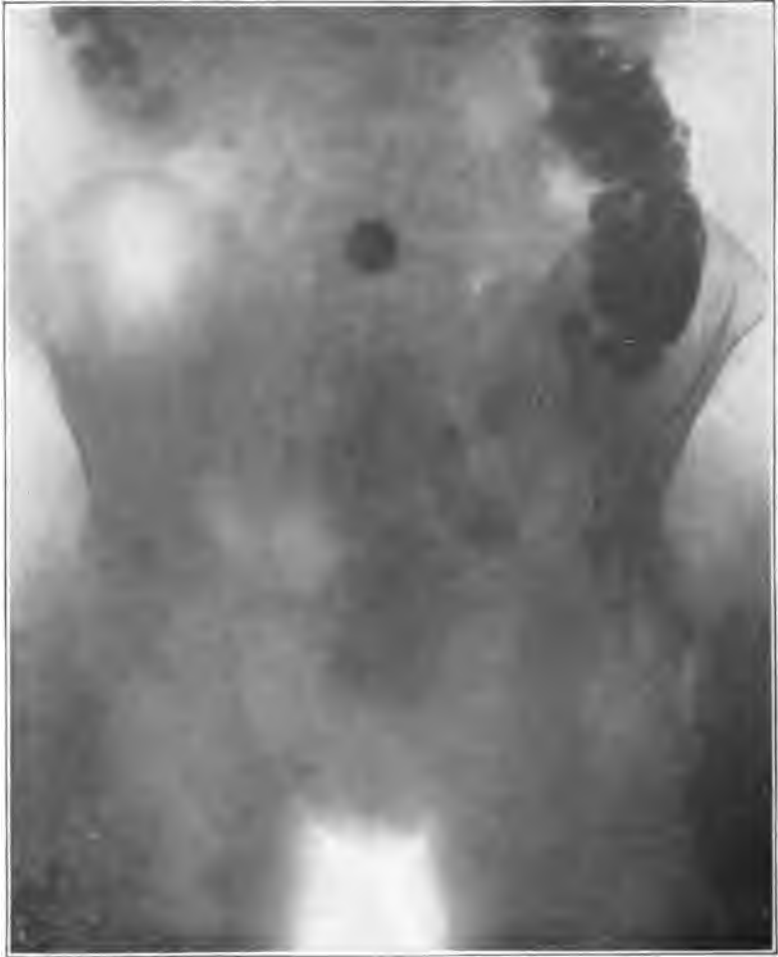

Fig. 47.-Bismuth meal passing from ileum to cecum (see Fig. 48).

food, thereby causing incomplete stimuli to peristalsis, and consequently improper stools.

Outside of dietetic error, the most common cause of constipation

is neglect. The school child receives the call of nature, the fecal mass is ready to be extruded, he is receiving powerful stimuli for the dilatation of the sphincters and the expulsion of his bowel contents;

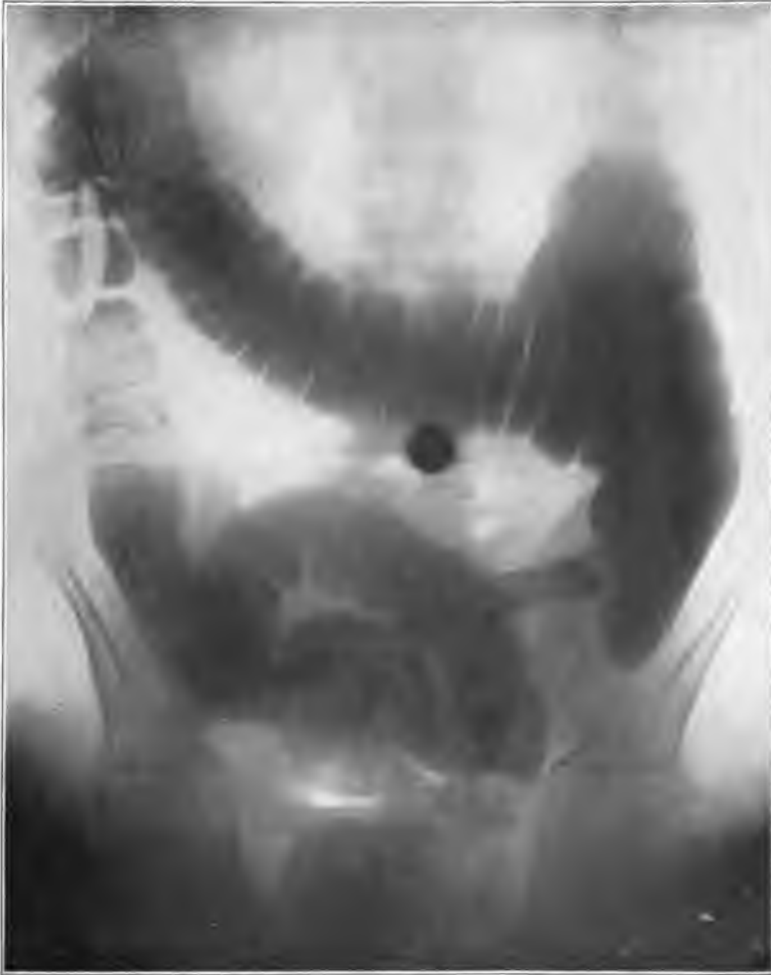

Fig 48.—Same as preceding with whole colon injected with bismuth, showing distention of cecum, hepatic flexure, and transverse colon, angulation and looping of sigmoid.

but in our modern schools the lesson hour is more important than the functions of nature! The child is not allowed to go and relieve himself. He resists and restrains nature's efforts, and the desire passes

away. The continuance of this performance day after day soon makes ~~the child~~ **chronically** constipated.

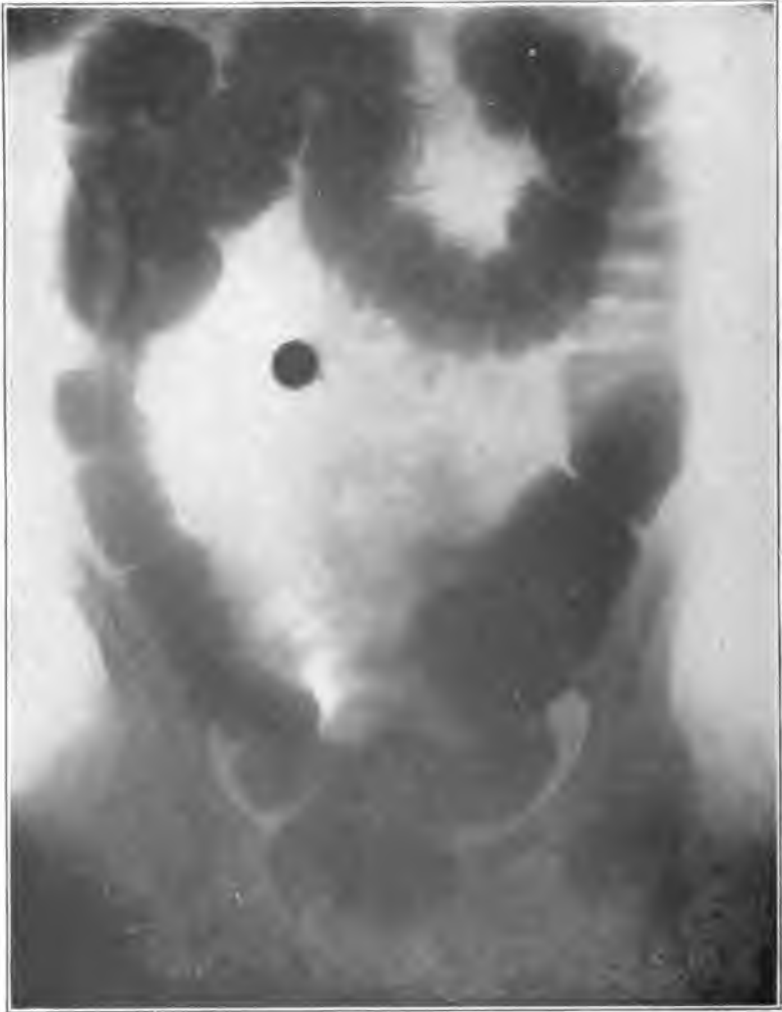

Fig. 42.—Ptosis of cecum, looping and adhesion of redundant transverse colon, and figure-of-eight loop replacing splenic flexure.

While peristalsis is involuntary, in the vast majority of people the voluntary control over the sphincter is normally sufficient to withstand peristalsis. The strong explosive efforts soon weaken when

opposed and retarded by a tightly contracted sphincter, and shortly the constipated habit is induced. The young girl in society is taken

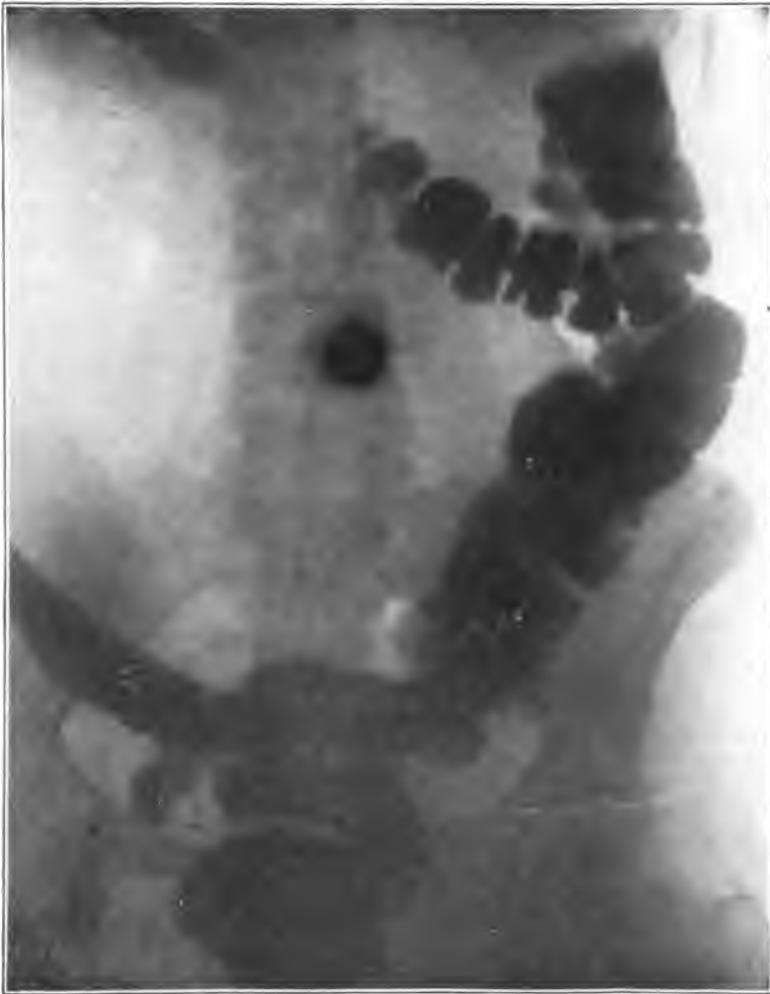

Fig. 50.—Ptosis of cecum, acute angulation of hepatic flexure, and the lower part of the illustration showing hypertrophy of second rectal valve.

with a desire to move her bowels; and either because the time is not convenient and she restrains nature's efforts, or because she may be willing to satisfy nature's desire, but the location of the toilet

room is such that the nature of her errand would be evident to others whom she would be obliged to pass, and false modesty prevents her from allowing her friends to see her go even in the direction of a retiring-room, she restrains nature's efforts, the desire soon passes away, and she thus becomes constipated. This is quite different from Continental Europe, where false modesty is unknown. When nature calls, she is answered, often with a promptness in public places which is rudely shocking to unsophisticated Americans. The fact remains, however, constipation is not so common in these localities.

A very important provision in architecture of homes and other buildings should be the placing of toilet rooms in such inconspicuous places that a person may reach the same without being subject to the gaze of others, and the making of the seats of such a height as to force the user to assume a squatting posture.

The business man, the professional man, the traveler—yes, even the physician—all refuse to obey nature's call, because they are too busy or the time does not happen to be convenient; and thus, because we cannot find time to move our bowels when they should be relieved, we have become a constipated nation. As a result, the newspapers, magazines, and signboards flaunt the advertisements of cathartic syrups, cathartic pills, candy cathartics, and aperient waters in our faces wherever we may turn. This neglect and indifference, in our humble opinion, is the most important cause of constipation.

Another contributing cause to the voluntary repression of defecation is the fact that schools, office buildings, and institutions generally, which are occupied or inhabited by a large number of people, do not have anywhere near enough toilet rooms for the number of inmates. Where one has to wait long for his turn, the time allowed and the desire for defecation is soon lost.

The shape of the closet seat and its height from the floor are of importance in the production of a good stool. The seat should be so constructed that the person using it has to assume the squatting position, instead of the ordinary sitting. The buttocks should be well separated so as to allow the free excursion of the muscles, which go to make up the pelvic floor, downward and upward, and the full action of all the other muscles involved in defecation brought into play.

People leading sedentary lives, who do not get sufficient exercise, are, of course, constipated. Exercise is one of the important factors in keeping all of the bodily functions normal. There are many other

causes which may contribute to the production of constipation in individual cases, but those mentioned are the most common, and by far the most important.

When the bowel has become atonic, remedies to restore its tone must be employed. In the treatment of acute constipation, cathartic drugs, suppositories, enemata, all have their proper place, but the victim of chronic constipation should no more be made a victim of the drug habit than the patient suffering from chronic appendicitis. Instead of causing irritating, irregular, erratic, and violent peristaltic movements at certain times during the day, and instead of changing from one cathartic to another and increasing the dosage—instead of taking away the natural physiologic work of the bowel by flushing enemata—we should strive to bring that bowel back to its normal tone by imitating nature's method. The only place for a cathartic in the treatment of chronic constipation is at the beginning of the treatment.

### DIAGNOSIS

When a patient consults you, complaining of infrequent or insufficient bowel movements, the first thing to do is to make a diagnosis between constipation and obstipation. The patient should be examined carefully; and here the author wishes to state that, if the general practitioner of medicine would make it a routine practice to examine the anus, rectum, and sigmoid of every patient who presents symptoms directed toward these organs, he would meet with much greater success; and he would discover that the treatment of ano-rectal diseases is not nearly so distasteful as he had heretofore thought.

The author holds that no patient, presenting the symptoms of interference with the regularity or quantity of his bowel movements, should have any treatment, without that patient being subjected to a complete digital, anoscopic, proctoscopic, and often sigmoidoscopic examination, in order to make a definite diagnosis. The patient suffering from the symptoms of constipation is just as much entitled to a proctologic examination as the one suffering from a cough is to the inspection, auscultation, and percussion of the chest. Every patient, male or female, should receive a bimanual rectoabdominal examination, and the female patient the vaginal examination in ad-

dition. In the male patient the condition of the bladder and prostate should be carefully noted.

In examining with the proctoscope, it is advisable always to place the patient in the knee-shoulder (Fig. 24) position, so that the rectum may be well dilated by the pressure of the atmospheric air, or the pneumatic proctoscope (Fig. 32) should be used. The author would suggest that every case suffering from constipation should be examined first in the constipated condition, so that the location of the stools in the lower bowel may be made out, and the mechanical obstruction, if present, located. Then an enema may be given, and the examination may proceed.

If the cause is still undiscovered, radiography should be resorted to for a diagnosis. The technic of the injection of bismuth for radiography of the colon which has given me the most satisfactory results is as follows:

After a cleansing enema is given, the patient is put in the left lateral position, and from a pint to a quart of a mixture of two ounces of bismuth subcarbonate to the pint of buttermilk or potato soup is slowly injected, using a short rectal tip. The irrigator is elevated two feet above the anus when the patient is in this position. From six to ten minutes is allowed for the injection of the fluid. As soon as the solution starts to flow, he is turned on his back. This allows the fluid to flow around to the cecum, and unless obstructed by some unusual pathologic condition, will give a good shadow. The flow of the opaque enema is carefully watched by means of the fluoroscope, and when its progress is halted at any time, manipulation will assist in determining whether an obstruction is present or not. The site of the umbilicus is marked with a coin held in place by adhesive plaster, and stereoscopic plates made with the patient either lying on his abdomen, or standing with the abdomen pressed against an upright frame. Occasionally it will be found that the addition of some inert substance, such as fuller's earth in the proportion of two ounces to the pint, will help to make a better mixture. Also barium mixture is used instead of bismuth, and instead of the buttermilk, acacia or sugar added to a pint of water in sufficient quantity to make a syrup of the desired consistency will answer very nicely.

If one is desirous of timing the activity of the small bowel, it is well to administer one ounce of bismuth subcarbonate in eight ounces



of buttermilk by mouth, and to make frequent fluoroscopic observations until the bismuth is seen entering the ileocecal valve (Fig. 47). [www.libtool.com.cn](http://www.libtool.com.cn)

The causes of many cases of so-called constipation which were aggravated in type and uninfluenced by any internal medication or physical therapy have been made very clear since the employment of radiography of the intestinal tract. A great many of these cases have been shown to be obstipation, the obstruction being due to exaggeration of the normal flexures, angulation, or ptosis, with or without adhesions, and the colon has been found to be the chief seat of the trouble in over 95 per cent of the cases. The small intestine is very seldom at fault. The accompanying radiographs almost tell their own story.

Fig. 42 shows a total lack of function of the descending colon, due to atrophy of all of its coats.

Fig. 43 shows a condition of extreme compensatory dilatation of the cecum, ascending and transverse colon, caused by an acute exaggeration of the normal angulation of the splenic flexure with adhesions. This case required exclusion of the diseased portion and ileosigmoidostomy for its relief.

An extreme type of dilatation of the entire colon is shown in Fig. 44. In this case coloptosis was also present in a marked degree, the transverse colon being angulated and adherent in the right iliac fossa below the cecum. This case required the extirpation of all of the colon from the cecum to the splenic flexure for relief. The section of bowel removed (Fig. 45) measured forty inches in length, the cecum fourteen inches in circumference, while at the splenic flexure the circumference was eight inches. When distended with water to the dimensions found on operation, it requires three and one-half quarts. This patient would go from ten to fourteen days without a movement, and on one occasion, went four months.

Ptosis of the transverse colon with adhesions in the pelvis, as well as the exaggeration of the hepatic and splenic flexures, is well shown in Fig. 46, which was taken with the patient in the Trendelenburg position.

The overdistention of the colon caused by nature's efforts to overcome an obstruction of the sigmoid is shown in Fig. 48, 51, 52. The acute angulations of the sigmoid will be noted, as well as the disten-

tion of the hepatic flexure. The ileocecal juncture is well shown. The preceding illustration (Fig. 47) was made from the same patient

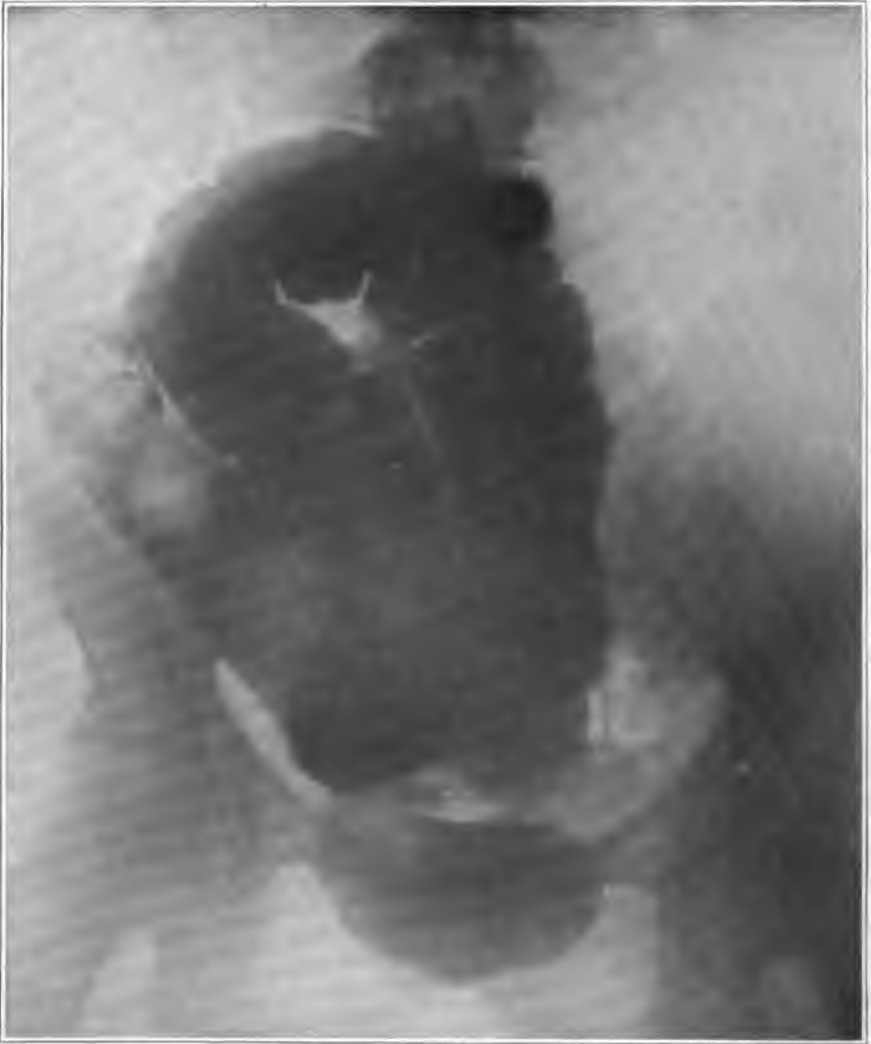

Fig. 51.—Hypertrophy of sigmoid or pelvic colon due to adhesions at recto-sigmoidal juncture.

as Fig. 48, before the bismuth was injected from below, and shows the bismuth meal, given ten hours previously, entering the cecum from the ileum.

In Fig. 49 we have a case of redundant transverse colon adherent and looped up under the diaphragm, and the splenic flexure replaced

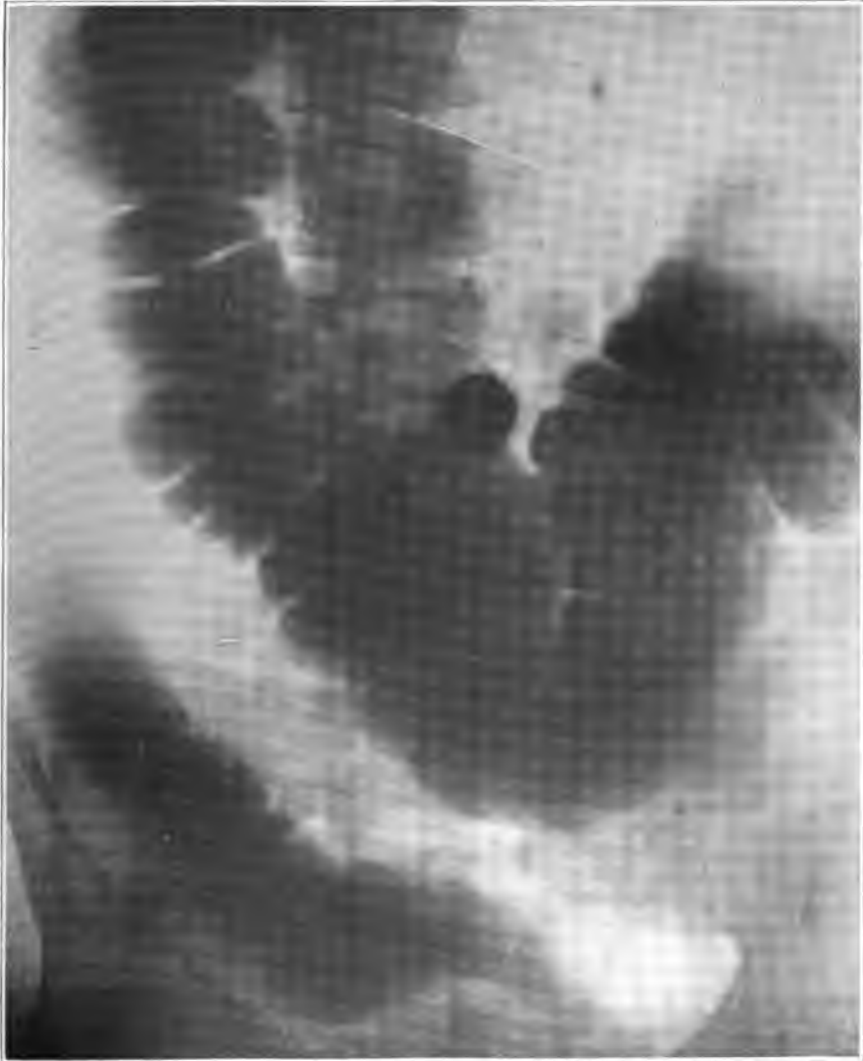


Fig. 52.—Hypertrophy of transverse colon associated with tuberculosis of ileo-cecal valve.

by a figure-of-eight loop of the bowel. The cecum is enlarged and prolapsed, and the hepatic flexure exaggerated.

In Fig. 50 we find this acute exaggeration of the hepatic flexure well marked. There is also distention and ptosis of the cecum, and the lower part of the radiograph shows the indentation made by the presence of a hypertrophied rectal valve. Figs. 51, 52, 53, 54, 55, and 56 are self-explanatory, and show the great and valuable assistance radiography offers the proctologist.

The series of radiographs shown here are selected from a large collection in the author's possession and are presented for the purpose of showing the futility of treatment directed toward the relief of constipation without making use of all of the diagnostic methods at our disposal. Every one of these cases required major surgical procedures for their relief, such as colectomy, exclusion, ileosigmoidostomy, resection of the diseased portions of the colon, lateral anastomosis, breaking of adhesions, mesenteric suspensions, and other operative measures which are not within the scope of this work.

If, after a careful physical, proctoscopic, and radiographic examination of the patient, none of the mechanical obstructions mentioned at the beginning of this chapter are present, the case is, in all probability, one of functional origin, and is a true case of chronic atonic constipation. In the course of the examination, the dietary, habits, occupation, and the important facts about the patient should be elicited. When all examinations are completed, the question of treatment presents itself.

## TREATMENT

Dietetic excesses and errors should be corrected, and the patient instructed as to the time, the quantity, and the kinds of food he may take. If he is not able to properly masticate his food, he should be referred to the dentist, and his teeth put in perfect shape. He should be instructed to drink from six to eight glasses of water in every twenty-four hours—a full glass of cold or hot water on arising, and also on retiring. He should drink plenty of water between meals, but very sparingly while eating. It is essential that he eat a sufficient amount of vegetable foods, such as have been enumerated above, and not to pare such fruits as pears, apples, and peaches before eating them. He should take plenty of outdoor exercise, such as tennis, golf, horseback riding, bicycle riding, and best of all, long walks in the open air. Breathing exercises should be indulged in, and in some

cases massage of the abdominal muscles will be necessary to restore their tone. The "setting up" exercises of the army can be recom-

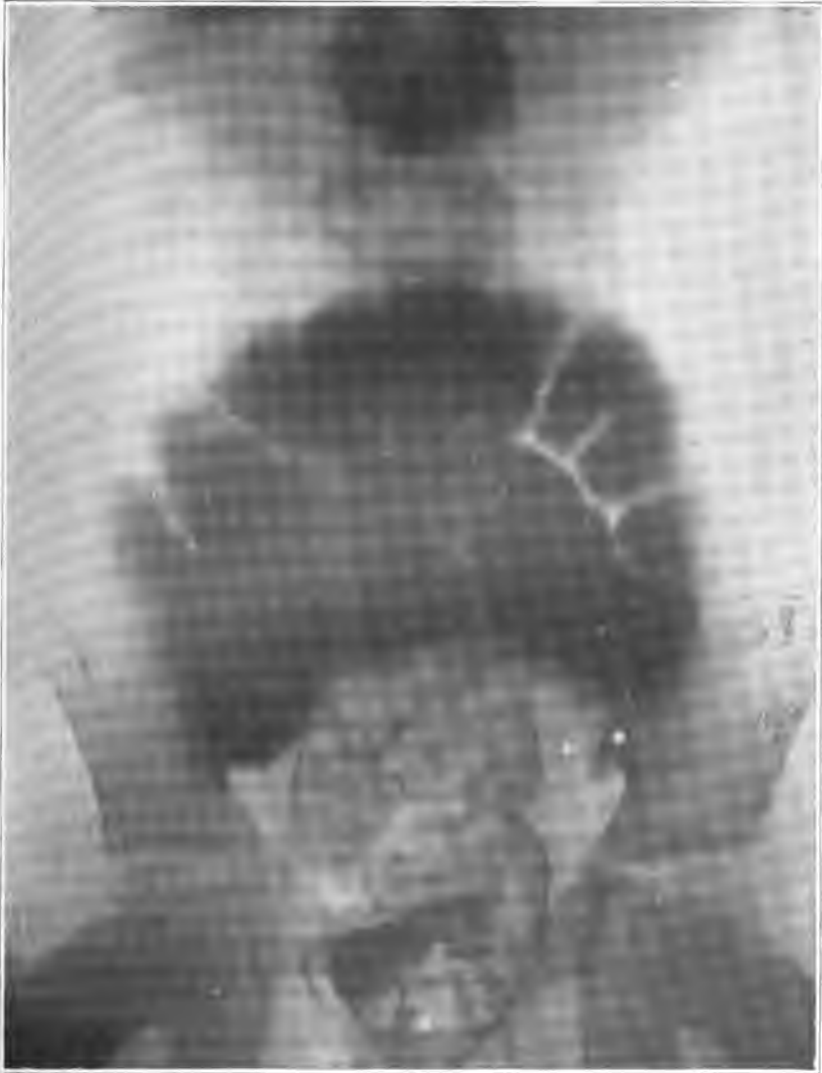


Fig. 53 -Congenital dilatation of sigmoid or pelvic colon and rectum in five-year-old boy.  
mended to the constipated patient, and, if persisted in, will be a great help in his treatment.

Any local condition, such as hemorrhoids (which of themselves do not **cause constipation** but are an effect of constipation, but by

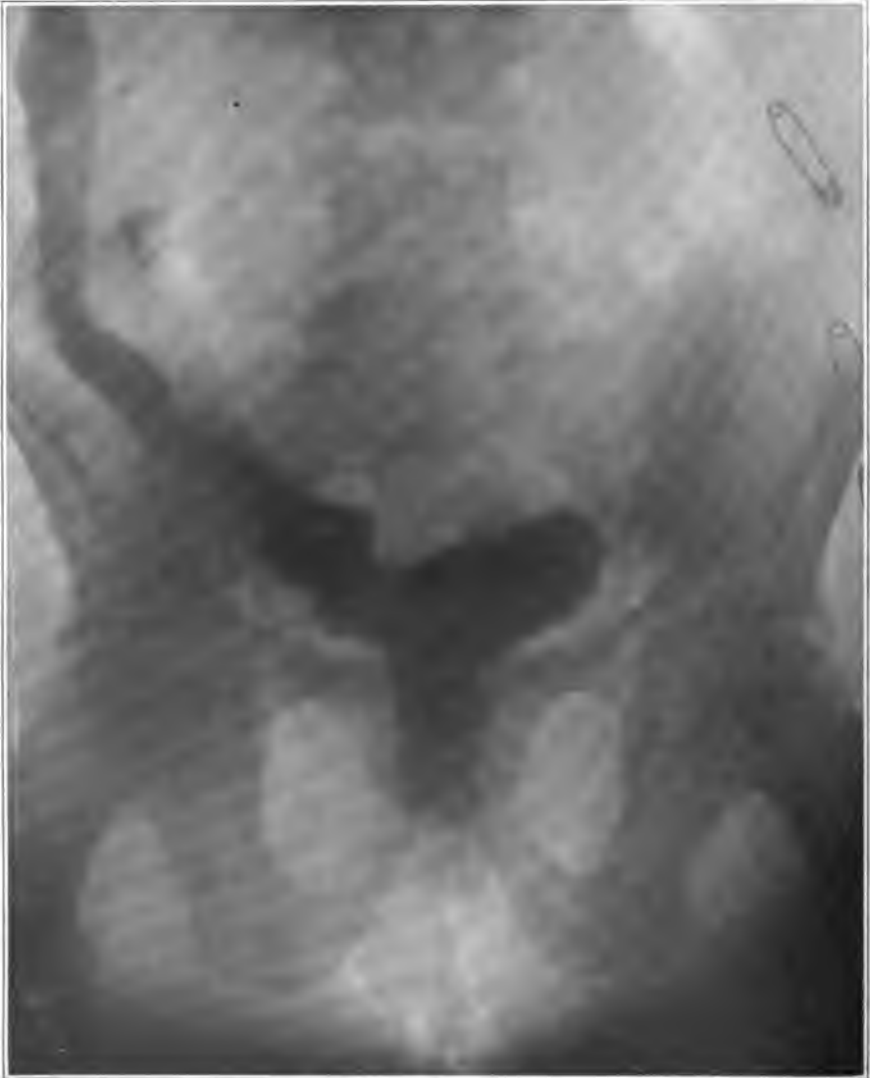

Fig. 54.— Sigmoid descending and pelvic colon.

their pressure prevent its relief by their interference with natural movements), should be corrected. Fissures, ulcers, or excoriations

of the anus should be remedied by surgical means or treated locally. Proctitis should be relieved by the proper dietary, and medications applied locally.

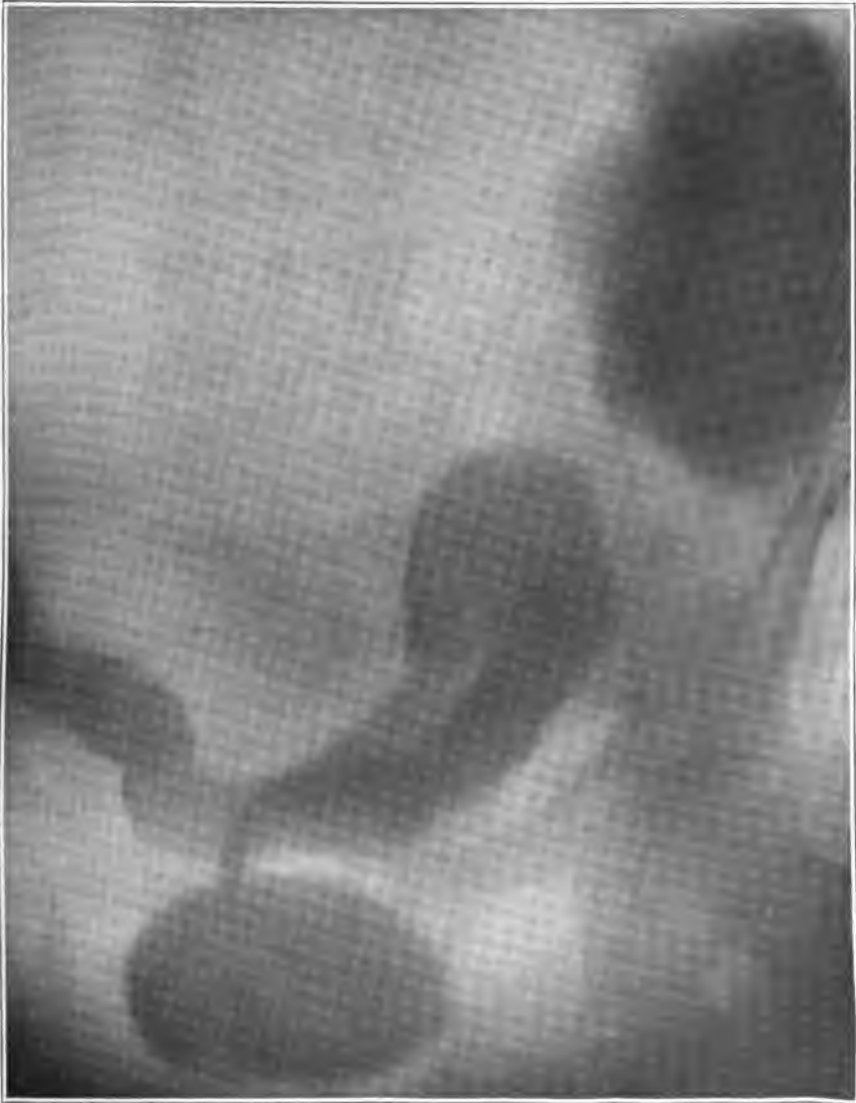

Fig. 55.—Stricture at recto-sigmoidal juncture.

Patients who are run down may require general massage, which should be given by a properly qualified masseur. If the sphincter is abnormally tight, it should be dilated under local or nitrous oxid

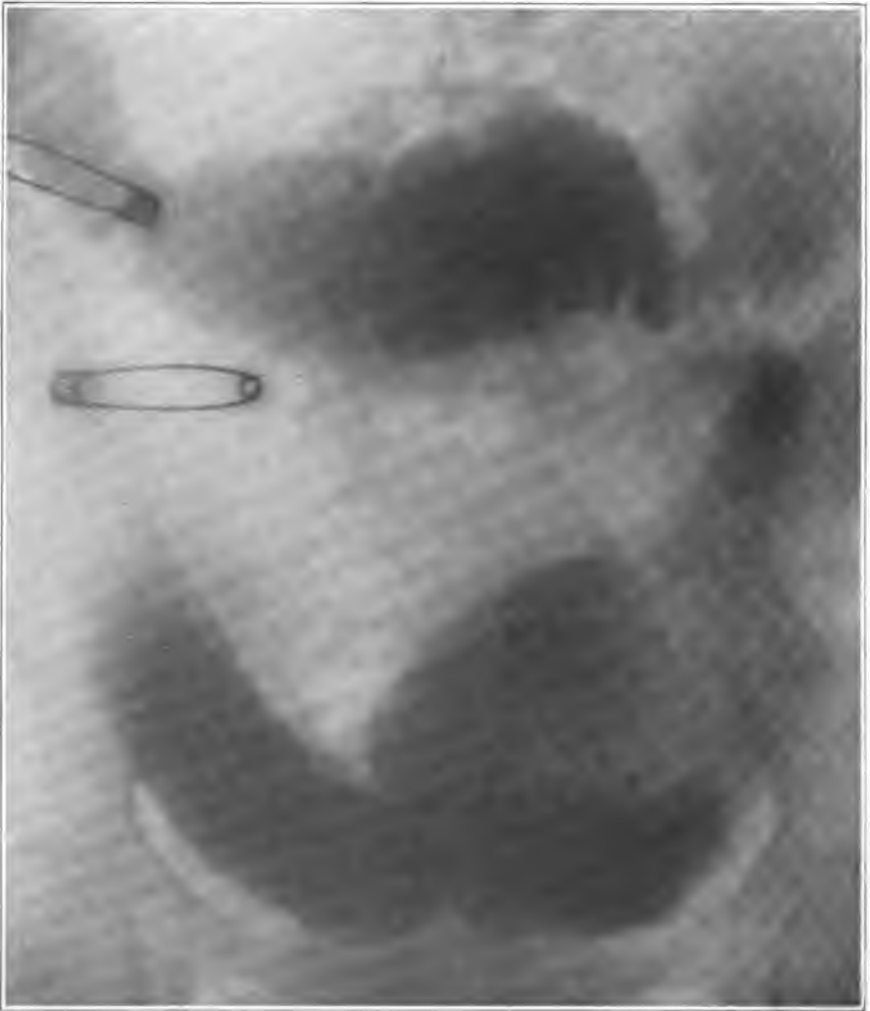


Fig. 50.— Stricture of transverse colon near splenic flexure due to carcinoma.

anesthesia, or by the use of a mechanical vibrator armed with a cone-shaped vibrator. Most important of all, however, the atonic rectum and sigmoid should receive internal massage.



A great many drugless methods of treating constipation have been offered to the medical profession. All kinds of electric treatments, external massage, cannon-balls, gymnastics, vibratory massage, baths,

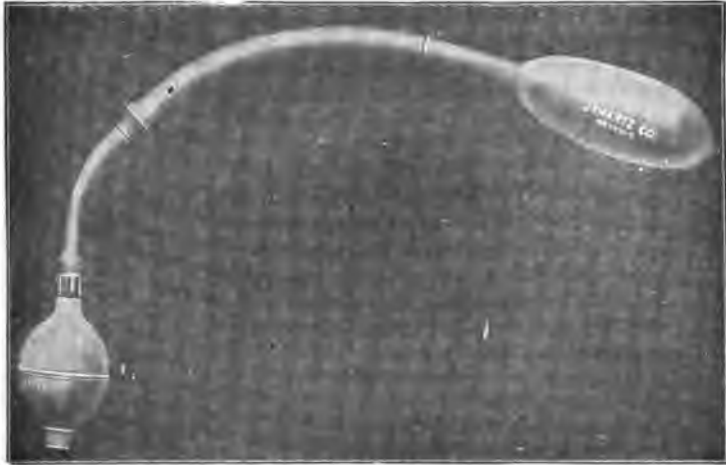


Fig. 57. -Author's pneumatic rubber dilating rectal massage bag equipped with a hand-bulb.

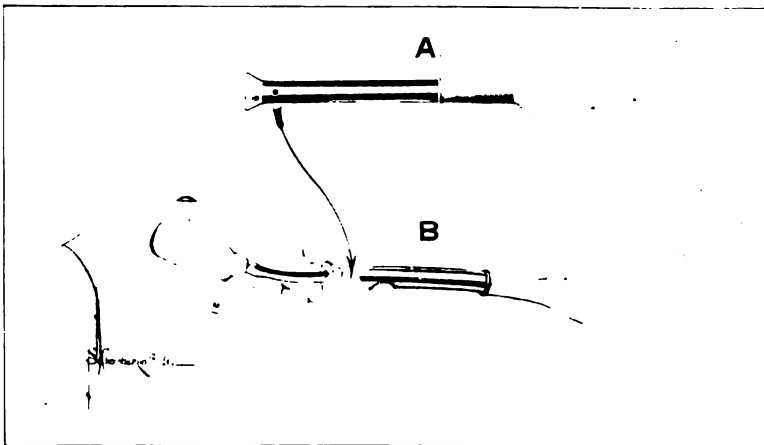


Fig. 58 - Author's rubber dilating rectal massage bag.

A. Bag deflated.

B. Showing the amount of inflation necessary in the average case.

and what not, have been tried, and while satisfactory results have been obtained from each of them in certain cases, there still seemed

something to be desired in the successful treatment of chronic constipation ~~without the use of~~ cathartic drugs.

The direct stimulation of the atonic sigmoid and rectum by means of mechanical dilatation has, up to the present time, given the best results. Rubber bags, which have been introduced through the proctoscope into the sigmoid and inflated, have been used by Turck and others with excellent results in some cases. Tamponing the rectum and sigmoid with cotton, wool, or gauze, as advocated by MacMillan, has, by its mechanical irritation of the mucous coat of the bowel and its simulating the normal bowel contents, produced satisfactory evacuation, in suitable cases. The inconvenience of carrying around a tampon or inflated bag in the rectum or sigmoid for from four to six hours, or more, has, however, been a serious obstacle to the more general use of these methods. Wells Teachnor, of Columbus, O., has successfully treated a number of cases by simple inflation of the rectum and sigmoid by allowing the entrance of air through the proctoscope, while the patient is in the knee-shoulder position, relying on the atmospheric pressure for dilatation.

**Author's Method.**—The author has devised and has been using for many years a very simple pneumatic dilator for accomplishing this distention, and has achieved very happy results from its use.

The apparatus consists of a specially shaped rubber bag (Fig. 57) provided with a stem, which is slipped over the distal end of a Wales bougie (No. 3 to 5); the Wales bougie is channeled and contains an air vent in the handle which is closed by the finger tip while inflating the bag. Compressed air at a low pressure (one to three pounds) is allowed to slowly enter the bag, and distention to any desired extent is produced. By means of an ordinary cut-off valve and pressure reducer this distention can be easily regulated. Where the compressed-air apparatus is not available, an ordinary atomizer bulb or a small bicycle pump can be utilized.

The technic of its use is as follows:

The patient is placed in the Sims position. The bag is twisted around itself on the bougie as an umbrella is rolled on its handle, lubricated, and passed upward into the rectum, first anteriorly until the anal canal has been passed, then posteriorly following the backward curve of the sacrum, then into the sigmoid to any desired

height. The Wales bougie, being firm enough to carry the bag up into the sigmoid, and at the same time, being flexible, does not create any discomfort or do any injury in its passage. It obviates the use of the proctoscope in its introduction. When the bag is in position, it is slowly inflated, until the patient complains of either fulness or slight crampy pain, or a desire to move the bowels (Fig. 58). The air is allowed to escape by removing the finger tip from the air vent in the handle of the bougie. Then, after an interval of five or ten seconds, it is again inflated to the point of tolerance. This treatment is

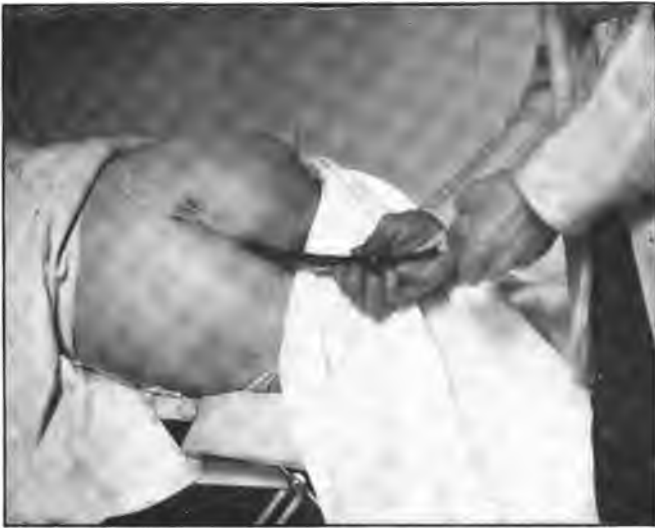

Fig. 59.—Position for the author's method of rectal massage. This is the best position for both the patient and operator in treating chronic constipation with the author's dilating rectal massage bag.

repeated for five to ten minutes in the average case. Then at the time of the last inflation, before removal, the cut-off valve, if the compressed-air tank is used, is disengaged, and the opening in the bougie is closed with the thumb; where the hand-bulb is used, the air vent in the handle of the bougie is closed with the finger tip, and then, by a to-and-fro motion, the apparatus is gently and slowly withdrawn. This method of removing the apparatus is of extreme importance as it massages the bowel as it is withdrawn, and also gently dilates the sphincter muscles (Fig. 59).

This treatment is repeated daily for from five days to a week, and

usually after the first or second treatment the patient will have a small unaided movement. Cathartics and enemata are, of course, strictly prohibited during the treatment.

Each day the patient will report a slightly larger and more satisfactory defecation, and often more than one movement in twenty-four hours. The patient is instructed to have a regular definite time for daily evacuations, and also to go to stool at any other time during the day, whenever he feels the slightest inclination to have a movement. Regularity is a very important factor in the treatment. When the defecation approaches the normal, treatments are given only on alternate days. After six or eight treatments, the interval is lengthened to two days, then to three, and then to four, when the patient is asked to report in five or six days. If he reports satisfactory evacuations daily, he is allowed to go a week, and then, if a similar report is made, he is discharged as cured, but asked to return for another treatment on the first day on which he does not have a normal movement.

*Under no circumstances is the dilator to be given to the patient for self-treatment.* It is impossible for a patient to successfully introduce the instrument or produce sufficient dilatation on himself to achieve results, and most of the failures reported to the author have been found due to this fact. The treatment must be given by the physician, never by the patient.

If the case is properly diagnosed and instructions as to a regular time for daily evacuations and strict obedience to nature's calls are faithfully carried out by the patient, as well as indulgence in a proper dietary, the results from this method of treatment will be very satisfactory, as the experience of several hundred practitioners in all parts of the United States and Canada will testify.

The patient must cooperate in every way. His mental attitude must be attuned to his treatment. When he attempts his daily evacuations, he must keep his mind on his work. Suggestion plays a large part in the re-establishment of a normal function, and functional constipation is peculiarly susceptible to constructive suggestion. The small boy who was promised a ticket to the "movie" every Saturday if he had a daily movement for the preceding week, proved the efficacy of suggestion in this condition!

The only internal medication which has been found necessary in

the author's experience has been the administration of extract of *nux vomica* in ~~one-fourth to one-half~~ grain doses before meals as a tonic to asthenic or run-down individuals. Pancreatin and oxgall in moderate doses before meals has been found of value in patients who show symptoms of intestinal indigestion. In those cases where starchy food is found difficult of digestion the administration of taka diastase in doses of four to ten grains has been found of service. The author has experienced great satisfaction for the last sixteen years from the administration of white refined petroleum oil, also known as liquid albolene.

This oil has no medicinal value whatever, is not a cathartic, or a food, and is not acted upon by any of the digestive secretions. It passes through the stomach and bowel and is expelled from the anus unchanged. It acts simply as a mechanical lubricant to the stool during its passage through the intestinal tract, softens hard masses which have been formed, and prevents the formation of others. A very satisfactory way of administering it is as follows:

℞ Olei gaultheriæ,  
 Olei menthæ piperitæ  
 Olei caryophylli, vel  
 Olei cinnamomi .....gtt. ii  
 Petrolati liquidi .....ʒiv  
 Sig: One tablespoon at bedtime.

The dose of the oil is gradually decreased until at the end of the treatment it is entirely withdrawn. From a study of the reports sent to the author by hundreds of physicians, and from his own experience with thousands of cases of all grades of severity and obstinacy, he would state that, if the case is properly diagnosed and the treatment persisted in, a cure will be effected in 85 per cent of the cases. In most of the failures reported to the author, correspondence with the physician usually demonstrated the fact that mechanical obstructions were present, the patient was allowed to attempt the use of the dilator himself, or the technic of its use was not fully understood. In the author's experience, one case which had existed for five and one-half years was cured after three treatments. Another case, of 26 years' standing, who would run two weeks without a bowel movement, required 40 treatments extending over a period of two months to effect a cure. The degree of atony will govern the

number of treatments and the length of time required for the treatment. The average number of treatments in the average case will run from ten to twenty-four.

Other diseases occurring coincidentally with constipation have to be treated according to their special indications and needs.

### OBSTIPATION

Obstipation as defined at the beginning of the chapter is a purely mechanical condition, there being some pathological condition which narrows, constricts, kinks, or obstructs the bowel in such a manner as to offer more resistance than normal peristalsis can overcome. Pressure from various abdominal organs, obstruction from coloptosis with or without intra-abdominal adhesions, torsion, or angulation of the bowel are conditions which can be remedied only by operative interference under general anesthesia, and do not come within the scope of this work. Obstipation, however, which is due to hypertrophy of the rectal valves of Houston, fecal impaction, or hypertrophied sphincters, is amenable to office treatment under local anesthesia.

**Rectal Valves.**—While for several years a great controversy was waged as to whether the rectal valves of Houston were really valves, or simply constant folds of mucous membrane, nevertheless the fact that fibrous hypertrophy of these structures does obstruct and impede the flow of the fecal current is now generally admitted. The number of cases reported of obstipation which have been relieved, only after section of hypertrophied rectal valves, is now so large that the operation of rectal valvotomy has come to be a recognized form of treatment.

Anatomical studies of the valves *in situ* and sections of the valve studied microscopically have shown conclusively that they possess all the elements of a typical valve. They are not simple folds of mucous membrane, but are composed of: first, mucous membrane; second, a fibrous tissue layer; third, a circular muscular layer; fourth, a longitudinal muscular layer; and fifth, a subserous layer consisting of areolar tissue and fat, and containing arteries, veins, nerves, and lymphatics. Under certain conditions these rectal valves become thickened and stiffened by the increased deposition of fibrous tissue, in fact, become almost leathery in consistency. They usually

encroach upon the lumen of the bowel. They may not become increased in thickness whatever, but may be simply increased in area so that they occupy from one half to three quarters or more of the



Fig. 60.—Author's four-inch operating proctoscope.




Fig. 61.—Author's rubber ligature carrier or valvotomy needle.




Fig. 62.—Author's angular rectal scissors. A very useful instrument for any cutting operation performed through the operating proctoscope.

rectal lumen. Sometimes one valve may be enlarged, and sometimes two or three. This form of enlargement presents a firm and unyielding barrier to the normal descent of the feces.

Patients with so-called constipation who have run the whole gamut

of cathartics, enemata, massage, dietetics, electricity, osteopathy, and "Christian Science" have not been relieved until they have had a proper proctologic examination and the enlarged rectal valves which were discovered reduced by valvotomy. The author has had repeatedly such cases referred to him, and the operation of valvotomy has relieved a large percentage of these cases.

The operation as performed on most of these patients was a modification of that first introduced by T. C. Martin, of Washington. It was a delicate operation, requiring considerable skill and special apparatus, but the results were all that could be desired. The objec-

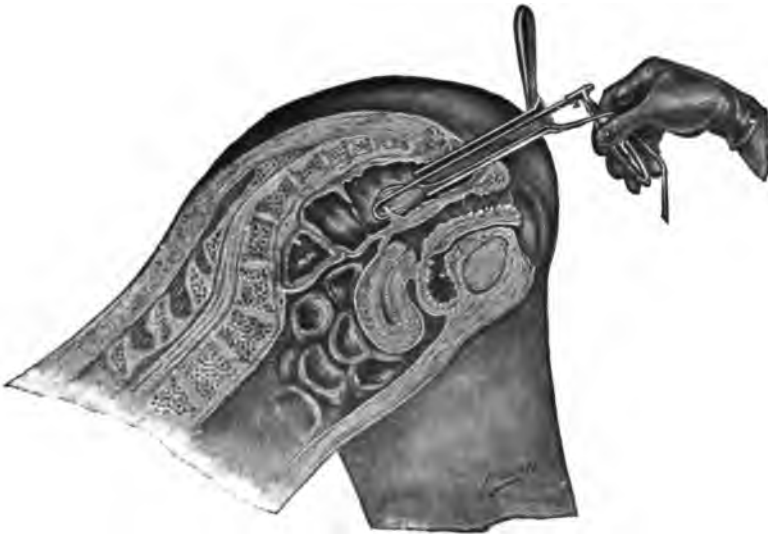

Fig. 63.—Technic of author's operation for rectal valvotomy. This drawing shows the position of the patient in the knee-shoulder position, with the author's valvotomy needle threaded with a rubber ligature transfixing the first rectal valve.

tions were: first, that without a general anesthetic patients became wearied and restless before the operation was completed; second, the fact that a general anesthetic was required for a number of cases; third, that in cases of unusually large blood-vessels in the valve considerable difficulty was experienced with hemorrhage; fourth, that the patient was confined in his house or bed or the hospital for four or five days to a week.

The Gant clamp and the Pennington clip greatly simplified the operation of valvotomy, so much so, that it could be done in a very



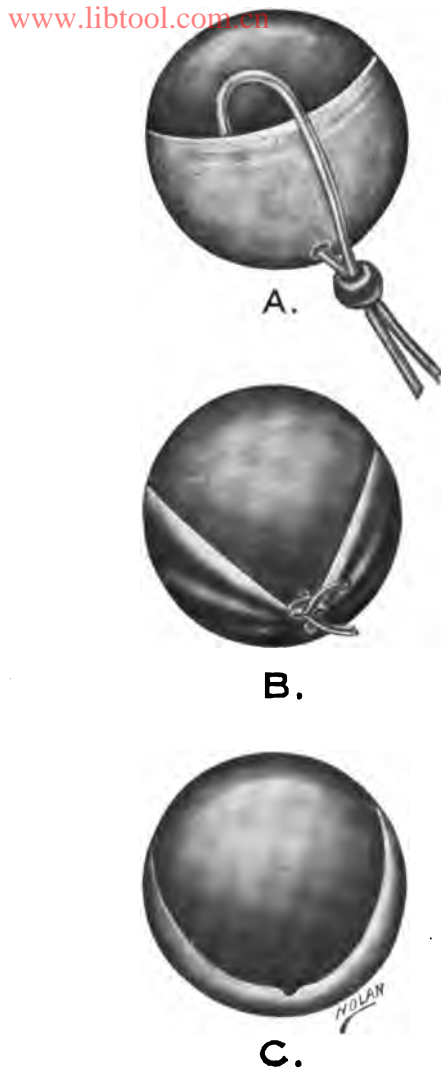


Fig. 64.—Author's rubber-ligature operation for rectal valvotomy (drawn from proctoscopic view).

- A. Rubber ligature in place with lead fastener ready for compression.  
 B. Ligature drawn taut, and lead fastener compressed, showing amount of constriction.  
 C. Result three weeks after operation.

few minutes in the physician's office without any anesthesia. The objection to the use of these mechanical contrivances was the fact of the possibility of their being carried up higher into the bowel after cutting through unless secured by a cord passing outside the anus, and worn there until the instrument was discharged, and also trauma of the rectal mucous membrane caused by the retention and passage of these irregularly shaped, hard, metallic bodies.

**Author's Operation for Rectal Valvotomy.**—The author has devised an extremely simple technic, which has proved most satisfactory in his hands, and which by reference to the accompanying illustrations can be readily understood (Figs. 60-64). The sphincter is first anesthetized and dilated, according to the technic described in Chapter XV. The patient is then placed in the knee-shoulder position, and a large operating-sized proctoscope (Fig. 60) inserted. The author's ligature carrier or valvotomy needle (Fig. 61) is threaded through the eye at the curve with a rubber ligature (sizes 5 to 8, French scale). The ligature passes inside of the curve of the needle and should project at least three inches from the point. The needle which is nine inches long and has a handle bent at an angle so as not to obstruct the view, is then passed up and around and hooked through the highest offending valve until the point is projected and the ligature can be clearly seen. This end is then grasped by means of a long alligator forceps, and the ligature is pulled through until it is outside the proctoscope. The needle is then passed back and around the edge of the valve and is brought down also outside the proctoscope, and is then taken off the ligature. The ligature is now in place (Fig. 64A). Over the ends is slipped a lead fastener or large perforated shot, the ligature being put on the extreme stretch, and the shot grasped and pushed up to the valve tightly by means of long compression forceps and crushed. This puckers the valve (Fig. 64B), and constricts it in such a way that circulation is shut off, and the ligature sloughs through in from two to eight days. After the ligature has cut through, the edges retract so that a large U-shaped opening is left, which gradually still further retracts. Fig. 64C shows the retraction in cases in which the rectal valve contains a considerable amount of fibroelastic tissue.

The advantages of this simple technic are as follows:

1. It can be done without any anesthetic whatever.

2. It can be done quickly; the whole operation should not require more than ~~ten minutes for three~~ valves.
3. It requires few instruments or appliances.
4. The patient is not confined in bed.
5. There is absolutely no hemorrhage; no stitches are required.
6. The rubber ligature, being soft and non-irritating, does not scratch or bruise the bowel *in situ* or during its expulsion, and there is no danger of its doing damage if it should by any possibility be carried up higher into the bowel.
7. It is simple.

## CHAPTER V

### FECAL IMPACTION

This consists in the formation and retention in some part of the intestinal canal of a mass of hardened feces. In 70 per cent of the cases the fecal impaction is found in the rectum, and in 20 per cent in the sigmoid flexure. The other 10 per cent are found in the upper portions of the intestinal canal, which do not come within the scope of this work, and will not be discussed.

#### CAUSES

Anything which interferes with the regularity of defecation may cause the formation of an impaction. Decubitus incident to illness or convalescence from surgical operations is a common predisposing cause. A diet which is too concentrated, such as the ordinary milk diet, is very apt to produce impaction.

Overdistention of the bowel caused by constipation may lead to the formation of a pouch or diverticulum. This pouch becomes filled with fecal matter, and on account of the atonic condition of its muscular fibers, is unable to completely empty itself during defecation. This leads to absorption of the fluid constituents of the stool and leaves behind a hardened fecal mass, whose consistency ranges from that of stiff clay to calcareous, as in enteroliths, or fecal concretions, which are composed largely of lime salts. Bits of bone, fruit and vegetable seeds, fruit stones, indigestible vegetable fiber, concretions of bismuth, salol, magnesia, or other insoluble drugs, taken internally, may become the nidus of a fecal concretion, which in turn is frequently the underlying cause of fecal impaction. Gallstones may also be responsible for their formation.

#### SYMPTOMS

The symptoms of fecal impaction are those of obstipation, coming on rather suddenly with more or less intestinal distention, accom-

panied with pain in the rectum, and extending to the left inguinal region, and frequently shooting down the left leg. The patient will complain of a frequent desire for stool, but inability to accomplish the same on account of a sense of weight and blocking-up of the rectum. If the impaction is low he may feel it impinging on the anus following the effort at expulsion. The pressure on, and irritation of, the mucous membrane, caused by the presence of this hard foreign body, starts up a hypersecretion of mucus and causes ulceration of the bowel. This causes in many instances, a diarrhea, characterized by frequent, small irritating, watery, and mucous stools, which often contain blood and frequently pus.

Cases have been reported in which the impaction has become channeled, where, after a period of almost complete obstruction, the patients have had stools apparently normal. In cases where the impaction occurs in a pouch, or diverticulum, this may also occur. In these cases, however, the feeling of weight, heaviness, and discomfort in the sigmoid or rectum is still present, and there is more or less tenesmus, and an unsatisfied feeling after stool.

In women, pressure from a large impaction on the uterus, or ovaries, may cause anterior displacement and symptoms of uterine irritation. Through direct pressure and reflexly, the bladder becomes irritable, and frequent micturition results. Patients suffering from impaction usually present, in addition to the foregoing, symptoms of autointoxication, such as dizziness, headache, coated tongue, foul breath, indigestion with or without vomiting, abdominal distention, lack of ambition, and general malaise.

### DIAGNOSIS

The diagnosis is not difficult. By rectoabdominal palpation, the round, or often nodular, mass can be made out in the lower left inguinal region, or in the rectum itself. To the examining finger in the rectum, it may be hard and nodular, or, owing to its being in a pouch or diverticulum and almost completely surrounded by mucous membrane, it may give an impression of being an extrarectal pelvic tumor.

On direct examination with the proctoscope with the patient in the knee-shoulder position, and the rectum inflated, the impaction can be easily made out. It is important in using the proctoscope

to carefully manipulate the instrument so as to see behind each rectal valve, as is not infrequently the pouching occurs in any of these locations, and the contained impaction, or concretion, is almost completely hidden from sight. If palpation discloses a mass in the sigmoid flexure, examination with the sigmoidoscope may be employed to demonstrate the impaction or concretion to the eye. It is important to determine by either ocular inspection, or examination with a sound, whether we are dealing with an impaction of clay-like consistency, or a hard concretion, as the treatments of the two are necessarily somewhat different.

### TREATMENT

The treatment of this condition consists in the prompt removal of the impacted mass. Situated in the rectum and reached by the finger, it may be easily broken up without the use of any instrument, providing it is of recent origin and its consistency not firmer than stiff clay. When it is situated beyond the reach of the finger, or if of too firm a consistency to be easily manipulated, the injection of 8 or 10 fluid ounces of liquid petrolatum, olive oil, or cottonseed oil, with the patient in the knee-shoulder position, and this allowed to remain for 12 hours, will often so soften and disintegrate the mass that it can be passed without any difficulty. In many cases this will bring the impaction down so low into the rectum that it can be broken up with the finger or a dull spoon curette used through the proctoscope, with the patient either in the lateral or lithotomy position.

The most reliable method is, however, the injection of peroxid of hydrogen in solutions varying in strength from 10 to 25 per cent. With the patient in the lateral position 2 to 4 ounces of peroxid solution are injected through a soft-rubber rectal tube inserted up to the impaction. The tube is allowed to remain in place, and at the end of 5 minutes the rectum irrigated, when it will be found that the impacted mass has been disintegrated through the mechanical action of the liberated gas and is easily washed out. Several injections of the peroxid solution may be necessary, but if persisted in, it may be relied upon to do the work. When the mass is of long-standing and so hard that it takes on the characteristics of a true concretion, it may become necessary to dilate the sphincters under

local anesthesia and to break up the mass with a short-jawed lithotribe passed ~~through an operating-sized~~ proctoscope. When the concretion is larger than  $1\frac{1}{2}$  inches in its widest circumference it is safest and best to administer nitrous oxid, dilate the sphincters, crush the concretion, and remove the mass with forceps.

After the impaction has been removed, the patient should be put on a liquid, absorbable diet for two or three days. Liquid petrolatum should be administered in doses of one or two teaspoonsful four times daily, and regular daily defecations encouraged. The atonic condition of the rectum should be overcome by the use of the author's pneumatic massage bag, as outlined in the chapter on the treatment of chronic constipation.

## CHAPTER VI

### PRURITUS ANI

Pruritus ani is the most annoying symptom, short of pain, which may accompany any disease of the rectum or anus. It is because of the intense suffering and discomfort which it causes, when present, that it has been given the prominence and importance that is accorded it of treating it as if it were a disease by itself.

. Pruritus ani, which may be an accompanying symptom of so many different diseases, in reality should not be considered alone as a disease any more than rectal pain or rectal hemorrhage. Like constipation, however, it is such an important symptom, and often the only apparent symptom of some diseased condition, that it has been thought wise to emphasize it in this chapter, and to speak of some of the conditions which most frequently cause it.

### CAUSES

Pruritus ani may be caused by or accompany every known anal or rectal disease, as well as many diseases affecting other organs or general in character. In other words, it may be caused by:

1. Any disease of the rectum or anus.
2. Any skin disease affecting the anal region.
3. As a reflex from diseases of the bladder, prostate gland, uterus, ovaries, vagina—in fact, any part of man's or woman's urogenital apparatus.
4. General or constitutional diseases.
5. Dietary disturbances.
6. Parasites.
7. Irritation from clothing, detergents, or moisture.

The discussion of the various anal and rectal diseases which present pruritus ani as a symptom will be taken up in the respective chapters devoted to those diseases. The skin diseases most commonly affecting the anal region are marginal eczema, herpes, erythema, scabies, and folliculitis.



Stone in the bladder is not infrequently accompanied by an itching of the anus and perineum. Chronic prostatitis, vesiculitis, urethritis, phimosis, and cystitis may also be accompanied by itching of this region. Any disease of the uterus or adnexa may cause itching in the region of the anus, and many times the symptom of pruritus is caused by some irritating discharge from the vagina.

Pediculi, threadworms (*Oxyuris vermicularis*), itch-mite (*Acarus scabei*), ringworm (*Trichophyton*), are the most common parasites manifesting their presence in the anal region by itching.

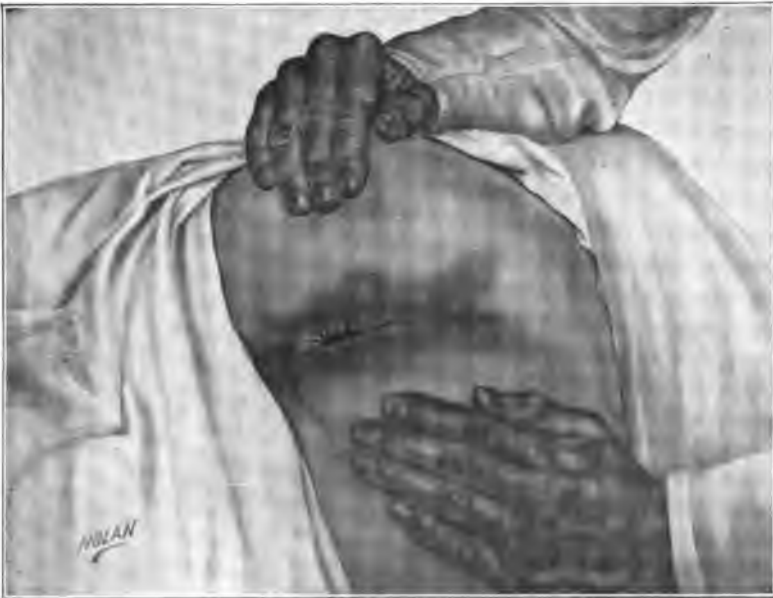

Fig. 65.—Pruritus ani. Characteristic cracking around the margin of the anus and at the posterior commissure, and the area of irritation of the apposing surfaces of the buttocks.

Among the diseases of a more general character which are frequently found to be the causes of itching at the anus are: diabetes, malaria, uric acidosis, nephritis, tuberculosis, syphilis, and hysteria. Many patients suffer from an attack of pruritus ani after partaking of alcoholic stimulants in excess. The adoption of national prohibition will soon cause this etiologic factor, at least, to disappear. In others, the excessive use of tobacco, coffee, tea, and spices also conduces to the production of this symptom. Some patients are

subject to attacks of pruritus ani only during the strawberry season, while others have an attack every time they partake of sea foods, particularly of the shellfish variety. Some patients possess an idiosyncrasy toward some one food or class of foods, and it is the indulgence in this class only which brings on an attack of pruritus ani in these particular individuals.

In many cases itching is caused by mechanical irritation of the skin surrounding the anus or by the use of coarse or harsh material

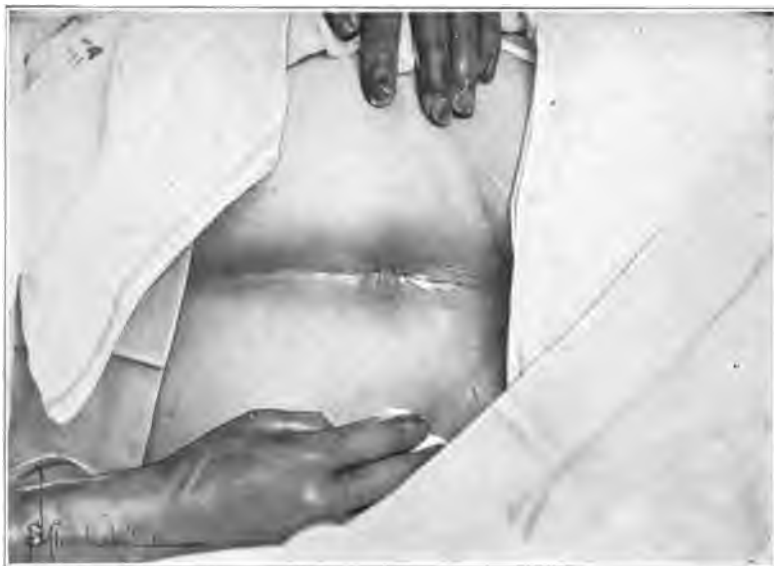

Fig. 66.—Pruritus ani, showing excoriation of anterior and posterior commissures.

in cleansing the anus after defecation. Some writers claim that the printer's ink on newspapers acts as a special irritant to the anus. The wearing of underwear colored with dyes of inferior quality, as well as the pressure of clothing which fits too snugly in the perineal region; the irritation caused by excessive sweating, particularly in stout individuals, and those who are forced to work in a high temperature, such as engineers, stokers, molders, and gas workers, are often responsible for the production of pruritus ani. Personal uncleanliness in this region is too often found to be the cause of pruritus, as in other parts of the body.

There has been a condition described by some writers as idiopathic pruritus ani, because of the presence of itching of the anus alone as the symptom, and the discovery of no other apparent cause for its existence. I do not believe that there is such a thing as idiopathic pruritus ani. I have seen cases in my practice where after the most painstaking and thorough search no cause could be found for the itching; yet I believe there was a local cause, only it was not discovered. The fact that some of these cases are cured empirically by stretching of the sphincter muscles would seem to indicate that there might be some local condition irritating the nerve-endings which was mechanically relieved by the stretching process. A perineuritis of the anal nerves is undoubtedly present, either as a primary or secondary factor in many cases of pruritus ani. Most cases of pruritus ani will be found to accompany a proctitis, which may involve a small circumscribed area or the whole proctal lining.

D. H. Murray, of Syracuse, believes that the cause of all cases of pruritus ani will be found in an infection from the *Streptococcus fecalis*, and has made extensive studies to support his views. He has reported in several communications to the American Proctologic Society a large number of cases cured by the use of autogenous vaccines made from the *Streptococcus fecalis*.

The author has verified Murray's claims as to the presence of this organism in practically every case of pruritus ani, but has been unable to secure the same success in the vaccine treatment. The therapeutic methods to be described in this and subsequent chapters have been followed by such success that they will not be abandoned until something more specific is presented.

## DIAGNOSIS

The appearance of the anus and perineum in the patient suffering from pruritus ani is quite characteristic—the skin around the anus being thrown into numerous, deep folds radiating from the anal orifice (Fig. 65). In those cases accompanied by more or less moisture, the skin is white, soggy, and more or less macerated, with, here and there, small raw areas where the skin has been denuded of epithelium by scratching. In other cases of not so long-standing, we find the skin around the anus normal in color but dry with a tendency to scale. The cutaneous folds are not so deep, but in

the sulci are found small cracks in the skin and extending up into the mucous membrane. In many cases, particularly in stout individuals, a long raw fissure or crack may be found extending along the median raphé anteriorly to the scrotum or posteriorly into the median perineal crease for a distance of from one to four or five inches. The skin surrounding the anus and these various cracks may be reddened and excoriated for a great distance from the

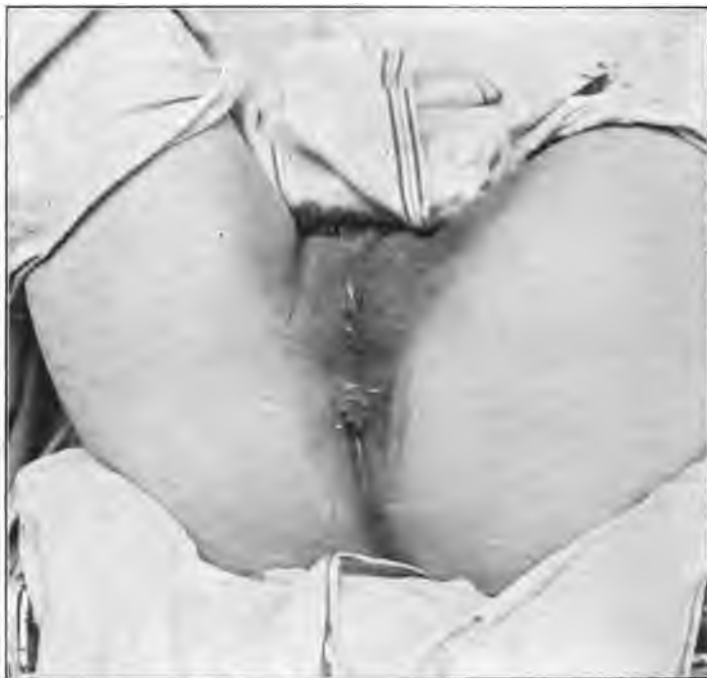

Fig. 67.—External integumentary hemorrhoids accompanied by pruritus ani. This shows the extent to which cutaneous irritation may go, in this case extending up over the sacrum and down nearly half-way to the knees.

lesion (Fig. 66). It may extend some distance up on the abdomen or down the thighs (Fig. 67) and legs to the knees. In cases of long-standing the skin surrounding the anus loses its elasticity and becomes hard, thick, and leathery. This condition is in reality due more to the scratching, rubbing and infection by the patient in his futile efforts to relieve the condition than to any pathological condition brought about by the itching itself.

Pruritus ani may mean anything from a slight feeling of uneasiness or irritation in the anal region to an intense burning, almost crazing, itching characteristic of the most aggravated types. There are several things characteristic about this itching:

1. It is usually more intense at night.
2. It tends to become progressively worse.
3. It is not relieved by scratching.
4. In spite of the fact that the sufferer soon realizes that the scratching or rubbing only aggravates the condition, he persistently and constantly continues to scratch.

While every disease affecting the rectum or anus may be responsible for the production of pruritus ani, those that most commonly cause it are fissure of the anus, ulcer, particularly of the anal canal, anal fistula, either complete, incomplete, or burrowing, hypertrophied papillæ, diseased crypts, and proctitis. The reader is referred to the respective chapters describing these conditions with their diagnosis and treatment. The presence of the *Streptococcus fecalis* in every case must be taken into consideration, but, in the majority of cases, as an agent of secondary infection.

Every case of pruritus ani demands the most careful investigation into the patient's habits, occupation, and mode of living, as well as the most thorough examination of the anus, rectum, sigmoid, and adjoining organs.

Unfortunately in some few cases where pathologic conditions have been found in the anus or rectum, which were thought to be the cause of pruritus ani, their removal has not relieved the itching. In fact, on account of the healing by granulation and the resultant scar tissue, some cases have been reported in which the itching has been aggravated. It is important, therefore, to be very guarded in the prognosis and not promise a cure.

### TREATMENT

The treatment of pruritus ani is of course the treatment of the disease, whether local or general, which causes it; and the reader must use his general medical knowledge in the treatment of diseases of a constitutional nature and in the treatment of the general diseases mentioned above, as that does not come within the scope of

this work. The treatment of the symptom, itching, must be simply palliative, while the treatment of the condition which is responsible for the itching is being carried out. If due to any of the rectal or anal diseases mentioned herein, follow out the treatment as laid down in the various chapters. If due to any skin disease of the part, such as marginal eczema, consult any good work on dermatology and treat it as you would any other skin disease in any part of the body. The author has found the following ointment a most successful one in these cases:

R Pulveris calaminæ .....	3ii
Zinci oxidi .....	3i
Hydrargyri chloridi mitis.....	gr. xv.
Phenolis .....	℥xx
Adeps lanæ hydrosi.....	3i
Misce et fiat unguentum.	

This is applied freely to parts, after cleansing and thoroughly drying, after each bowel movement and at night. In some cases where there is considerable moisture the following powder may be used instead of the ointment:

R Chlorotone .....	gr. xxx
Pulveris calaminæ.....	3ij
Zinci oxidi .....	3j
Hydrargyri chloridi mitis.....	gr. xxx
Misce et fiat pulvis.	

This is applied in the same manner as the ointment.

Herpes and erythema of the skin surrounding the anus may be relieved by the application of the compound stearate of zinc with balsam of Peru or stearate of magnesia. The parts must be protected, and the surfaces kept from rubbing against each other by absorbent cotton. Sometimes ordinary corn starch acts as a very good protective powder and certainly prevents and relieves chafing. Scabies is best treated by the ordinary sulphur ointment of the pharmacopœia. Where inflammation of the hair follicles exists with the formation of pustules, they must be opened, washed with a 25 per cent solution of peroxid of hydrogen, and then dressed with a compress of any of the standard antiseptic solutions, boracic acid being used by the author. Where the *Pediculi pubis* are present, liberal applications of blue ointment or tincture

of larkspur should be used. In ringworm the *Trichophyton* may be reached by sulphur ointment. Where threadworms are present, lime-water enemata will very quickly relieve. They should be injected twice daily, using from 4 ounces to ½ pint at each sitting, and capsules containing one-half grain calcium sulphid, given three times daily before meals.

In cases where excessive indulgence in smoking, alcoholic stimulants, and articles of diet that produce or aggravate itching is responsible, it is obvious that these indulgences must be interdicted. Where the occupation or habits are at fault, changes are necessary in order to bring about the best results. The remedies or combination of remedies which are recommended for pruritus ani are many. Blackwash is recommended by many authorities as an old reliable remedy. Tuttle considered carbolic acid in ointment, or solution from 5 to 20 per cent, as the most generally applicable of all drugs for the relief of pruritus ani. He recommends this prescription:

R Phenolis .....	3ii
Acidi salicylici .....	3i
Glycerini .....	3i
Misce secundem artem.	

Sig.: Apply to the parts with camel's hair brush or cotton swab softened in hot water.

Cripps recommends:

R Phenolis .....	3ss
Unguenti hydrargyri .....	3ii
Unguenti petrolei .....	3i

Another ointment of which he speaks very highly is

R Extracti conii .....	3i
Olei ricini .....	3i
Unguenti lanolini q. s. ad.....	3i

Cripps recommends a lotion containing two grains of bichlorid of mercury to the ounce of lime water as an application after thoroughly washing the parts with soap and water.

Gant recommends as a hard ointment the following:

R Phenolis .....	gr. xx
Mentholis .....	gr. x
Camphora .....	gr. x
Sevi .....	3i
Misce.	

Sig.: Apply freely two or three times daily after cleansing the parts.

In the preparation of the above he advises to melt the suet and when ~~partly cooled to~~ add the other ingredients. He especially cautions against adding oil, as the ointment should be quite hard, the object being to form a coating over the parts which will not be penetrated by the secretions. Citrine ointment (*unguentum hydrargyri nitratis*) is highly recommended by Gant in cases where it is necessary to restore the circulation, and the indurated skin to its normal color and suppleness. Through the suggestion of Dr. L. H. Adler, Jr., Gant uses it in the following manner: After the parts have been bathed in warm water, the citrine ointment (which may have to be weakened in some cases by the addition of lard) should be spread on several thicknesses of gauze, applied, covered with oiled silk, and held in place by a snug T-bandage. This ointment should be kept on constantly, or in some cases it may be found necessary to alternate it with an ointment containing 20 grains of calomel to an ounce of petrolatum.

In the author's experience for the mere relief of itching, compresses or enemata of water as hot as can be borne have given the greatest relief in the greatest number of cases. Sometimes cold acts better than hot. An ointment containing 25 per cent of chloretone in white cold cream has proved very efficacious in the author's hands for the same purpose.

In cases presenting a fissured condition of the anus, skin, and mucous membrane, the application of 100 per cent solution of nitrate of silver will cause a desquamation of the entire surface within 24 hours. Then a 5 per cent scarlet-red ointment in vaselin is applied on alternate days. The use of a mechanical vibrator, with a cone-shaped vibratode, for five minutes at a time, using from 5,000 to 7,000 strokes a minute, and inserted as far as can be borne by the patient, will often afford much relief. Firm pressure by means of a hard-rubber rectal plug affords relief to some individuals where all other measures have failed. It must be borne in mind that, while any of the remedies mentioned herein are being used to relieve the itching, they are but palliative, and the permanent relief of the itching comes only after the diagnosis and cure of the condition which causes it. This must be diagnosed and studied for treatment; and if the condition is not amendable to non-surgical treatment or operative



treatment under local anesthesia, it is more likely a case for the proctologist than for the general practitioner, and his aid should be called in.

If the itching is caused by the discharge from rectal cancer or from the small, shallow ulcerations of the mucous membrane between the sphincters—which Wallis, of London, claims is the cause of 90 per cent of all cases of true pruritus ani—then the indicated surgical procedures should be carried out, whereupon the itching will be relieved. In all cases where the *Streptococcus fecalis*, described by Murray, is found, the administration of autogenous vaccines should be tried, along with the measures advocated above.

The writer would suggest that one should carefully read over the chapters on proctitis, constipation, anal fissure and ulcer, fistula, hemorrhoids, and hypertrophied papillæ, as well as the chapter on the examination of the patient, before attempting to treat a case presenting pruritus ani as a symptom.

In many cases the local condition seems to imperatively demand surgical treatment, and in many of these patients prompt relief is experienced after the indicated operation. The author describes below those which he can safely recommend.

**Surgical Measures.**—In those cases of pruritus ani in which the skin surrounding the anal orifice has been hypertrophied and thrown into heavy folds and the sulci between these folds fissured, eroded, and giving forth an irritating discharge, a simple surgical procedure will often give relief. The removal of these hypertrophied skin folds under local anesthesia will give very good results.

Where there are only two or three folds involved, they can all be removed at one sitting. Otherwise, the operation may have to be done at different sittings, with intervals between long enough to allow of complete healing of the ones already operated on. There is no reason why in the average case the whole operation cannot be completed at the time.

After cleansing, shaving, and sterilizing the parts, the patient is placed in either the lithotomy or lateral position. Each fold to be removed is injected from its outermost point with  $\frac{1}{2}$  per cent solution of apothecin or  $\frac{1}{8}$  to  $\frac{1}{4}$  per cent solution of eucain lactate. After allowing three to five minutes for the anesthetic to take full effect, the fold is removed by grasping its apex with

a pair of forceps and cutting it out at its base with a sharp scissors curved upon the flat, or by elliptical incisions with the scalpel. The other fold or folds are treated in like manner, and the wound surfaces allowed to fall together without suture; and they usually heal by first intention. The bowels are kept confined for two days, and then moved by the administration of a heaping teaspoonful of compound licorice powder on the evening of the second day, followed the next morning by a six-ounce oil enema. Applications of a 5% solution of silver nitrate to the wound surfaces daily will greatly hasten healing. After two or three weeks another two or three folds, preferably those situated opposite to those previously removed can be treated in a like manner, and the same technic carried out until all the redundant tissue has been removed.

Where the pruritus is most persistent at the posterior commissure of the anus, and examination at that point shows either nothing but a thickened and irritated area extending a short way into the anal canal, or shallow excoriations at the anal margin which are neither fissures nor true ulcerations, the removal of a kite-shaped flap of skin and mucosa at this point is often followed by relief from the symptoms.

The technic is as follows:

After cleansing, shaving, and sterilizing the parts, a point three quarters of an inch behind the posterior commissure is selected, and  $\frac{1}{2}$  per cent solution of apothecin,  $\frac{1}{4}$  per cent solution of eucain lactate, or  $\frac{1}{2}$  per cent solution of quinin and urea hydrochlorid, injected so as to include a triangle whose apex is the point of injection and whose base extends from one-quarter to one-half inch to either side of the posterior anal commissure. The infiltration of the anesthetic solution should extend up into the anal canal far enough to include any excoriated or irritated areas. A triangular flap of skin is dissected up by means of a sharp scalpel or sharp-pointed scissors curved on the flat—starting at the point of injection and extending to the posterior margin of the anus. The incisions then should be brought toward each other so as to meet at a point one quarter of an inch above the diseased area in the anal canal. The latter part of the operation makes a short, broad triangle, whose base is the same as the base of a longer one

on the skin surface. This leaves a denuded kite-shaped area. The skin is brought together by three or four No. 1 or 2 chromicized catgut sutures, borochloretone powder applied, and the wound protected with a gauze pad held in place by adhesive strips (Fig. 68). The care of the bowels is the same as that outlined above, and the after-treatment consists of daily cleansing of the parts and reapplication of borochloretone, or compound stearate of zinc powder. Healing will take place in from four to seven days, and the relief experienced by the patient after this procedure in selected cases is very satisfactory.

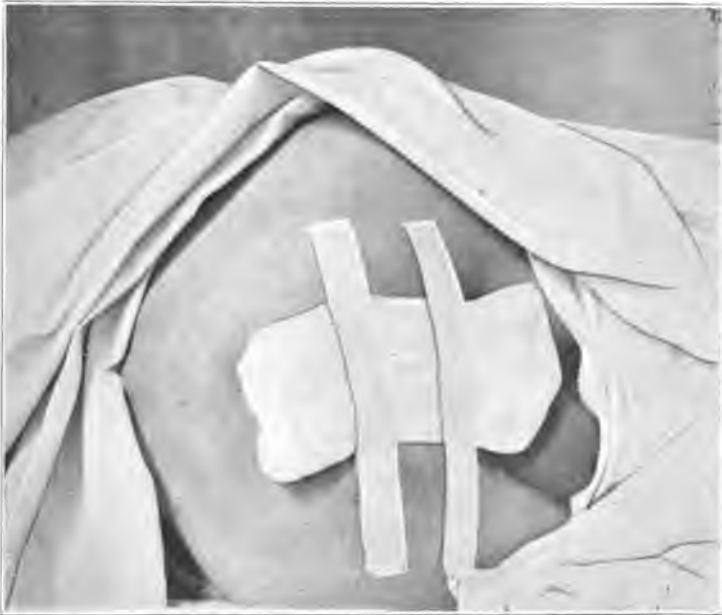

Fig. 68.—A simple and satisfactory rectal dressing, consisting of a gauze-covered cotton pad and two strips of adhesive plaster.

**BALL'S OPERATION.**—One of the most successful surgical measures available for employment under local anesthesia, for the relief of persistent pruritus ani, is the ingenious operation devised by Sir Charles Ball, of Dublin.

As described in Ball's work on "The Rectum," its employment is advocated under general anesthesia. The author, however, has been able to perform an improved modification of the operation

with brilliant results by the employment of local anesthesia. The object of the operation is for the purpose of dividing all the sensory nerve-twigs supplying the skin of the anus, anal canal, and circumanal region, which arise from branches of the third and fourth sacral nerves, come down to the levator ani muscle, and reach the skin by perforating the external sphincter.

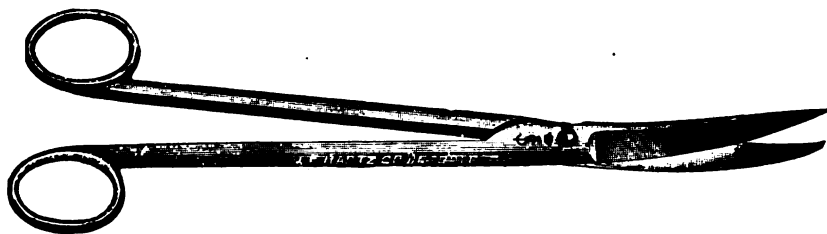


Fig. 69.—Sharp-pointed scissors curved on the flat.

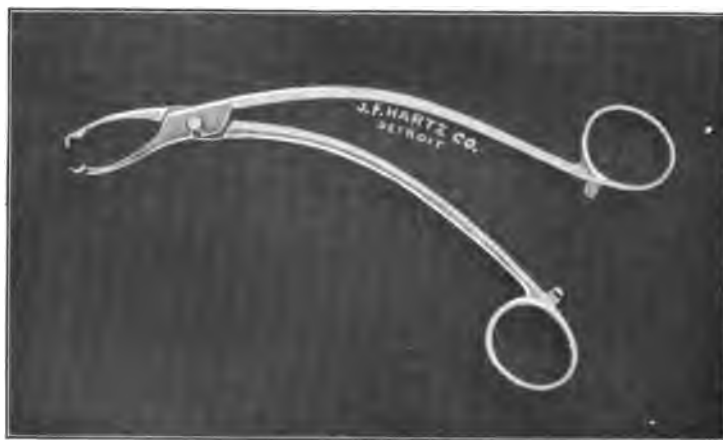


Fig. 70.—T-forceps.

Sometimes a small submucous or submuco-cutaneous fistula (Fig. 99-4) leading from a Morgagnian crypt will be found to be the cause of a localized pruritus. If so, it should be removed according to the technic outlined in Chapter IX.

The technic as employed by the author is as follows:

The patient is given a hypodermic injection of  $\frac{1}{4}$  grain of morphin and  $\frac{1}{150}$  grain of hyoscin and is placed in the left lateral or Sims position, and the area surrounding the anus cleansed, shaved, and sterilized.

An ounce of  $\frac{1}{8}$  per cent solution of beta-eucain lactate, or  $\frac{1}{2}$  per cent solution of apothecin, or the same quantity of  $\frac{1}{2}$  per cent solution of quinin and urea hydrochlorid, should be prepared and in readiness. Ten or twelve sharp-pointed curved needles, each threaded with No. 2 chromicized catgut; a couple of sharp, small-bladed scalpels; sharp-pointed scissors curved on the flat (Fig. 69); two pairs Pennington triangular (Fig. 109) or of T-forceps (Fig. 70), and two or three hemostats; and the syringe for




Fig. 71.—Ball's operation for pruritus ani. Elliptical lines of incision on either side of the anus.

injecting the solution are all the instruments required. Selecting the point about one-half inch behind the posterior extremity of the lines of incision in Fig. 71, the skin and subcutaneous tissue are infiltrated. From this point the area, included inside the lines in Fig. 71 and for one-half inch beyond, is distended until complete anesthesia is secured up to the anorectal juncture. The

presence or absence of skin sensibility to pain should be tested before starting to operate. The incisions, as outlined in the above illustration, are then made with a sharp knife down through the skin to the subcutaneous tissue. The area included between the lines of incision should be of elliptical shape, and about twice as long in the antero-posterior direction as it is broad in the lateral, with the anal canal as its center. With the patient in the left lateral position, the incision on the left side is made first, the inner flap of skin is grasped with triangular or T-forceps, and by rapid

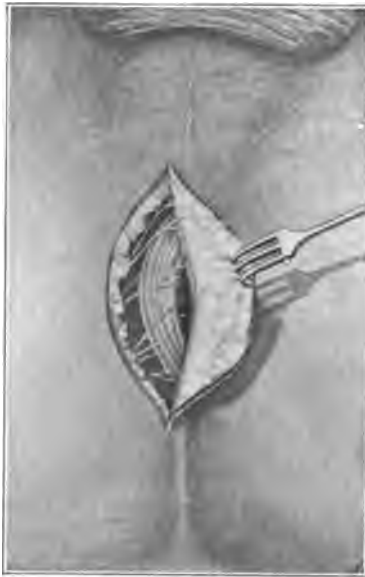

Fig. 72.—Ball's operation for inveterate pruritus ani. Method of dissecting the flaps and of dividing the terminal cutaneous nerve-twigs, which, for the purpose of clearness, are somewhat exaggerated in the drawing.—After Ball.

and careful dissection with the scalpel is raised from the surface of the external sphincter muscle and freed up to the anorectal juncture. The anterior and posterior pedicles between the ends of the incisions are freed from the subcutaneous tissues as well. In other words, all connections between the funnel-shaped cutaneous and mucocutaneous covering of the anus and anal canal are freed entirely from their underlying tissues (Fig. 72). Ball advocates the use of the scissors for this work, but the author has found he

can work much more rapidly and with more assurance of dividing all the sensory nerve-twigs by the use of a sharp scalpel. All bleeding should be controlled by pressure with dry gauze, and the flaps sutured again to the surrounding skin with silkworm or No. 2 chromicized catgut. Four to six interrupted sutures are all that are necessary for each incision. Firm pressure by wedge-shaped gauze pads is brought to bear against the region operated on, and

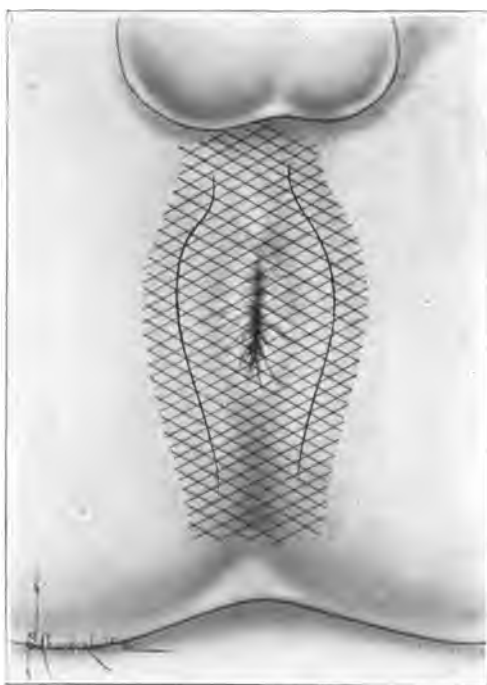


Fig. 73—Ball's operation for pruritus ani. The crossed lines show the area to which the wound is undercut, and the outside limits of anesthesia produced by the operation.

the dressings held in place by adhesive plaster and a T-bandage. This operation, by dividing all of the sensory branches supplying the area most often involved, immediately renders this region superficially anesthetic, and the pruritus is relieved at once (Fig. 73). Cutaneous sensation returns after a few months, but pruritus is permanently relieved.

Louis J. Krouse, of Cincinnati, has modified this operation by substituting six or eight radiating incisions for the elliptical ones

used by Ball (Fig. 74). His technic possesses the advantage of less possibility of interference with the circulation and vitality of the flaps, and suturing is usually not required.

**AFTER-TREATMENT.**—The after-care consists in keeping the patient on an absorbable liquid diet and keeping the bowels confined for four or five days, when they are moved by a soapsuds or oil enema. The parts are carefully washed and kept protected at all

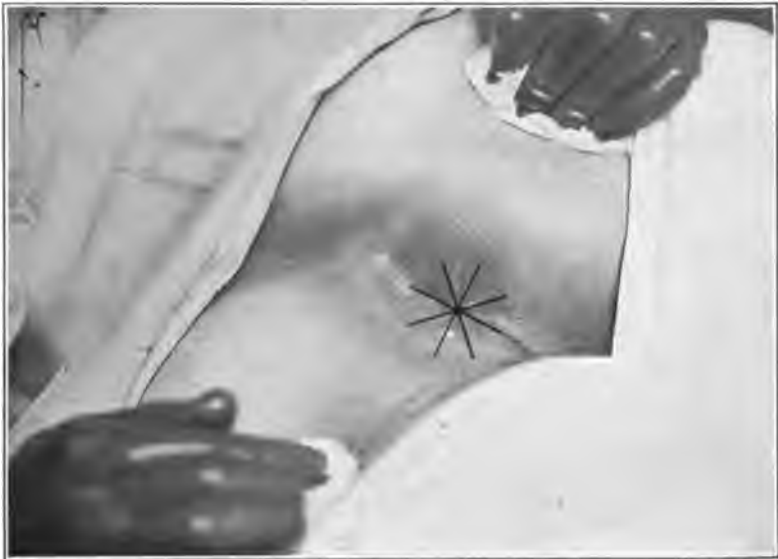

Fig. 74.—Krouse's radiating incisions for his modification of Ball's operation.

times by the liberal use of compound stearate of zinc or magnesia powder. The patient should be kept in bed for a day or two and then allowed to be up and about, but not to resume his regular occupation for five or six days. In the experience of the author, the results following this operation have been most happy, particularly in those old chronic cases where all other forms of treatment have been tried and found wanting.



## CHAPTER VII

### ANAL FISSURE AND ULCER

Anal fissure, or *fissura in ano*, is probably responsible for more acute pain, suffering, and discomfort than any other lesion of its size occurring in the human body. The fissure, as its name implies, is a crack or elongated ulceration, occurring most frequently at the posterior commissure of the anus (Figs. 75, 76, 77, 78.)

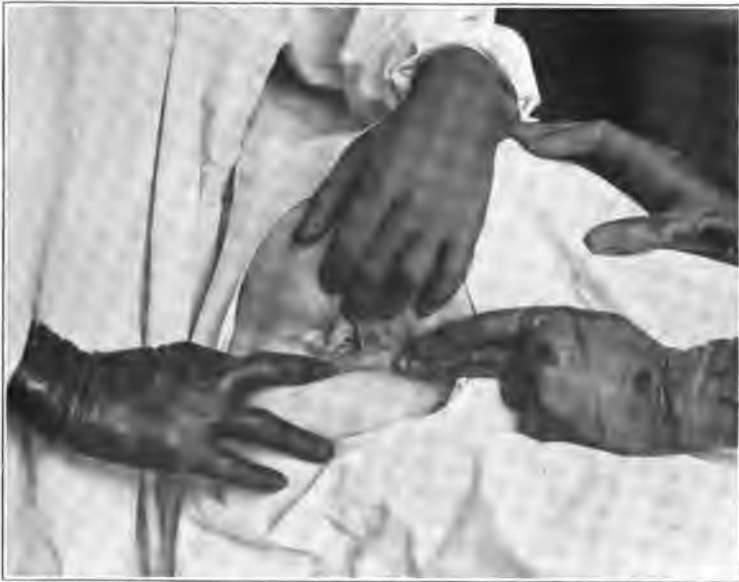

Fig. 75.—Typical site of anal fissure.

#### CAUSE

Fissures are caused by trauma. The traumatism may be produced by passing an unusually large stool, introducing or expelling a foreign body, straining, sneezing, coughing, or by faulty instrumentation. Fissures usually occur singly. When more than

one is present it is an evidence, as a general rule, of the presence of tubercular, gonorrhoeal, or syphilitic infection, or a run-down condition caused by some of the wasting diseases (Fig. 79.)

In men, in 90 per cent of the cases, the fissure will be found in the vicinity of the posterior anal commissure; in women, in about 60 per cent—the other location being in the region of the anterior commissure.

The reasons for the posterior commissure being the most frequent location for fissure are: The fact that on account of the

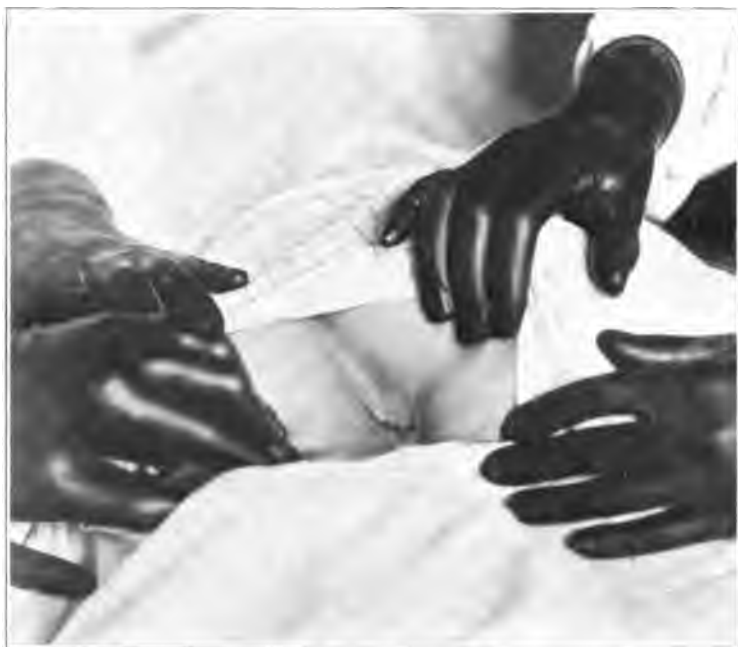

Fig. 76.--Traumatic fissure.

concavity of the sacrum the curvature of the rectal and anal canal is such that the greatest force during the expulsion of the stool is toward the posterior commissure; also, the fact must be remembered, that some of the fibers of the sphincter ani muscle run parallel to each other posteriorly (Fig. 4) to the coccyx, and this is the direction of the anal line of cleavage. Moreover, this is a constant location for one of the crypts of Morgagni, and the tear-

ing-down of a semilunar valve at this point (Fig. 80) is often the starting-point in the production of fissure.

Any inflammatory condition which will cause a moisture and softening of the anal skin will render it more liable to be injured during a movement and fissure produced. A fissure is, in reality, an infolded longitudinal ulcer. When the fissure has been in existence for some time, it tends to become chronic, the tissues sur-

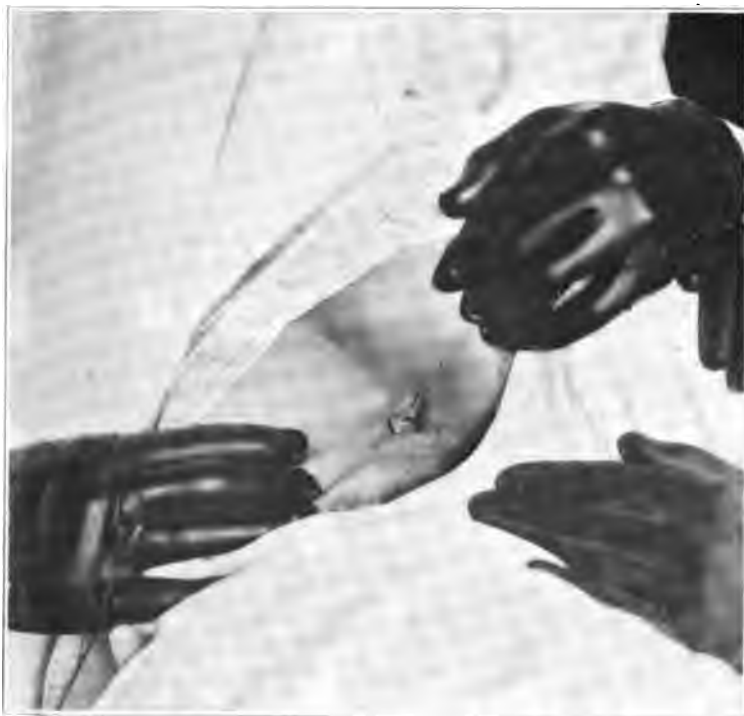

Fig. 77.--Anal fissure with sentinel pile.

rounding it become indurated, and the skin is pushed down in the form of a tag which becomes hypertrophied (Figs. 77, 78 and 80) in such a way as to form a thick crescentic fold known as the "sentinel pile." Fissures are frequently found accompanying hemorrhoids, the ulceration being located in the sulcus between two hemorrhoidal masses. Not infrequently, when the fissure is of the chronic variety, it is accompanied by a polyp, which, by

hanging down into the fissure from its upper extremity, tends to keep it irritated and prevents it from healing. One reason advanced for the fact that fissures or ulcerations in the anal canal tend to become chronic rather than to heal is the fact that the anal canal is lined by a layer of thin transitional epithelium, which is neither mucous membrane nor skin, and is poorly supplied with blood. This fact, and the action of the sphincters, keeping the parts in motion, tend to prevent good healing.

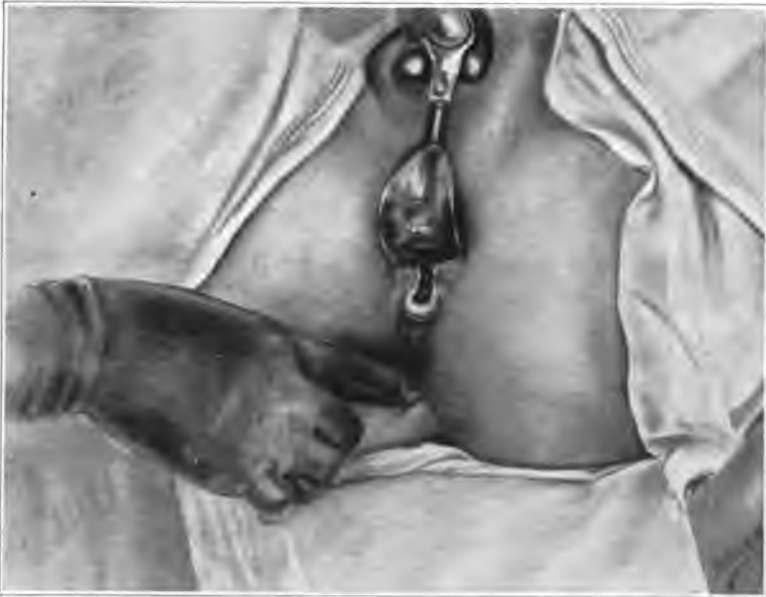

Fig. 78.—An aggravated case of anal fissure, showing sentinel pile.

### DIAGNOSIS

The diagnosis of fissure is comparatively easy. A patient, presenting himself with a history of sharp, cutting, often excruciating pain, accompanying the passage of a hard stool, and the appearance of hemorrhage, usually slight, following the passage, is in itself almost pathognomonic of a fissure. Added to this, the history of pain, usually very severe, as well as the appearance of blood with each succeeding stool, is corroborative. When the patient also complains of a beating, throbbing pain, lasting from half an hour to

several hours following the passage, and painful spasmodic contractions of the anal sphincter, or pruritus ani, the diagnosis of anal fissure is without an examination almost conclusive. However, one can never take the diagnosis of any condition in the anal or rectal region for granted, without making a thorough examination. Therefore, after obtaining such a history, the patient should be placed on the table in the lateral position for examination.

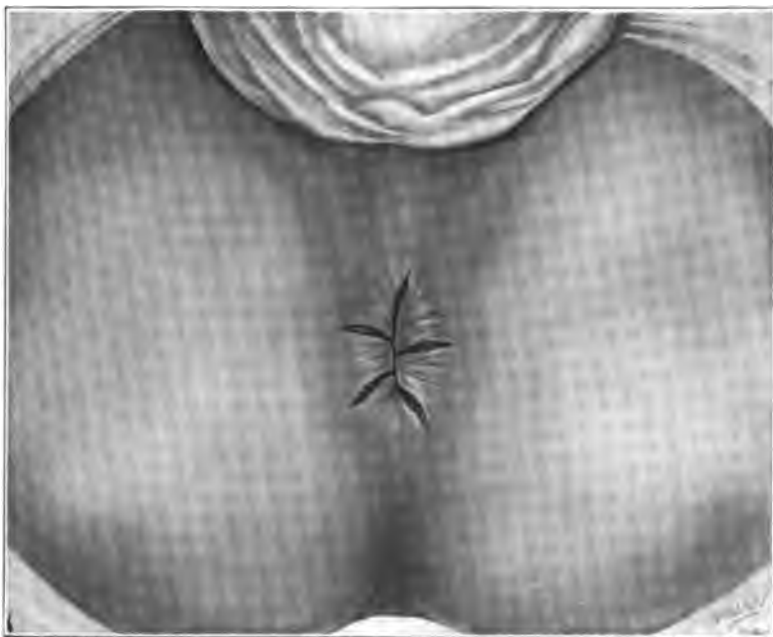


Fig. 79.—Multiple anal fissure.

Upon separating the buttocks, the first thing that will usually attract attention, except in acute cases, is the presence of a sentinel pile. This gives a clue at once to the location of the fissure, which will be found, as above stated, just at either side of or at the posterior anal commissure. Inasmuch as the entire sphincter is inflamed, hypertrophied, and exquisitely sensitive to the touch, it may be necessary, before a satisfactory examination can be made, to anesthetize the parts.

However, if by gentle traction on the skin, just below the sentinel

pile, an abrasion is disclosed, extending upward into the anal canal, the diagnosis of fissure is confirmed. If this procedure causes the patient much suffering, it had better be abandoned until the sphincter has been anesthetized according to the technic outlined in Chapter XV.

In cases which have existed for some time, the fissure, instead of presenting a red angry appearance, may be covered with a grayish or yellowish exudate. The reason that a fissure or ulcera-

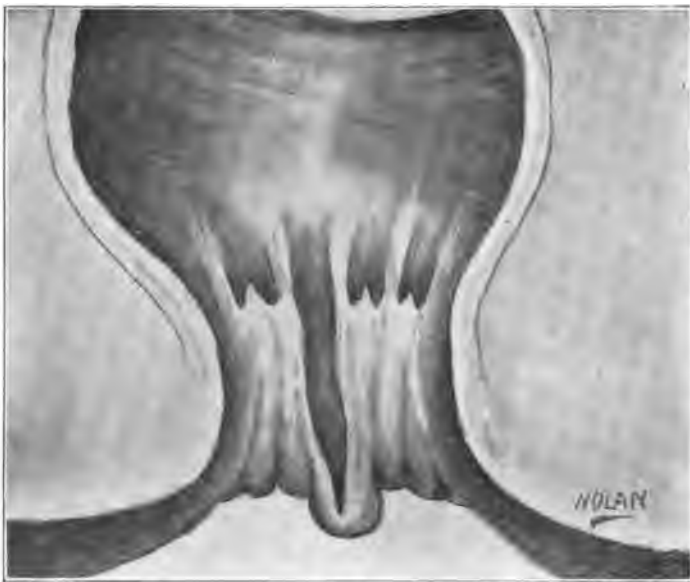


Fig 80.—Anal fissure resulting from the tearing-down of one of the crypts of Morgagni, with the formation of a sentinel pile.

tion of this region is so exquisitely tender is because of the exposure of some of the numerous nerve-endings with which this area is so generously supplied. The only other condition with which fissure is liable to be confounded is hemorrhoids, and that only from the patient's standpoint. Not infrequently, practitioners have been led into the error of taking the patient's word for the fact that he was suffering from hemorrhoids, because of the symptoms of pain at stool and hemorrhage; therefore the author would reiterate, at the risk of becoming tiresome, that a rectal

examination must be made in every case, when the exact diagnosis can be easily made.

### TREATMENT

The treatment of anal fissure resolves itself into palliative and operative. Some cases of fissure of recent origin are entirely amenable to non-surgical treatment. The first thing to do is to relieve constipation, which is done by putting the patient on a suitable diet, excluding all articles which leave much residue and cause bulky stools. The administration of white petroleum oil, suitably flavored, in doses of from one-half to one ounce daily,

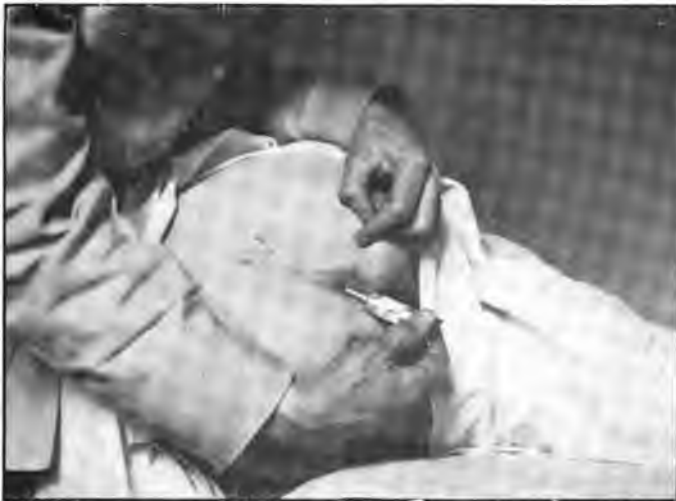

Fig. 81.—Method of applying ointment to the anus from a long-nozzled collapsible lead tube.

will soften the stools to such an extent as to make them easy of expulsion, though not liquid and irritating.

Where the fissure is shallow, and is not accompanied by the formation of a sentinel pile, the application of a swab moistened in 2 per cent eucain solution, for four or five minutes, followed by the application of pure ichthyol to the surface of the fissure, is very efficacious. This is repeated every second day. In the meantime the patient is instructed to carefully cleanse the parts after bowel movements and to apply, by means of a long-nozzled ointment tube (Fig. 81), the following:

℞ Chlorctone .....	gr. xxx
Thymolis vididi .....	gr. xx
Ichthyoli .....	gr. xxx
Adeps lanæ hydrosi q. s. ad.....	℥ss
Misc et fiat unguentum.	

Occasionally, where the fissure is very superficial and consists merely of a crack in the mucous membrane, a single application

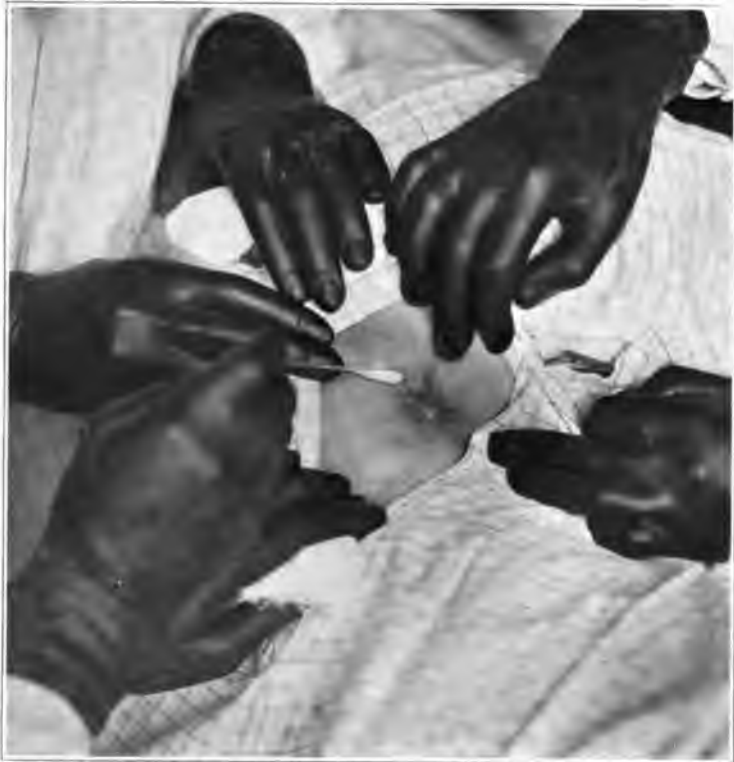

Fig. 82.--Application of carbolic acid at point of puncture.

of a saturated solution of nitrate of silver will be sufficient. This acts by causing a protective covering of albuminate of silver to be formed and effects the cure. Proper attention to the condition of the bowels, cleanliness, and the application of stearate of zinc powder are all the after-care that is required.

The daily applications of mild solutions of nitrate of silver,



alum, copper sulphate, or the use of the caustic stick are not to be advised, because they only keep up the irritation and destroy the new granulation tissue as fast as it is formed. The stronger solution of silver nitrate, as mentioned above, by its sudden coagulation of the albumin of the tissues when it comes in contact with the wound, causes the formation of an impermeable protective covering for the granulating surface beneath, and moreover, is far less painful than the milder solutions. The application of 5 per cent scarlet-red ointment every third day is an excellent stimulant to the formation of new epithelium. Suppositories for the relief

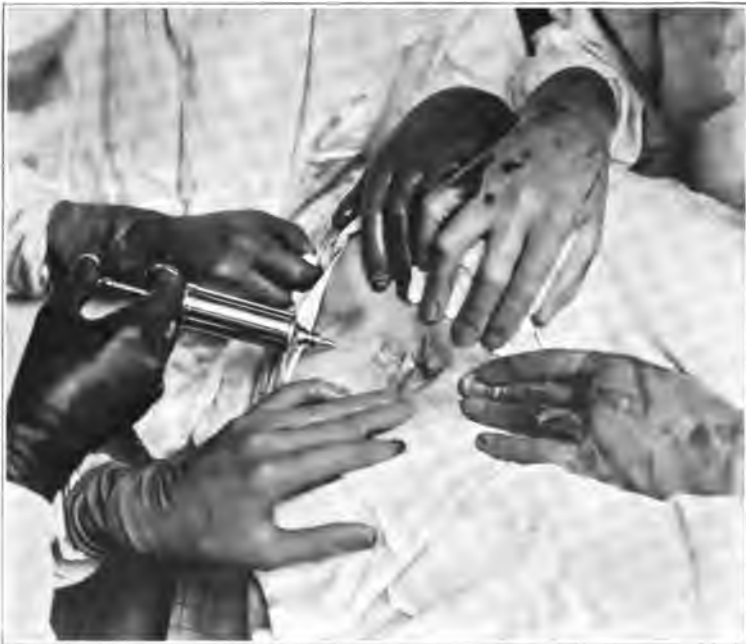

Fig. 83.—Injection of anesthetic for excision or fissurectomy at usual site.

of fissure do not appeal to the author; inasmuch as fissure is always found in the *anal canal* and the action of a suppository is exerted only in the lower *rectal cavity*, he fails to see where any direct relief can be obtained from suppositories in this condition. Moreover, it is doubtful whether an ointment applied with the finger is of any value, for it certainly cannot be applied high enough

to reach any but the most dependent portion of the fissure; yet it is astonishing how often the patient suffering with fissure is dismissed with a prescription for an ointment.

**Surgical Treatment.**—The best, surest, and quickest treatment for anal fissure is incision or excision. The author knows of no operative procedure in the practice of proctology from which more satisfactory results are achieved than the incision or excision of an anal fissure. Under local anesthesia, this is very easily and

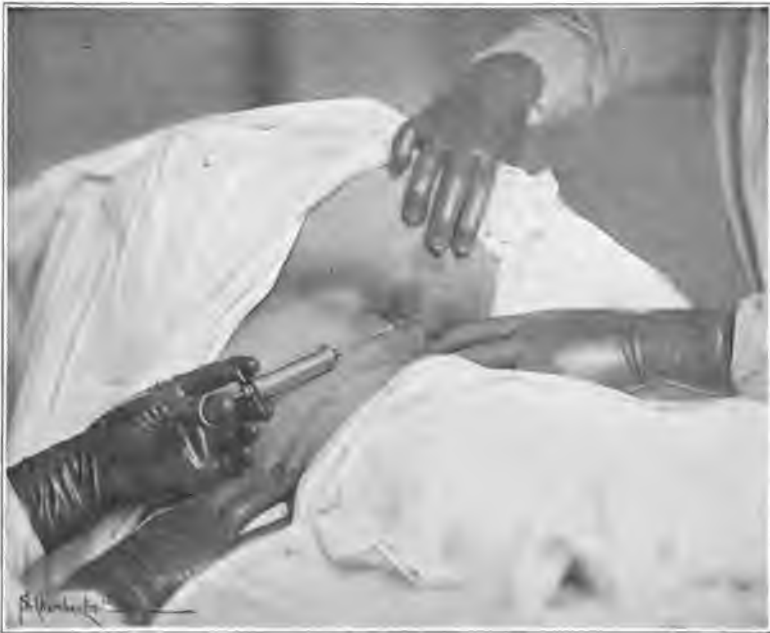

Fig. 84.—Injection of anal fissure at the base of its sentinel pile at the anterior commissure.

readily accomplished, and the results are invariably all that could be desired (Figs. 82 *et seq.*).

**INCISION.**—The technic of incision of anal fissure is as follows:

After anesthetizing the sphincter and dilating it, as outlined in the chapter on local anesthesia, a dram of  $\frac{1}{2}$  per cent solution of apothesis,  $\frac{1}{8}$  per cent solution of eucain, or  $\frac{1}{2}$  per cent solution of quinin and urea hydrochlorid, is injected below and around the fissure in such a way as to raise it up so that it is resting on a "water-bed." After waiting at least five minutes for anes-

thetia to become complete, an incision is made from the extreme upper end of the fissure down through the center and extending beyond the lower extremity for a quarter of an inch into the skin (Fig. 87). The incision should be so made that its upper or inner extremity will be the shallowest, and it should become deeper until at the lower or skin end it is from one-quarter to one-half inch in depth, slanting in such a way that the upper or shallowest part will be the first to heal and the lower the last—thus providing ex-

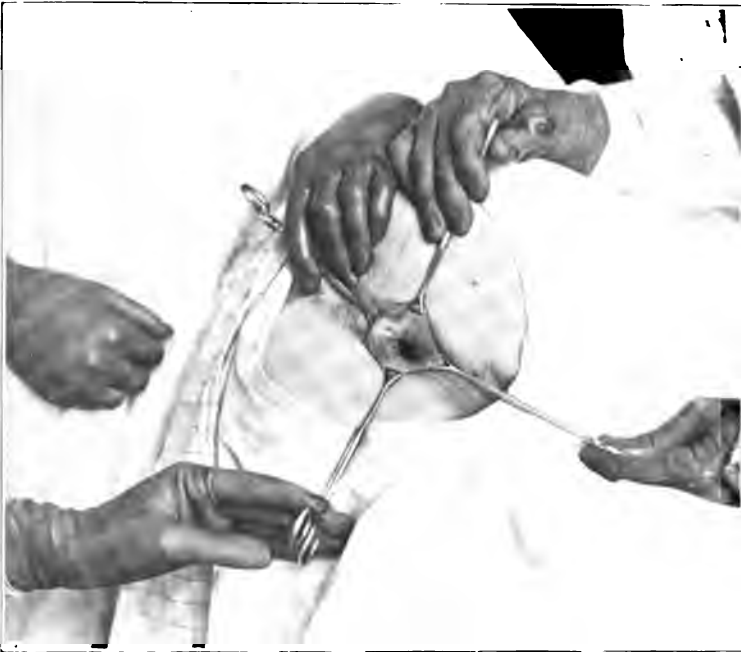


Fig. 85.—Anesthesia and sphincteric relaxation complete, giving excellent exposure for fissurectomy.

cellent drainage. The unhealthy surface should be swabbed with tincture of iodine, a suppository containing two grains each of chloretone and thymol iodid, or ten grains of quinin and urea hydrochlorid, inserted, and a single strip of plain gauze may or may not be placed in the wound.

At the end of 24 hours the gauze is removed, but the patient's bowels are not allowed to move for two or three days at least. In the meantime, he is kept on liquid diet, and the administration of

white petroleum oil is started on the evening of the second day, so that ~~the first stool will be~~ soft and unirritating. It is advisable on the evening before a stool is desired to administer a level teaspoonful of compound licorice powder, and the first thing the following morning, to inject through a small rubber catheter six or eight ounces of soapsuds or olive oil into the rectum to insure a soft and easy moment.

The after-care consists in keeping the parts clean, the bowel movements soft, and the patient up and about after the first 24

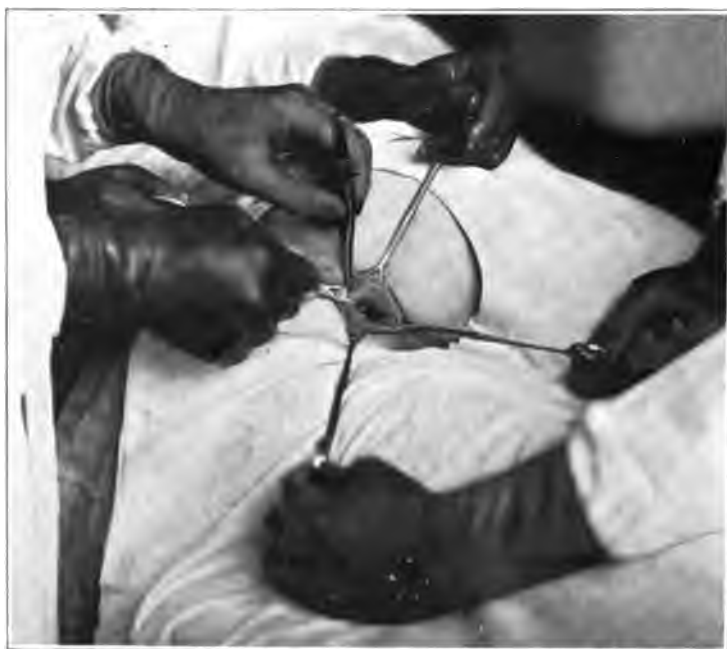

Fig. 86.—Fissure grasped ready for excision.

hours. If granulations become flabby or unhealthy in appearance, a single application of saturated solution of sulphate of copper or of nitrate of silver is usually sufficient to stimulate healthy healing. On the other hand, if the patient is in a rundown condition and the healing slow, the insertion of a one-half-inch strip of gauze soaked in bovine, twice daily, will nourish the healing tissues and bring about a speedy result. Scarlet-red ointment, 5 per cent, is also of great value in these sluggish cases.

While in many cases this procedure will be sufficient, it will not answer where the fissure is of long-standing, or if surrounded by an area of infiltration, or where there is a well-developed sentinel pile, or a polyp accompanying the fissure. Often a fissure after incision will not heal, because of the fact that the mucous membrane dips down into the wound and tends to keep its edges apart. To obviate this, and to make sure that all the diseased tissues are removed, the author *excises* instead of *incises*, when operating for chronic anal fissure.

**AUTHOR'S OPERATION.**—With the patient prepared and anesthetized as for the incision operation (with the exception that

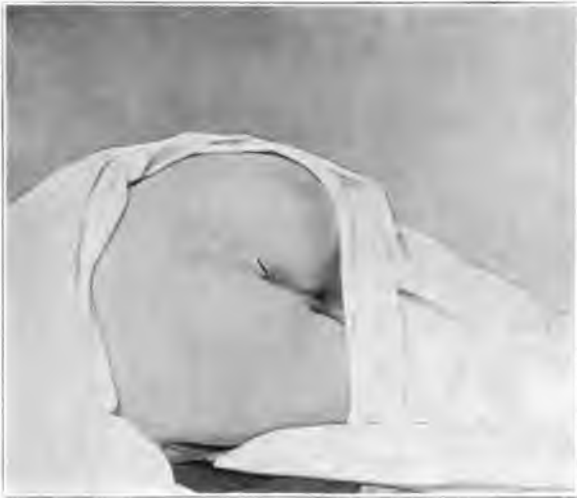

Fig. 87. Simple incision of fissure in right posterior lateral quadrant of anus.

the area of infiltration anesthesia is made more extensive so as to include all the induration surrounding the fissure), he proceeds as follows:

The fissure is grasped at its upper extremity with sharp-toothed forceps (Fig. 88), and two longitudinal incisions are made, one on either side of the fissure, starting from one-eighth to one-fourth inch to either side of its upper or inner extremity, and being made in such a manner that they meet underneath the fissure in its median line, forming a V-shaped trench (Fig. 90), which is one eighth of an inch deep at its upper extremity and



Fig. 88.—Sharp-toothed or pronged forceps. This is a very useful instrument in many anorectal operations, and while originally designed as a tonsil forceps, is of great value in proctologic work.

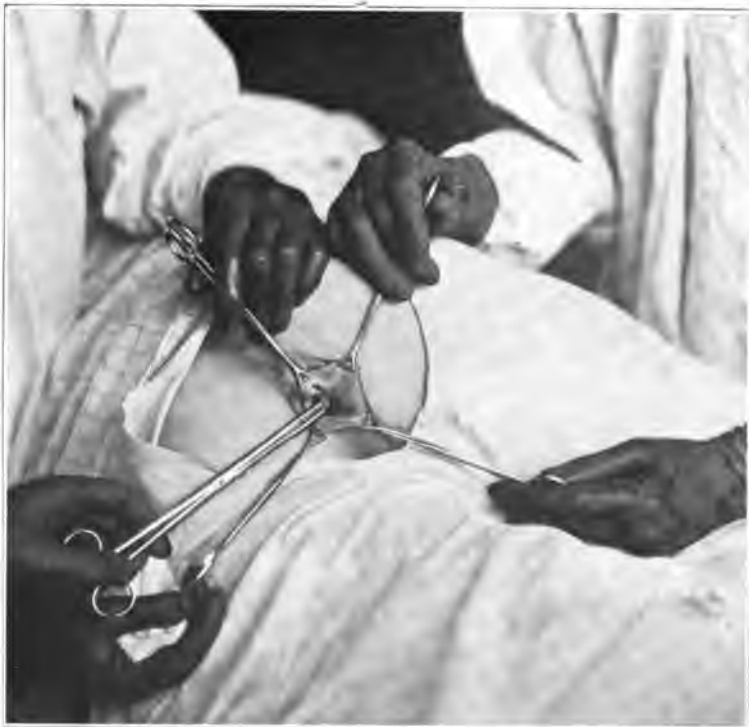

Fig. 89.—Anal fissure complicating internal hemorrhoids.

one fourth of an inch wide; and at the outer or skin portion its width is from one half to three fourths of an inch and its depth

from one-fourth to one-half inch. This disposes of the entire fissure, with its indurated edges, and the sentinel pile as well. It also allows the fissure to heal quickest at the bottom and prevents any overgrowth of the mucous membrane or dipping-down of the edges. If a polyp is situated at the upper extremity, the incisions are carried up to include it; and as the fissure is dissected up from below, a ligature is thrown around the base of the polyp, tied, and the fissure and polyp cut away *en masse*. The after-

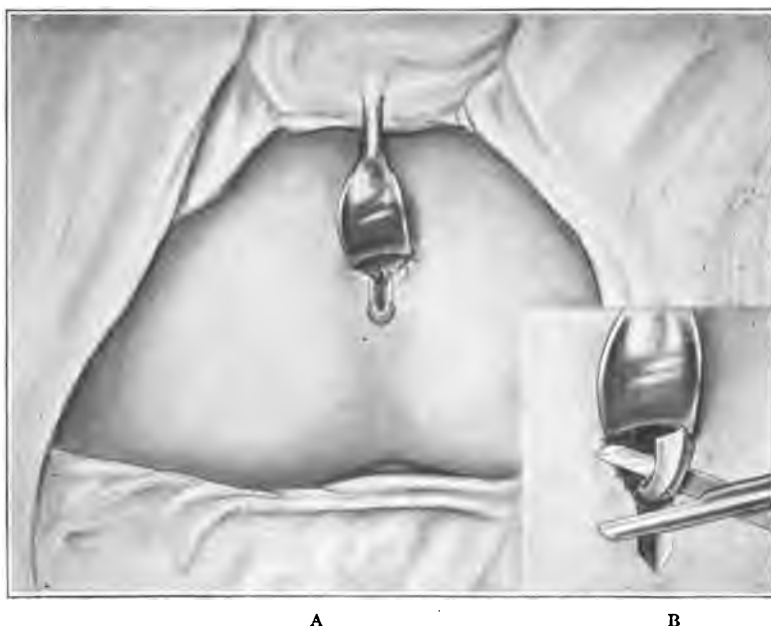

Fig. 90.—Author's technic for the excision of chronic anal fissure.

A. The dotted lines show the line of incision both on skin surface and mucous membrane.  
 B. Showing V-shaped bed left after removal of the flap containing the fissure; the dotted lines show the shape and the direction of the incision inside of the anus.

treatment is the same as outlined for the incision operation. This operation, in the hands of the author, has been so satisfactory that it is his routine treatment for all chronic and many extensive acute fissures not amenable to non-surgical treatment. Occasionally in both acute and chronic fissures of a mild type, the simple removal of the sentinel pile has sufficed to effect a cure.

### ANAL ULCER

Whatever has been said of anal fissure in regard to treatment by non-surgical measures is equally applicable to anal ulcer, the only distinction between the two conditions being a question of the shape of the ulceration—the fissure being elongated, while the other ulcers of the anus are round or irregular in outline. In ulcers which do not respond to the applications advocated for fissure, the injection of a few drops of  $\frac{1}{10}$  per cent eucain solu-

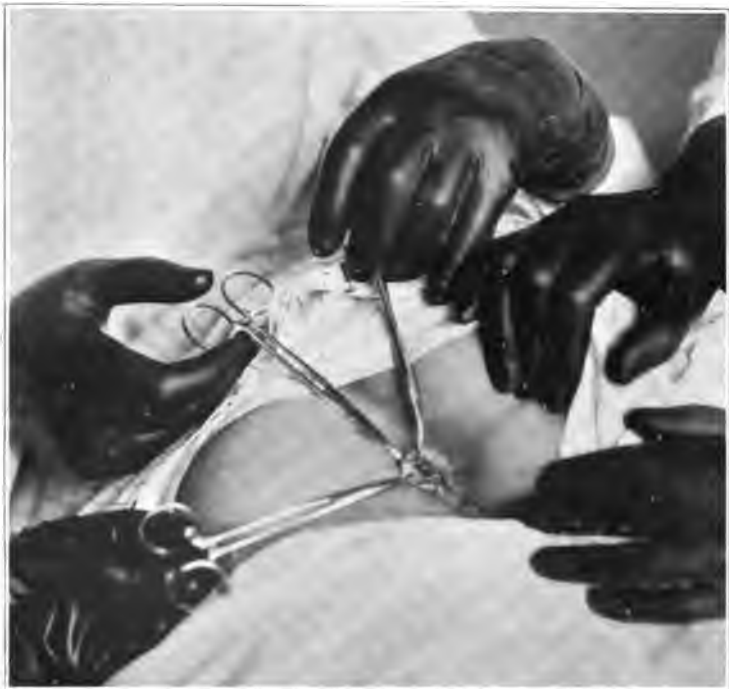

Fig. 91.—Posterior anal ulcer.

tion, or 1 per cent of quinin and urea hydrochlorid, under the ulcer is advisable, and a light curetting of its surface will often be followed by marked relief. Where the ulcer is of long-standing, the excision of the indurated tissues surrounding, as well as the ulcer itself, should be accomplished, following the same technic as outlined for the excision of fissure, varying the direc-



tion of the incisions to correspond to the shape of the ulcer (Figs. 91-92.)

The after-treatment following excision of an anal ulcer is exactly the same as that, outlined above, following fissure. It is the watchful after-care of the conscientious physician, following many of these minor anal operations, which is responsible for the good

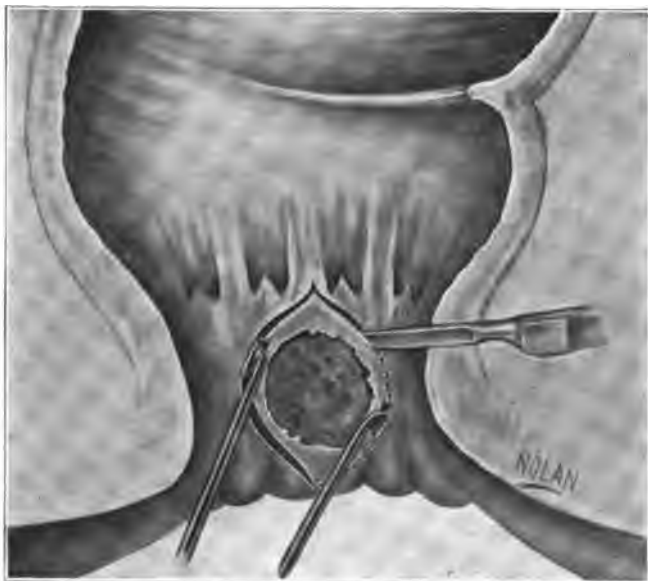

Fig. 92. Operation for excision of anal ulcer. Note the manner in which the incisions are brought to a point at upper and lower extremities of wound.

results—for often a well-executed operation is nullified in its results by neglectful, slovenly, or misdirected after-care. Oftentimes the after-care of patients following these operations is overdone rather than the reverse, and meddling interference accomplishes more harm than the operation does good.

## CHAPTER VIII

### ABSCESS OF THE ANORECTAL REGION

The region of the anus and rectum is peculiarly prone to infection and abscess formation, for several reasons: The unusual amount of cellular tissues surrounding the rectum; the lavish blood supply of this region; the constant presence in the rectum of pyogenic bacteria; the traumatism from unusually large or hard feces; foreign bodies, such as spicules of bone, fruit pits, seeds, and other articles which have been ingested. The rich lymphatic supply of this region is of great importance in the production and extension of septic inflammation. Skin diseases around the anus, particularly those which affect the hair follicles, inflammation of external hemorrhoids, the irritation from clothing or harsh detergents, disease of the crypts of Morgagni, rectal ulceration and anal fissure—all may form the starting-point for the formation of an abscess in this region.

Septic infections of the anorectal region have been divided into different classes by different authors. Tuttle classifies them as follows:

Circumscribed inflammations or abscesses...	Superficial.....	Subtegumentary
		Tegumentary
		Ischiorectal
	Profound.....	Retrorectal
		Superior pelvirectal
		Interstitial
Diffuse inflammations.....		Diffuse perirectal cellulitis
		Gangrenous perirectal cellulitis

Of the circumscribed inflammation or abscesses, only those which are located below the levator ani muscle are amenable to treatment under local anesthesia, and will be considered by the author

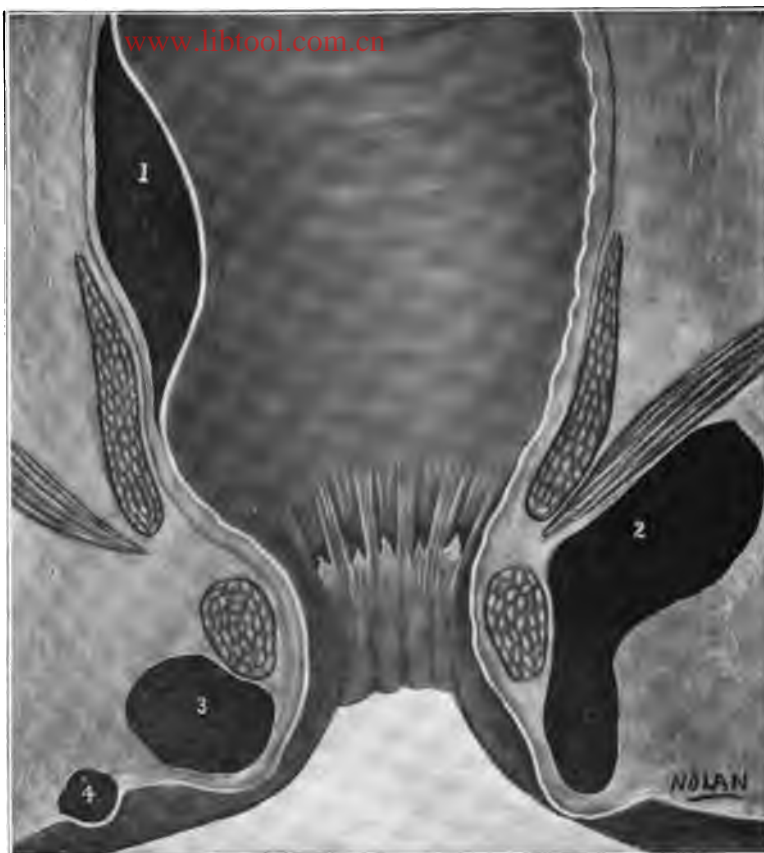

Fig. 93.--Anorectal abscesses.

1. Submucous or intermural abscess.
2. Ischiorectal abscess.
3. Marginal or subcutaneous abscess.
4. Tegumentary or cutaneous abscess.

under the head of tegumentary or perineal abscesses; perianal, marginal, or subtegumentary abscesses; submucous or intermural; and ischiorectal abscesses (Fig. 93.)

### TEGUMENTARY ABSCESS

The tegumentary, or perineal, abscesses are really nothing more than pustules, or furuncles of the skin surrounding the anal orifice, or a pustular inflammation of the hair follicles. They may be

brought about by anything which causes irritation of the parts, such as extensive perspiration, discharge from the anus or vagina, chafing

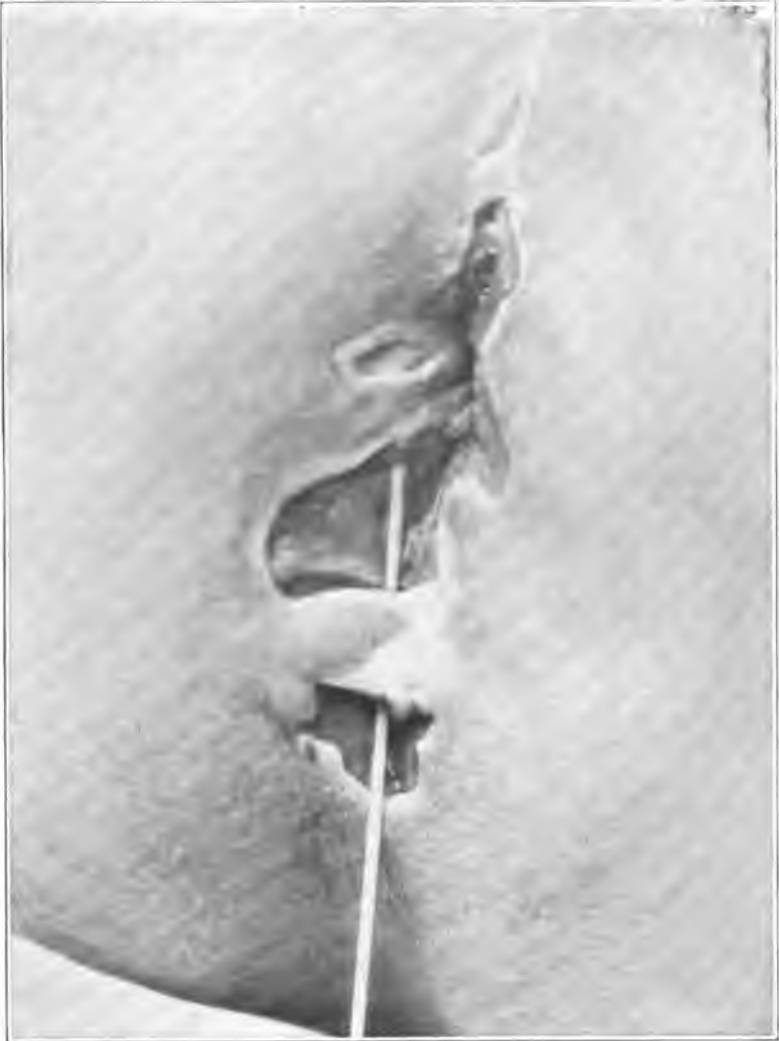

Fig. 94.—Circumanal ulceration, infective. (Note undermining due to circumanal abscesses.)

from the clothing, infection by the finger-nails in scratching, personal uncleanliness, or the use of harsh detergent materials. The

condition may range from a simple acne of the parts to the formation of ~~numbers of typical~~ furuncles or boils. These cause a slight sense of irritation, smarting or itching, and cause more discomfort when the patient is sitting or walking than any interference with the function of the bowel itself. Occasionally several of these small abscesses may run together, forming a typical carbuncle. This, however, is rather rare in this region. There is usually a slight rise of temperature, a degree or two at the outside, and more or less irritability of the patient's temper. There are no constitutional symptoms.

**Diagnosis.**—With the patient in the lateral posture, these abscesses will be seen occurring either singly or in groups as rounded reddened swellings from the size of a large pinhead to a hazel nut, with or without a point of suppuration showing in its center.

**Treatment.**—The treatment consists of spraying each abscess with ethyl chlorid and opening with a sharp bistoury. After allowing the pus to escape, the cavity is swabbed with 95 per cent carbolic acid. Daily washing of the part with warm saturated solution of boracic acid and dressing with boro-chloretone powder will usually be all that is necessary in the line of after-treatment. The parts should be washed after defecation and protected with sterile gauze, and the clothing worn loose so that there is no pressure or chafing from that source to keep up the irritation.

If there is a tendency for these little skin infections to recur, it is advisable to treat the patient with a bacterial vaccine made from the predominant germ responsible for the infection. In most cases this will be found to be the *Staphylococcus pyogenes aureus* or *albus*.

### **SUBTEGUMENTARY OR MARGINAL ABSCESS**

The most common abscess developing in the region of the anus is that which occurs deeper under the layers of the skin or lining membrane of the anus, described in the above classification as subtegumentary, also known as perianal or marginal abscess—also as subcutaneous, submucous, or intramural, depending upon the kind of tissue under which the abscess develops. While often their starting-point can be traced to a fissure or ulcer, infection of the bloodclot of a broken-down thrombotic pile, or a diseased

crypt, or the traumatism due to a bit of bone or other swallowed foreign body, nevertheless, in many cases, the point of infection cannot be determined. This leads us to the conclusion that the abscess is caused by extension through the lymphatic system, from some more or less remote injury or disease in this region. They may occur at any age, but are less common in children.



Fig. 95. —Characteristic sitting posture assumed by patients suffering from anorectal disease.

**Symptoms.**—Occasionally, abscesses which occur in this region, particularly the submucous variety, have developed to a considerable size without causing any other symptoms than a sense of uncomfortableness or fulness in the lower rectum, noticed particularly during defecation. Usually, however, the patient com-

plains first of sharp darting pains in the rectum, which are soon followed by an aching, throbbing pain which is persistent and gradually increasing. This aching extends to the sacral region, and the pain often shoots down one or both legs, even to the heel. The patient often complains of difficulty of urination. Defecation is always painful, and on account of the feeling of fulness in the rectum, is deferred by the patient as long as possible. The pulse rate increases in rapidity, and the temperature rises from one to four degrees. The patient cannot sit comfortably and rests his weight on either buttock—a characteristic posture of patients suffering from acute rectal disease (Fig. 95), which in itself is almost diagnostic.

An abscess may often develop in from 24 to 36 hours, and occasionally will rupture before the patient is really aware of the severity of the trouble. These are the cases which terminate in the formation of fistulæ.

**Examination.**—With the patient in the lateral posture, often nothing can be determined by ocular inspection unless the abscess be situated at or outside the margin of the anus, when it will appear as a rounded swelling, reddened in color, situated usually at either side of the posterior anal commissure. On digital examination, it can be definitely outlined, and its extent determined. If seen early, a definite point of fluctuation cannot be made out, but the whole abscess has a hard, doughy feel. It is extremely tender on palpation, and on account of the accompanying spasmodic contraction of the sphincter muscle, it is often very hard to examine.

**Treatment.**—The treatment of the subcutaneous or marginal variety is very satisfactorily accomplished under local anesthesia. If the abscess is situated at or below the juncture of the anus and rectum, it will not be necessary to anesthetize the sphincter muscle. With the patient in the lateral or lithotomy position, the parts are scrubbed, shaved, and sterilized, and the skin over the abscess injected with a  $\frac{1}{2}$  per cent solution of apothosin or  $\frac{1}{4}$  per cent solution of beta-eucain lactate. A point one-half inch below the abscess proper is selected for the first injection, and the injection carried upward so that a wheal or welt a quarter of an inch to half an inch wide, and extending the entire length of

the abscess, is formed. After waiting fully ten minutes for the anesthetic to take effect, an incision is made from one extreme of the abscess to the other in a direction at right angles to the anus, and the pus allowed to escape. It is then irrigated with sterile water or normal salt solution, and after breaking down any dividing walls, so as to convert the abscess into one cavity, it is swabbed out with equal parts of tincture of iodine and carbolic acid; a light gauze drain inserted, and a sterile dressing applied. When the author says *lightly inserted*, he means the gauze should be inserted *sufficiently firm to keep the wound edges well separated and yet touching against the lining of the cavity so lightly as not to interfere with its contraction during the healing process*. The patient is not allowed to arise from the table for five or ten minutes after the operation, when he is slowly assisted to his feet, and after a few minutes in a chair will be able to go on his way.

It is advisable to keep the patient on an absorbable diet for a couple of days and not allow the bowels to move during that time. The wound should be dressed daily, being irrigated with Carrel-Dakin or any of the other chlorinated solutions, the value of which was so well demonstrated during the recent World War.

In the author's experience in an army base hospital in France, it was found that the use of Carrel-Dakin's solution, dichloramine-T and flavine materially hastened healing in every case. In a fair percentage of cases, secondary suture was successfully performed.

At the end of the third or fourth day in the average case all drainage can be discarded except a strip of gauze inserted merely to keep the wound edges apart. This must be renewed daily as long as any purulent discharge persists. The best protective powder to use to keep the discharge from irritating the surrounding skin is compound stearate of zinc with balsam of Peru or magnesium stearate.

### **SUBMUCOUS ABSCESS**

The submucous or intermural variety occurs underneath the mucous membrane covering the lower rectum, and may be found at any point in the circumference of the rectum. Those located in the anterior wall are usually accompanied by disturbances of urination. In fact, oftentimes patients are unable to urinate at



all and have to be catheterized. This variety is diagnosed by digital examination—the well-lubricated finger gently inserted through the anus while the patient is asked to bear down. A rounded mass may be felt within an inch or inch and a half of the anal outlet, either of a doughy consistency or distinctly fluctuating. By gently sweeping the finger from side to side, the outlines can be

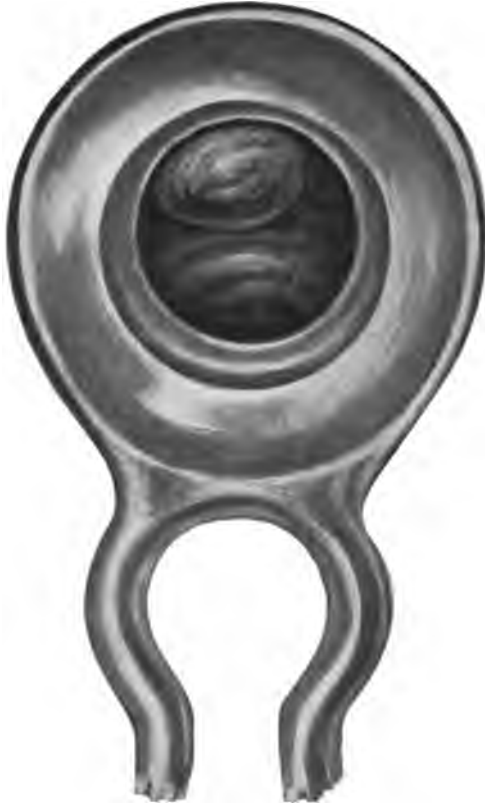

Fig. 96.—Proctoscopic view of submucous abscess of the rectum.

made out, and its extent determined. With the short anoscope, the diagnosis can be further confirmed (Fig. 96), and not infrequently the point of infection determined. Occasionally, the abscess may extend down to the integument beyond the anus, forming a submucocutaneous abscess.

**Diagnosis.**—The diagnosis, after both digital and ocular examination, is very evident. Given the symptoms of rise in temperature, rapid pulse, aching, throbbing, pain coming on more or less suddenly in the region of the anus or lower rectum and remaining, becoming more persistent and increasing in severity, with the presence of a circumscribed painful swelling, these make the diagnosis of abscess in this region conclusive.

**Treatment.**—When the abscess is of the submucous variety and situated above the internal sphincter, it will be necessary to anesthetize the sphincter, according to the technic outlined in Chapter XV. After washing out the rectum with saturated solution of boracic acid, the patient is placed in either the lithotomy position, if the abscess is situated on the anterior wall, or the

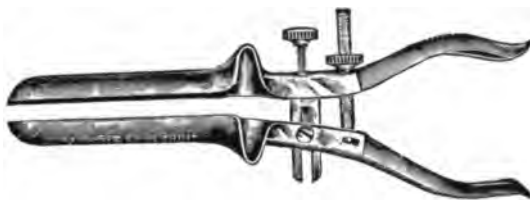

Fig. 97.—De Vilbiss rectal speculum. This instrument is useful in many anal operations, on account of the fact that its blades may be opened parallel to each other and it can be self-retaining.

lateral position, if located on the posterior or lateral wall. After the parts are washed, shaved, and sterilized and the sphincter anesthetized, it is slowly dilated, and a single Sims retractor inserted at a point opposite the abscess and held by an assistant. In the absence of an assistant, a De Vilbiss rectal speculum (Fig. 97) will answer, as it is self-retaining. The mucous membrane covering the abscess is injected with a  $\frac{1}{2}$  per cent solution of apothecin or a  $\frac{1}{8}$  per cent solution of eucain lactate, or  $\frac{1}{2}$  per cent solution of quinin and urea hydrochlorid, until the tissues are blanched over the entire abscess.

After waiting five minutes for the anesthetic to take effect, the abscess is opened by a longitudinal incision extending from its extreme upper end down well below its lower extremity. The pus is allowed to drain out, when the cavity is irrigated with normal saline solution or sterile water. All dividing walls are

broken down so that the abscess is converted into one cavity. It is then swabbed out with 95 per cent carbolic acid or equal parts of carbolic acid and iodin, and gauze lightly inserted, which should extend out through the anus. In some cases it is advisable to insert a rubber drainage tube about the size of a lead pencil, which tube should extend an inch outside the anal canal.

The after-care is similar to that advised for the subcutaneous variety, especial care being taken to see that the abscess is kept

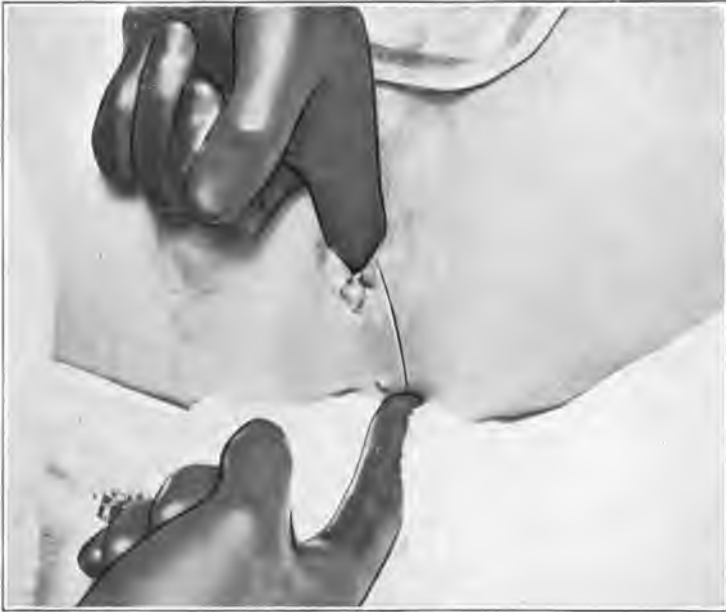

Fig. 98.—Line of incision for opening an ischiorectal abscess.

healing from the bottom, and that no ramifications form during the healing process. The patient is allowed to be up and about immediately after the operation, and is properly kept up on account of better drainage in the upright position. It is this variety of abscess which, if allowed to open without surgical interference, forms the internal sinus or blind internal fistula. It is an important thing to remember, in this form of abscess particularly, that the incision should be carried well below the lower extremity of the abscess, so as to allow good drainage.

**ISCHIORECTAL ABSCESS**

[www.libtool.com.cn](http://www.libtool.com.cn)

Ischiorectal abscesses are the most extensive variety which can be treated under local anesthesia, and not all of these, by any means, are favorable cases. The author would lay down the rule that *no abscess of the ischiorectal region whose upper extremity is over two inches from the anal skin, and whose extent, size, and location cannot be definitely outlined by bimanual palpation, should be operated unless under a general anesthetic.*

Ischiorectal abscesses start, grow, and extend with great rapidity on account of the loose cellular tissues, in which they form, offering little or no resistance to their spread. They occur at either side of the rectum, and occasionally surround it. They are caused by either the puncture of the rectal walls by spicules of bone, bristles, or other ingested foreign substances, or from diseased Morgagnian crypts or infection which is carried by the lymphatic system. They have been known to follow operations on the rectum and anus, or injury caused by faulty instrumentation in making a rectal examination.

**Symptoms.**—The constitutional symptoms are similar to those which accompany the subcutaneous or submucous abscesses, with the exception that the pain is more deeply seated, the sacral aching more severe, and the symptoms in general approaching more nearly those of a general septic infection. The patient often suffers from chills, with a high fever, severe headaches, backache, fetid breath, languor, loss of appetite, and more or less prostration. The pain localizes itself on either side of the rectum, unless there is a simultaneous infection on both sides. Defecation is so painful that the patient gives up all attempts at it and frequently also is unable to urinate. If the abscess has existed longer than 48 hours, some redness of the skin will be observed, varying in degree according to the nearness of the abscess to the integument.

**Diagnosis.**—Bimanual rectal palpation, with one finger in the rectum and the other hand pressing toward it just outside the anus (Fig. 98), will disclose a hard elongated mass, often pear-shaped, which is extremely painful, and gives the characteristic doughy or boggy feeling of an abscess. A point of fluctuation oftentimes can be made out at the lower extremity of the abscess.

The diagnosis is readily made on bimanual examination. The swelling caused by the abscess may be so great that it is practically impossible to introduce the proctoscope into the rectum.

**Treatment.**—After the rectum has been flushed with a saturated solution of boracic acid, the patient is placed in the lithotomy or lateral position, according to the location of the abscess, and the parts washed, shaved, and sterilized. The sphincter is anesthetized, according to the technic outlined in Chapter XV, and the skin over the abscess, as well as the anal lining membrane, is infiltrated with a  $\frac{1}{2}$  per cent solution of apothecin,  $\frac{1}{4}$  per cent solution of eucaïn lactate, or a  $\frac{1}{2}$  per cent solution of quinin and urea hydrochlorid. After the infiltration of the skin, the subcutaneous tissues down to the abscess are injected with the quinin-urea solution, care being taken not to penetrate the abscess cavity with the hypodermic needle. The infiltration should be carried well into the lower rectum. A single Sims retractor (Fig. 109) is inserted at a point opposite the abscess and held by an assistant, or the De Vilbiss speculum used, and opened to its fullest extent. With a sharp-pointed bistoury an incision is made from the outermost point of the abscess on the skin toward the anus, so that the incision is at right angles to the anal canal. The opening should be made wide enough so as to thoroughly drain the abscess cavity, and only if necessary, should be extended through the sphincters into the anus.

Where the abscess cavity can be well exposed by an incision which stops short of the sphincter and there are no ramifications of the cavity, it will not be necessary to enter the rectum, and the author, as a rule, would caution against making an opening in the rectum unless a communication already exists in the form of a fistula. All trabeculæ and partition walls should be broken down so that the abscess is converted into a single cavity, and it should be irrigated with saline solution or sterile water. The incision at the outermost point of the abscess cavity should be as wide or wider than the cavity itself. After irrigating the cavity sufficiently, gauze soaked in balsam of Peru should be gently inserted so as to keep its walls apart. A dressing is applied, and the patient advised to keep in the recumbent position, lying preferably on the operated side for 24 hours.

At the end of that time, the packing is removed, and about two thirds of the quantity of gauze used in the first dressing lightly inserted. At each succeeding daily dressing the amount of gauze is lessened until the abscess cavity has healed up from the bottom. If the granulations become flabby or unhealthy at any time, they should be touched with a saturated solution of copper sulphate or a 25-100 per cent solution of silver nitrate. The application of pure ichthyol every second or third day, while somewhat painful, is of extreme value in promoting good granulation.

Where it has been found necessary to carry the incision into the rectum and sever the sphincters, care should be taken to arrange the drainage in such a way as to prevent the skin or mucous membrane from growing down into the wound, and preventing the reuniting of the sphincter as the abscess cavity heals.

If this should happen, however, in spite of all precautions, anesthize the part by the application of a swab soaked in 4 or 5 per cent eucain solution for five minutes, keeping up pretty steady pressure on the parts. Then with a pair of sharp-pointed scissors, curved on the flat, trim back all redundant tissue to the surface of the skin or mucous membrane as the case may be.

In the treatment of all suppurative conditions of the anorectal region, the author would caution his readers to refrain from attempting to operate on any case in which there is the slightest doubt of his ability to complete the operation under local anesthesia. One must be sure of the size, location, and extent of the abscess, and it must be definitely outlined and definitely circumscribed in order to be amenable to treatment under local anesthesia.

## CHAPTER IX

### ANAL FISTULA—ANAL SINUS

A fistula may be described as a tubular suppurating tract, communicating with or connecting the mucous membrane of the anus or rectum, and the integument contiguous to the anal outlet.

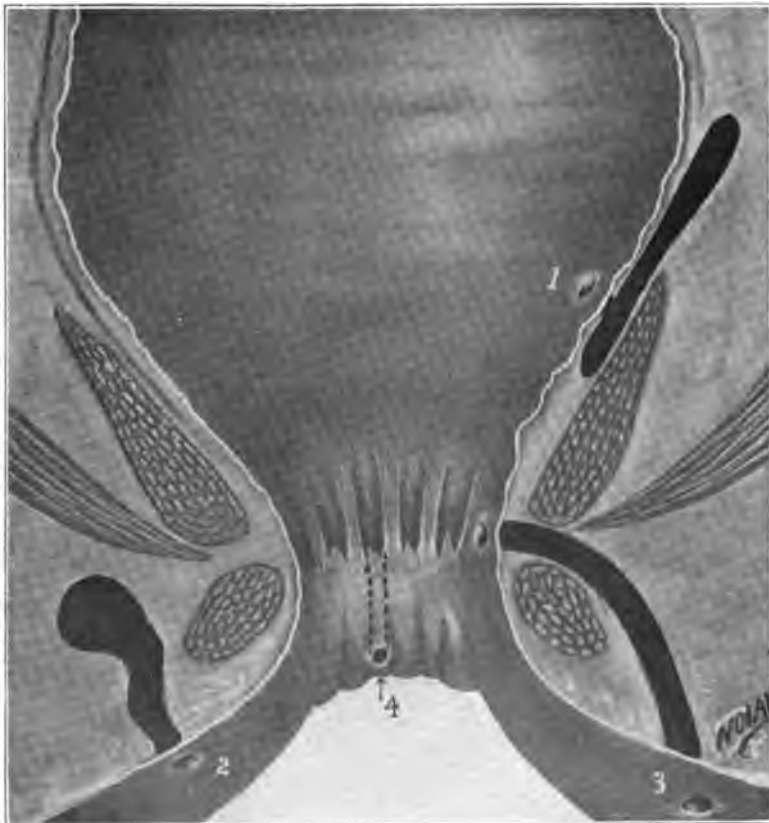


Fig. 99.—Anorectal fistulæ and sinuses.

1. Internal sinus.
2. External sinus.
3. Complete direct fistula.
4. Submucous or submucocutaneous fistula.

Fistulæ are of several different varieties, which will be described below. A fistula is the result of an abscess in the anal region, which has either been untreated and allowed to rupture, or when opened by the surgeon has, through insufficient, careless, or improper after-treatment, been allowed to contract without being made to heal from the bottom. The only exception would be a fistula caused from a punctured wound, either traumatic or surgical.

Anal fistula is often spoken of as either tubercular or non-tubercular. While the author realizes that tuberculosis is a factor to be seriously considered in the discussion of fistula, he will reserve his remarks on this particular variety of fistula until farther on in the chapter. What is said regarding fistula below, therefore, must be understood to mean the non-tubercular varieties.

The reason that an abscess degenerates into a fistula in this region, rather than to completely heal, is due to two factors peculiar to its location. The most important is the fact that, due to the natural motion of the anus and rectum in the act of expulsion of gas or feces, and the dilatation and contraction of the sphincter muscles, the parts are not allowed to remain at rest, and the surfaces are prevented from adhering to each other. Added to this is the important fact that mucus and feces enter the abscess cavity from the rectum and their constant passage tends to keep the tract open and prevent healing. A fistula, therefore, is in reality the tubular contracted remains of an abscess, and is lined by a pyogenic membrane as was its parent abscess.

### VARIETIES OF FISTULA

The variety of a fistula depends on the location and kind of abscess which preceded it. They are divided by some authors into complete and incomplete. A complete fistula is one which gives a direct communication between the bowel and the surface of the skin, somewhere in the region of the anal opening. An incomplete fistula is either one which has an opening into the bowel alone or one which opens through the integument alone. Complete fistulæ (leaving out of consideration those which communicate with other organs, such as the bladder, vagina, or urethra) are divided into horseshoe fistulæ and multiple fistulæ. The horse-



shoe fistula is characterized by its having one opening in the anal canal, usually situated between the sphincters at the posterior commissure, and surrounding the anus, communicates with the skin by two openings—one on each side of the anus. A multiple fistula is one which has one or more internal openings and numerous branching channels opening by many external openings on the skin.

The incomplete, or so-called "blind," fistula is in reality a sinus. The term "blind fistula" should, therefore, be discarded, as suggested by Pennington in favor of the more truly descriptive term "sinus." We, therefore, speak of internal sinus and external sinus, whether anal or rectal, instead of blind fistula. The internal sinus opens on the mucous membrane, while the external sinus opens on the skin.

A form of fistula known as the submucous fistula is one which has two openings, both opening on mucous membrane, and is usually found just inside the anal canal. The most common location for the internal opening of a fistula is at the posterior commissure of the anus and between the sphincter muscles. In this chapter only those varieties of fistulæ which are amenable to treatment under local anesthesia will be discussed: viz., simple complete fistula, external sinus, internal sinus, and submucous (Fig. 99).

### SIMPLE COMPLETE FISTULA

This is the commonest form of fistulæ met, and is the remains of a subcutaneous or ischiorectal abscess, and consists of a straight or slightly curved channel running from the anal canal or some point in the rectum a little higher up to the outside skin—usually opening within one or two inches of either side, and below the anal aperture. The internal opening is usually posterior, between the sphincters; it may, however, be found at any point of the anal circumference. The external opening may be at any point on the skin in the vicinity of the anus, but the points mentioned are the usual sites.

**Symptoms.**—The symptoms are a sense of irritation or an itching of the anal region, pain during defecation, and the presence of a purulent discharge. If for any reason one of the openings should become plugged up, there is some distention, and pain from pressure.

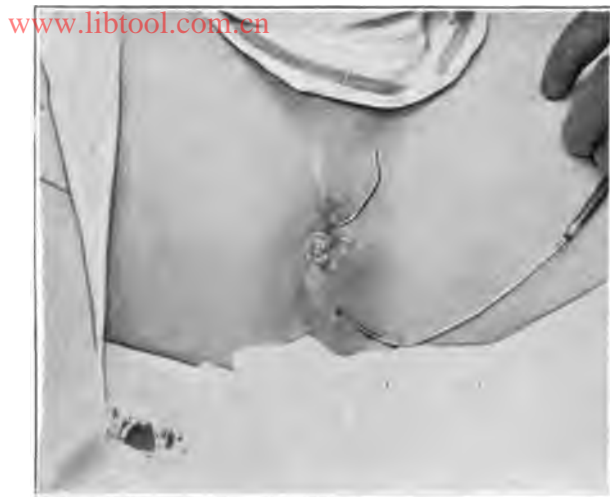

Fig. 100.—Direct complete anal fistula. The probe is seen entering the external or cutaneous opening, while directly above it its blunt-tipped extremity is seen emerging from the anus.

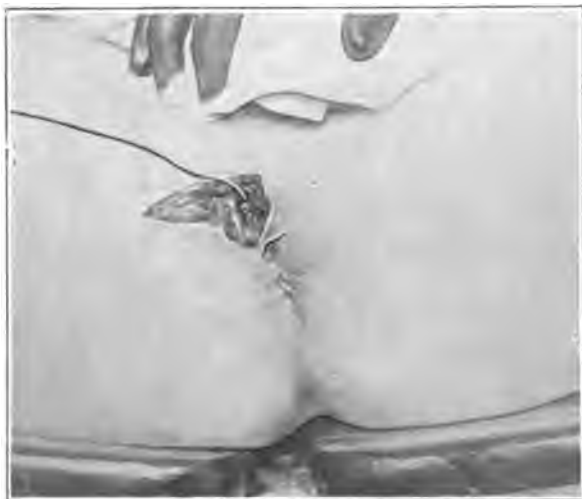


Fig. 101.—Angular fistulous tract. The upper portion of the fistula has been opened, and the probe can be seen entering the lower portion. The end of the probe can be seen emerging from the left upper quadrant of the anus.

**Diagnosis.**—The diagnosis of fistula should always be in mind when on examination of a patient a papule is seen on the perineum or buttocks, from which a drop of pus exudes or can be pressed out. This is the characteristic appearance of the external opening of a fistula. With the patient in the lateral position and the index finger of one hand over the external opening, the index finger of the other should be inserted with the palmar surface directed toward the posterior commissure. Often by the pressure with the finger in the rectum a drop of pus will be forced out through the external opening. By carefully feeling the region between the anal canal and the outside opening, one will often make out the cord-like feel of the fistulous tract. Oftentimes the internal opening is extremely difficult to find. Upon examination with the author's fenestrated anoscope, or the anoscope with the




Fig. 102.—Best type of glass syringe for injecting bismuth paste into fistulous openings.

oblique aperture, a small reddened spot, often raised somewhat from the surface, will be detected, from which pus can be squeezed out. When this point is discovered digital examination will reveal the induration underneath the surface, which discloses the direction of the fistulous tract. If, after careful examination of the entire circumference of the anal canal and lower rectum, no internal opening can be detected, the injection into the external opening of peroxid of hydrogen, (Figs. 102-3) methylene-blue solution, milk of magnesia, or bismuth paste will assist one in locating the internal opening by the point of appearance of the solution inside the anus or rectum.

The probe may be used to diagnosticate the presence and direction of a fistulous tract, but in order to be of any value, it must be *very fine* and *extremely pliable*—one made of annealed-silver suture wire is the best for this purpose (Figs. 27, 107, 109C). One

must be extremely careful in introducing a probe into a fistulous tract, or ~~or sinus if it is~~ very easy to force it through its walls into the anal canal or rectum, thus creating a false passage. If the probe does not pass easily, it is better to discard it than to use any force in its use. If there is a suspicion that the fistula communicates with the bladder or urethra, the injection of a mild solution of methylene blue 1 to 5 per cent into the organ will settle the question. If such a communication be present, the colored solution will exhibit itself at the fistulous opening in very short order.

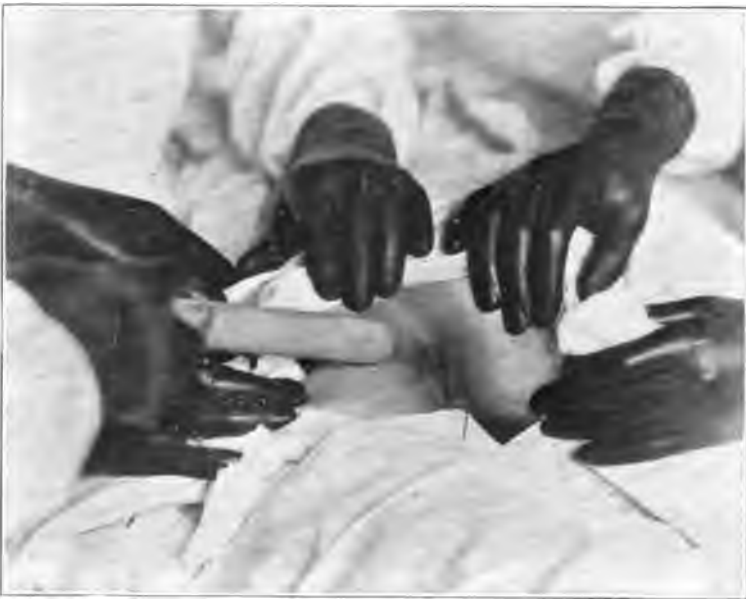

Fig. 103.—Injection of fistulous tracts with bismuth paste.

A five-grain capsule of methylene blue administered by mouth will, if a communication with the bladder or urethra exists, show a blue discoloration of the fistula in a few hours. The injection of a warm paste made from one part of bismuth subnitrate and two parts of vaselin into the external opening of a fistula, followed by a stereoscopic radiograph, is, without doubt, the best and most accurate diagnostic agent in our possession today. The existence of tracts, otherwise undiscoverable, is thus demonstrated, and the operation can be definitely planned in advance (Figs. 104-106).

**Treatment.**—The treatment of fistula, as a general thing, is best accomplished under general anesthesia, because many times, upon laying open what appears to be a simple fistulous tract, ramifications and extensions may be found which would necessitate more dissection than is possible to accomplish satisfactorily under local anesthesia. A case of simple, direct fistula, however, which is not tortuous, and in which the whole channel with its external and

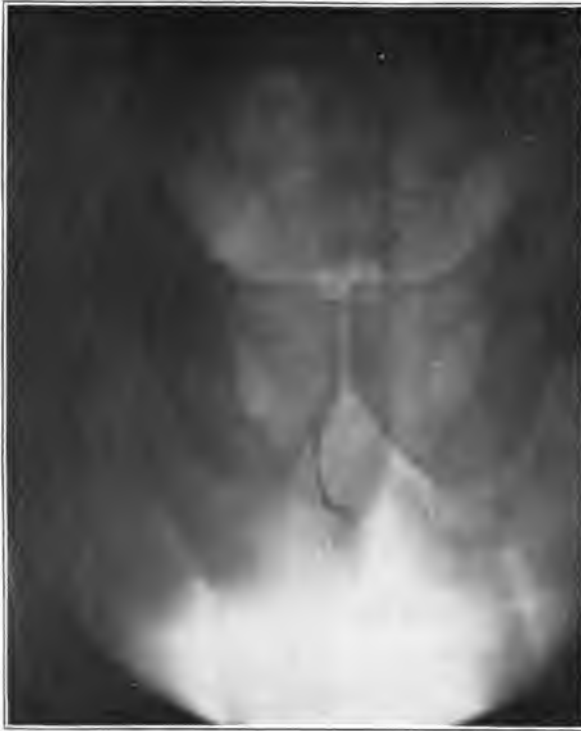

Fig. 104.—Radiograph of simple direct complete fistula.

internal opening is made out by the diagnostic methods mentioned above, may be treated under local anesthesia in any one of three ways.

**INCISION.**—Simple incision will suffice in some cases where the fistula is not deeply seated. After the bowels have been washed out with a saturated boracic-acid solution and the area around the anus scrubbed, shaved, and sterilized, the sphincter is anes-

thetized, according to the technic outlined in Chapter XV, and the tissues over the fistula injected to the point of blanching with  $\frac{1}{2}$  per cent solution of apothecin or a  $\frac{1}{4}$  per cent solution of eucain, or 1 per cent solution of quinin and urea hydrochlorid. A soft

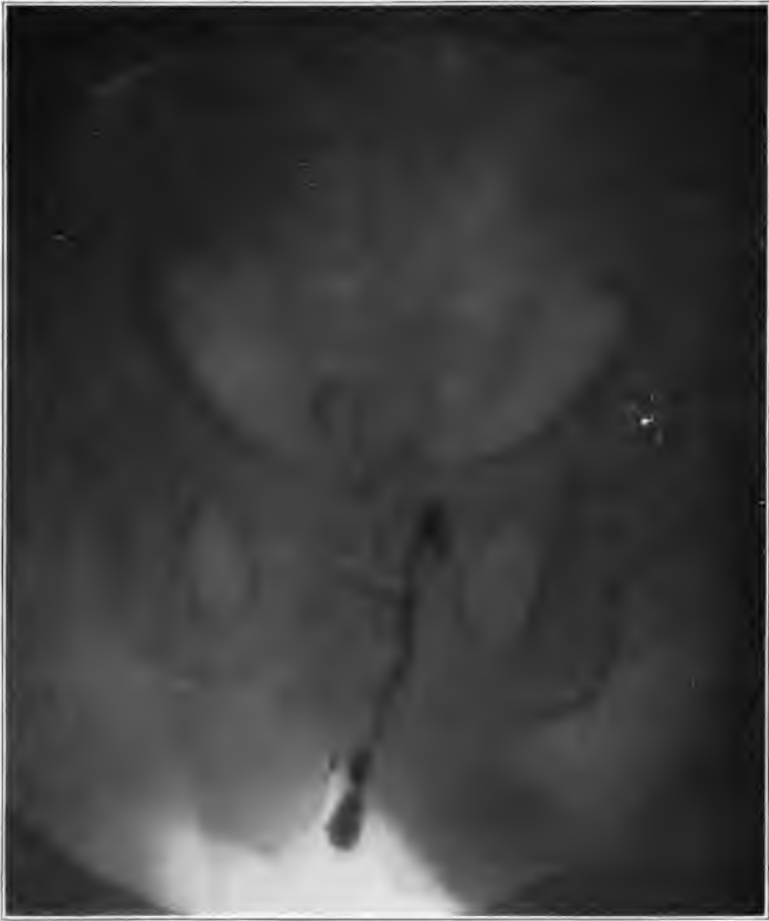

Fig. 105.—Complicated complete fistula. This ran up nearly six inches behind the rectum. Its branching channels would have been missed had it not been for the radiograph.

silver wire probe is passed through the fistula, its internal end drawn outside the anus by forceps, and twisted around the external end (Fig. 113). This threads the fistula on the probe, when it is released by dividing all the tissues between the wire and the

surface by a curved bistoury passed from without inward. This frees the ~~probe and lays open~~ the entire fistula. A pledget of cotton soaked with a 2 per cent solution of eucain or apothecin is pressed into the incision and is held firmly against the opened

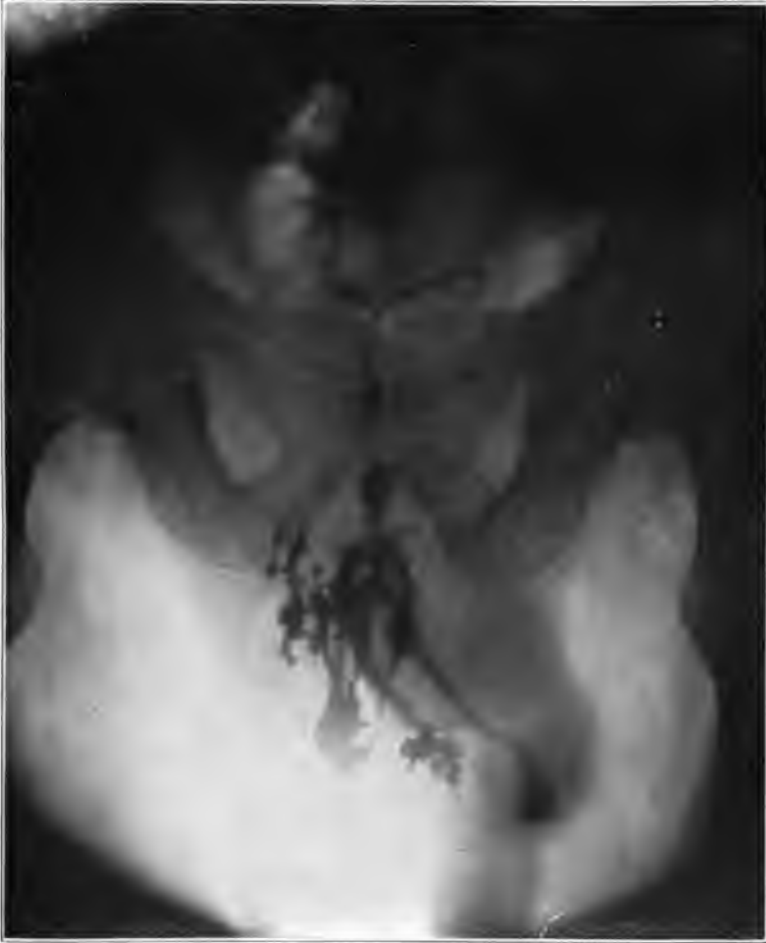

Fig. 106.—Multiple fistula communicating with urethra. This case had twelve external openings besides the one into the urethra.

fistulous tract for two or three minutes. It is then removed, and the diseased surface lightly curetted with a sharp spoon curette, the incision loosely packed with gauze, and an anodyne suppository inserted and a dressing applied.

Unless the direction of the fistulous tract is in a line at right angles to the fibers of the sphincter muscle, it must not be opened by a single straight incision. It is an invariable rule that any incision which must sever any or all of the fibers of the sphincter should cross it only at right angles (Fig. 111) in order to prevent incontinence afterward. The incision, therefore, must be so directed that it never severs the sphincter muscle in an oblique

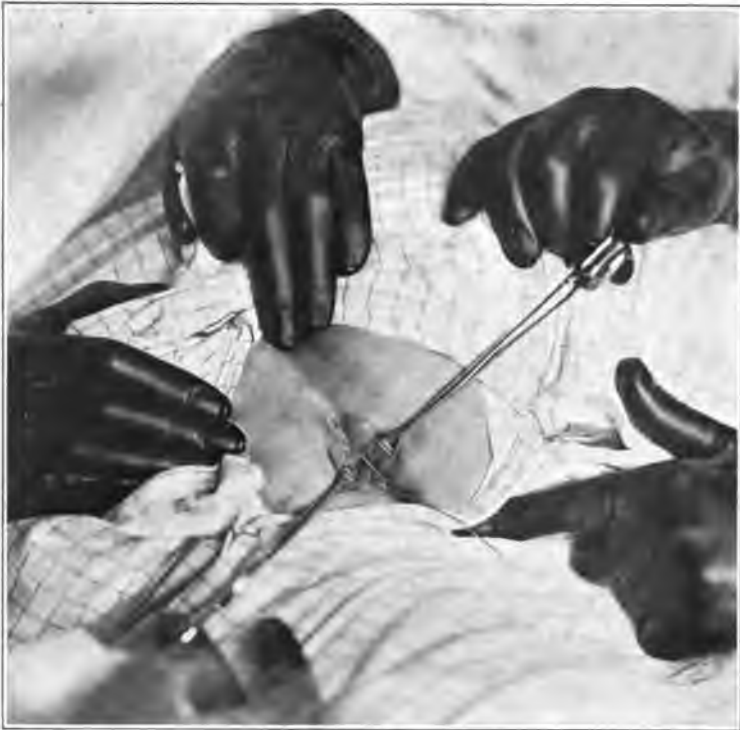

Fig. 107.—Soft silver probe passed through posterior direct complete fistula.

manner. Where the fistula is located just below the skin or mucous membrane and does not involve the sphincter, this rule does not necessarily hold good.

**EXCISION.**—In some cases it will be found advantageous, instead of simply opening the fistulous tract, to excise the entire canal. This is the most satisfactory operation when it can be successfully carried out, and should be the operation of choice



in all straight, uncomplicated fistulæ which are situated so that the tissues surrounding the fistula can be successfully infiltrated. After the usual preparation of the patient and anesthetization and dilatation of the sphincter muscles, the tissues surrounding the fistula are anesthetized. A  $\frac{1}{2}$  per cent solution of apothecin or a  $\frac{1}{4}$  per cent solution of eucain is injected into the skin along the line of incision up to the opening in the anal canal; then the surrounding tissues are distended with a  $\frac{1}{2}$  per cent solution of quinin and urea hydrochlorid, care being taken to completely surround the fistula on all sides. A silver wire is then inserted as described in the operation of incision, and the ends, which have been brought together outside the anal opening, are twisted so that they pull the whole fistulous tract outside the anus. This brings the entire tract into view. The skin is then incised the full length of the fistula *down to* the infiltrated tissues surrounding it, *but not through them* (Fig. 113). The incisions are then carried on either side of the infiltrated fistulous canal in such a way as



Fig. 108.—Grooved director.

to free it entirely, and remove it unopened and threaded on the silver wire or director. As the incisions are carried around the fistulous tract, they should be brought together in a V-shaped manner beneath it. After the removal of the fistula, the wound should be loosely packed with gauze, the anodyne suppository inserted, and dressing applied.

In the after-care, following both excision and incision, extreme care must be taken in the daily dressing of the wound to so arrange the drainage that it is firm enough to retard too rapid granulation, and yet placed so lightly as to allow the wound to gradually come together. Especial care must be exercised to keep the skin and mucous membrane from dipping in or growing down the sides of the incision. If granulation does not proceed as rapidly as it should, the gauze packing should be soaked daily with bovine before applying, or pure ichthyol or balsam of Peru should be

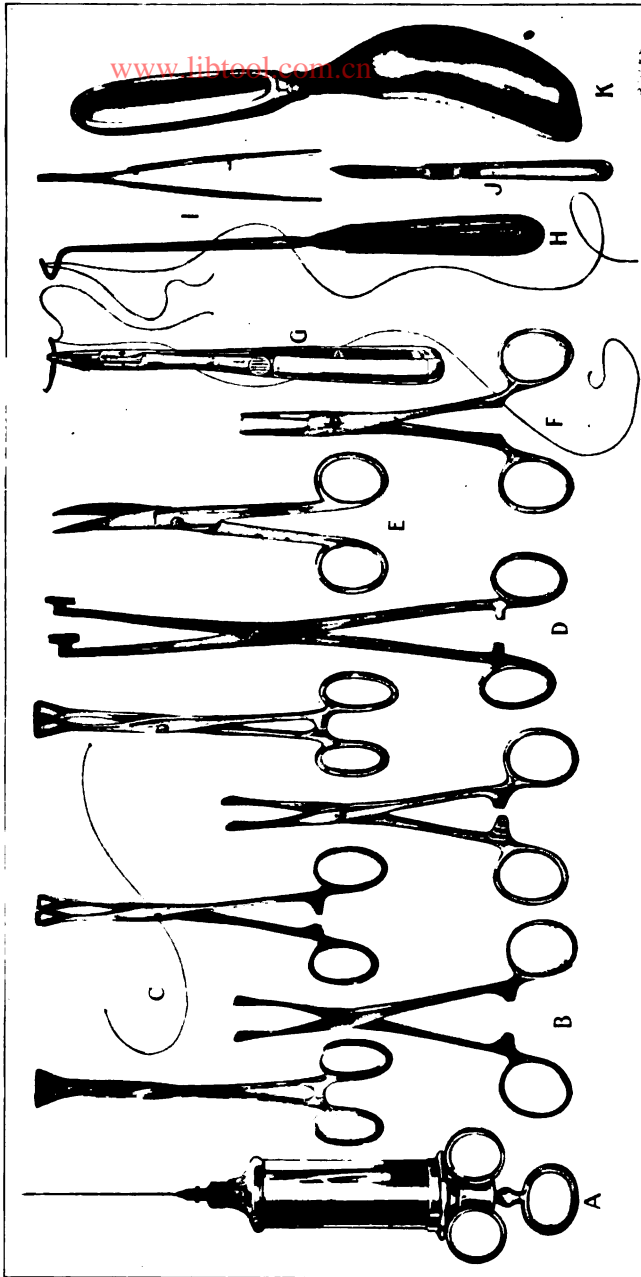


Fig. 109.—Principal instruments necessary in ano-rectal surgery under local anesthesia.

- A. Syringe.
- B. Pennington triangular forceps.
- C. Soft silver wire probe.
- D. Author's hemorrhoid forceps.
- E. Scissors curved on flat.
- F. Sharp-pointed forceps.
- G. Needle holder and curved needles.
- H. Author's ligature holder.
- I. Thumb forceps.
- J. Scalpel.
- K. Rectal retractor.

applied daily to the granulating surfaces. Scarlet-red ointment, 5 per cent, is also an excellent stimulant to unhealthy or sluggish granulations and should be lightly rubbed into the wound every third day. It is not necessary or advisable to use any of the antiseptic powders in the after-treatment of these cases. In many cases, the use of the Carrel-Dakin or other chlorinated solutions as irrigations will materially hasten the healing process.

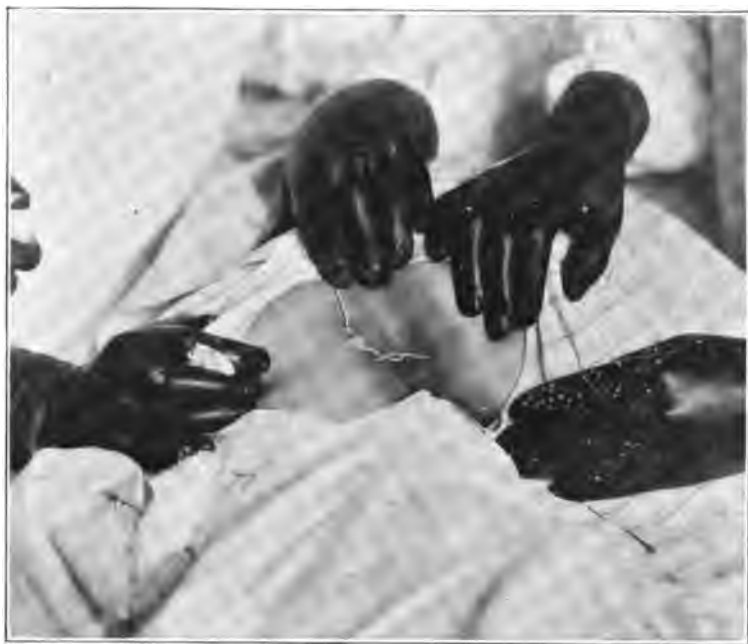

Fig. 110.—Fistula with three external openings.

The bowels are not allowed to move for three days, after which daily movements are not contraindicated.

Where it has been necessary to divide the external sphincter, either in part or in its entirety, there may be some temporary lack of full control of the bowel movements; but as the wound heals, control is regained so that no fear need be felt on this score. The patient is allowed to be up and around after the first day, and can pursue his usual occupation with little or no discomfort.

**LIGATURE OPERATIONS.**—In some few cases, from either the desire of the patient that no cutting operation be done, or some other contraindication, one may occasionally accomplish the cure of a simple direct fistula by means of a ligature, of linen, silk, or rubber. The author does not advise the use of the ligature in these cases, as he personally feels that they are never so satisfactory, and certainly not so quick in their results as a clean-cut surgical operation under local anesthesia. If the patient must have a ligature operation, the rubber ligature as used by the author in his operation for rectal valvotomy is to be advised, as it is quicker and surer in its results than silk or linen.

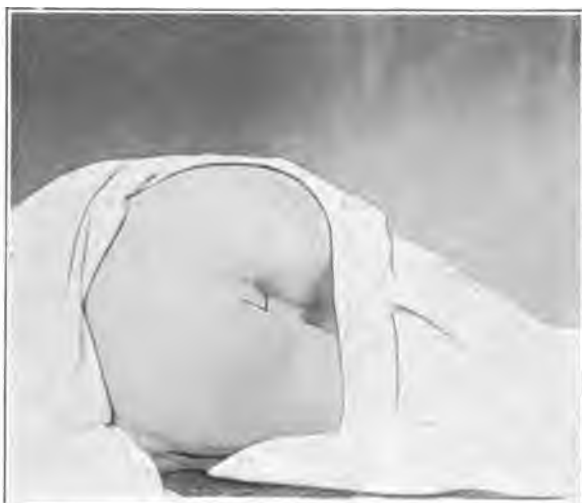

Fig. 111.—Right-angled incision for simple direct anal fistula. In a simple fistula by which the bowel communicates with the external integument crossing the external sphincter in an oblique manner, the external sphincter is cut at right angles by the method outlined.

The ligature is applied in the following manner: A fine flexible probe is threaded with the material of choice, and it is passed through the fistula from without inward; the point projecting in the rectum is grasped with forceps and is pulled through and outside of the anus. The ligature, if silk or linen, is then loosely tied so as not to constrict the parts but lightly surround them, and the ends are cut off. This leaves a small loop not unlike a seton. This is moved to and fro every day by the patient

and in the course of three to six weeks gradually wears through, the fistula ~~healing behind the~~ ligature in the meanwhile. In some cases, however, this will not prove efficacious.

Where more quick action is desired it is better to use the rubber ligature. It is passed through the fistula, threaded on a probe, in the same manner as the non-elastic ligatures, but when it is

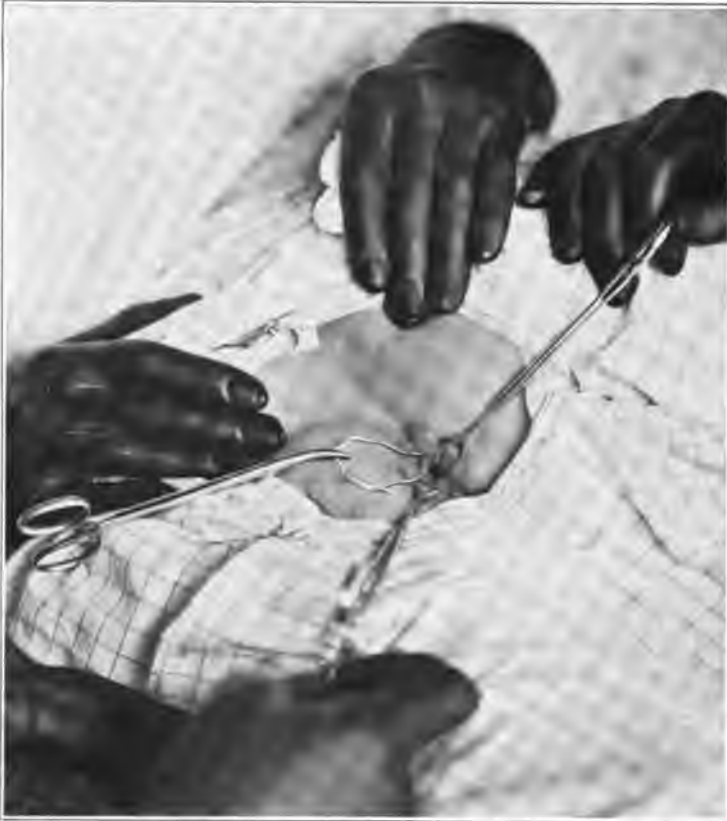

Fig. 112.—Soft silver probe passed through fistula and twisted into a loop.

fastened with a perforated shot, it is put on the stretch (Fig. 119). This causes so much pain and suffering for the first twelve hours that it is necessary to give the patient repeated doses of anodynes. After this period, however, there is comparatively no pain or discomfort until the ligature sloughs its way through,

which occurs in the course of from three days to a week. The suffering caused by the use of this rubber ligature is far more intense than that experienced after one of the radical measures mentioned above, and the author cannot conscientiously recommend it except in those cases where other measures are refused by the patient. After passing the soft silver wire probe through the fistula, it, itself, may be drawn taut, a shot slipped over its ends, and it will cut through the same as the rubber ligature. If the wire is used, the projecting ends should be cut flush with the shot (Fig. 120).

### EXTERNAL SINUS

The external sinus is caused by the opening of a perianal abscess on the skin surface only. It is characterized by the appearance, after the rupture or opening of an abscess in this region, of a red spot or papule from which pus is discharging. It is accompanied by discomfort to the patient when sitting, pruritus ani, or disagreeable moisture in the region; and its diagnosis from a complete fistula is made by the method of examination outlined above. In reality it is nothing more or less than a contracted abscess cavity which refuses to heal on account of the action of the sphincter muscle in keeping it open.

**Treatment.**—The treatment consists in the incision with curetting and drainage, or excision of the entire sinus tract. Some authors advise the converting of an external sinus into a complete fistula, and then operating as for complete fistula. The author cannot see the reason or advisability of thus converting a simple abscess cavity into a fistula, and would strongly deprecate any such methods. The author does not believe that it is ever necessary to divide the sphincter in order to heal an external sinus.

### INTERNAL SINUS

This variety of sinus is characterized by its having an opening into the bowel only, and is caused by the rupture into the bowel of a perirectal abscess whose point of least resistance was toward the rectum. The sinuses are characterized by their insidious and obscure onset and often go undiagnosed for a considerable time.

**Symptoms.**—The chief symptom is the appearance of a purulent discharge from the anus. This is accompanied by some smarting, burning, or itching, and a feeling of unrest or discomfort in the lower rectum. If there is much involvement of the mucous membrane surrounding this opening, there is also a tendency to diarrhea. When a patient has complained of pain in the rectum

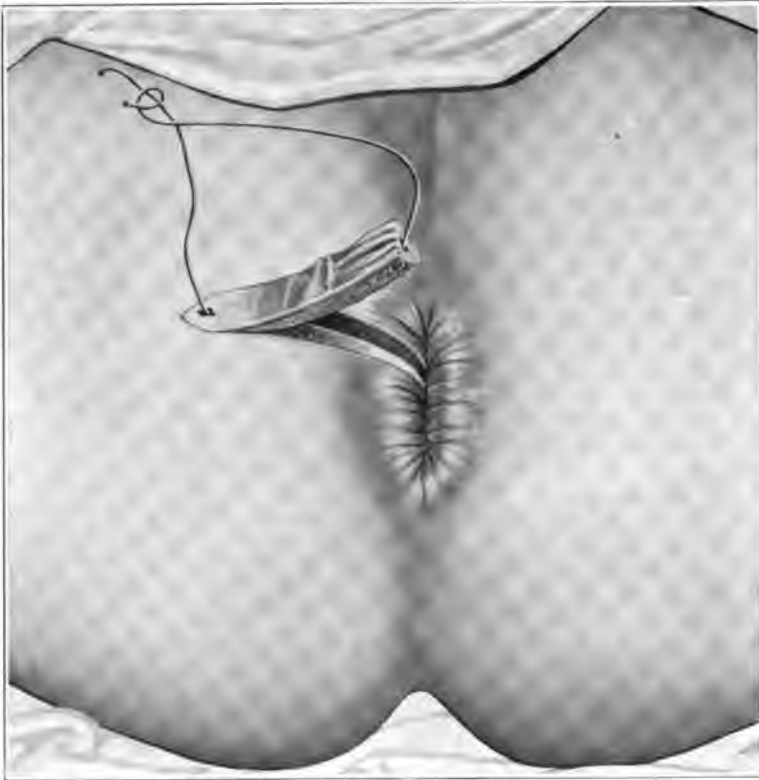

Fig. 113.—Complete direct fistula looped on soft silver probe, showing technic of excision or fistulectomy.

persisting for several days, accompanied by heat, throbbing, and rise of temperature; and these symptoms are more or less relieved just previous to the passage of a quantity of pus from the anus—the breaking of a submucous or perirectal abscess into the rectum should be suspected. The continuance of a purulent discharge off

and on for a period of weeks and months means the existence of an internal sinus.

**Diagnosis.**—With the patient in the lithotomy or lateral position, a roughened spot with indurated edges is felt on digital examination, usually posteriorly or laterally. Upon stroking or milking the interior of the rectum adjacent to this opening, a purulent discharge will be produced. Upon examination through the anoscope or fenestrated speculum the opening will be seen usually within the first inch from the anal margin. It will be

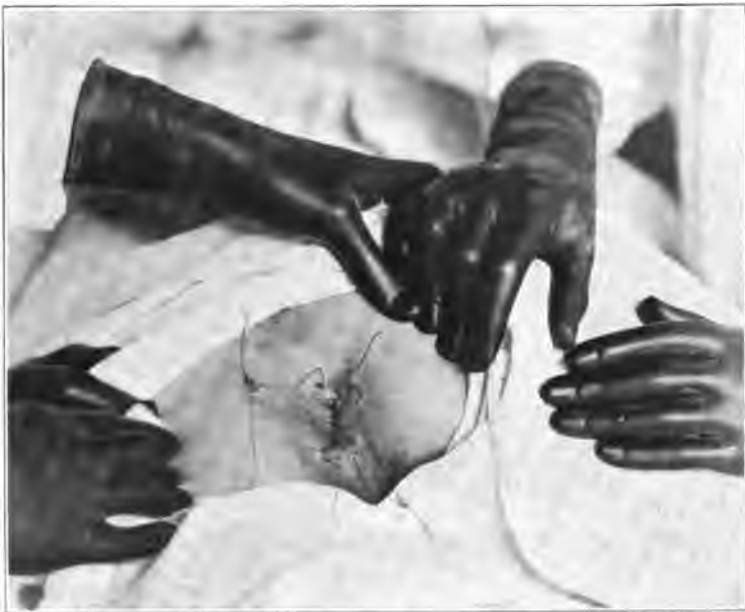

Fig. 114.—Multiple anorectal fistulae. Note probes in openings.

dark red in color, with edges somewhat raised, and the extent of the sinus can be readily determined by examination with a soft-silver wire probe. It is well to bend the probe on itself in the form of a hook, so as to determine the extent of excavation under the mucous membrane of the bowel in the direction of the anus, as not infrequently internal abscesses, particularly of the submucous variety, are found with their largest cavity extending down toward the anus. The internal sinus is more frequently





Fig. 115.—Excision of fistulous tract with wire looped through anterior tract.



Fig. 116.—Fistulous area dissected clean.

the result of a submucous abscess than of any other variety, and its channel very rarely penetrates the muscular coat of the rectum.

**Treatment.**—With the patient either in the lithotomy or lateral position and the external parts washed, shaved, and sterilized, the sphincter ani muscle is anesthetized and dilated according to the technic described in Chapter XV. Either a De Vibiss rectal speculum or the anoscope with the oblique opening is inserted so

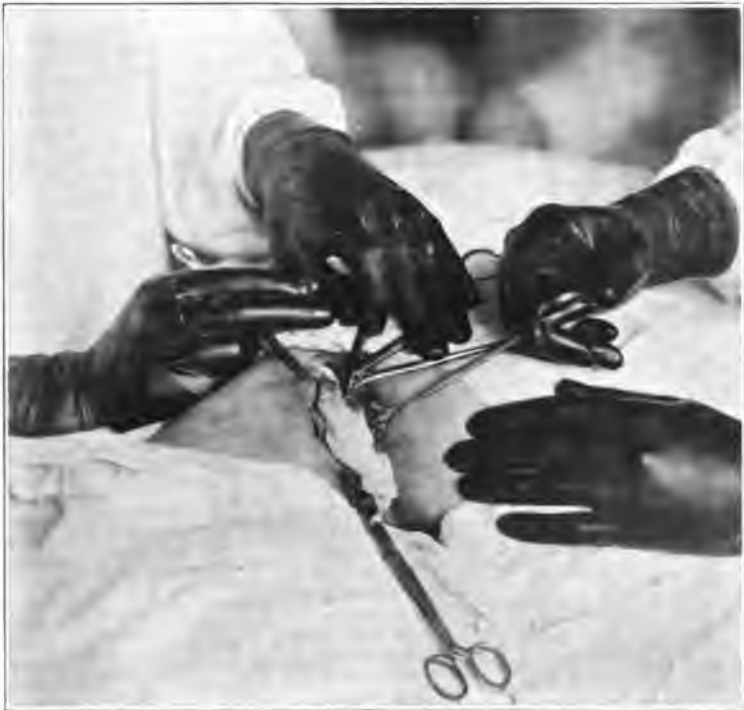

Fig. 117.—Wound lightly packed with dry gauze.

as to best expose the opening of the sinus. Its direction and extent having been determined, the tissues over the abscess and surrounding it are infiltrated with a  $\frac{1}{2}$  per cent solution of apothecin or  $\frac{1}{10}$  per cent solution of eucain, or  $\frac{1}{2}$  per cent solution of quinin and urea hydrochlorid. A grooved director is then inserted, and the sinus is laid open with a long-handled scalpel, a cryptotome (Fig. 121), or the author's angular rectal scissors. A pledget of

absorbent cotton soaked with a 2 per cent solution of the anesthetic used is then placed in the abscess cavity and allowed to remain for two or three minutes. The interior of the tract is lightly curetted, and a strip of sterile gauze inserted for drainage, one end of the gauze being carried outside the anus. In laying the tract open, the lower extremity should be opened well down to the anus, care being taken to leave no pockets at the lower end. In twenty-four hours the gauze is removed, and a cleansing enema given. The bowels should be allowed to move on the third day, the stools being softened by the administration of liquid petrolatum, and they should be kept regular daily. Ordinarily these cases will heal without any further attention. It is well, however, to have the patient report every other day for a week or so, and to make sure that the cavity is healing from the bottom and the granulations are healthy.

### **SUBMUCOUS TRACT, OR SINUS**

There is a variety of submucous sinus extending usually from the bottom of a crypt of Morgagni, which has been called by Wallis a submucous tract. It consists in nothing more or less than either an unusually small-calibered submucous sinus, or a very deep inflamed crypt. It gives rise to an irritating purulent discharge, which is very small in amount, but which sometimes is responsible for the production of pruritus ani. In order to determine its presence, it is advisable, in those cases where a discharge is noted and no internal opening of a sinus can be found, to examine with a probe each of the Morgagnian crypts and determine the presence or absence of one of these so-called submucous tracts. If present, it can be slit up with a sharp-pointed bistoury or cryptotome (Fig. 121) after anesthetizing as outlined above. It requires no after-treatment, other than examination every other day for three or four days, to make sure that it does not heal over at the surface before it is thoroughly healed underneath.

### **SUBMUCOUS OR MUCOCUTANEOUS FISTULA**

Cripps describes a variety of fistula very similar to the submucous tract or sinus, which he calls mucocutaneous fistula. It differs from the variety just described only from the fact that

it communicates with the surface through a small opening in one of the anal folds instead of one of the crypts of Morgagni (Fig. 99).

The treatment of this variety is just the same as that just preceding and need not be described in detail.

### INJECTION OF BISMUTH PASTE

The use of a mixture of bismuth subnitrate and vaselin in the diagnosis and treatment of fistulous tracts, sinuses, and abscess

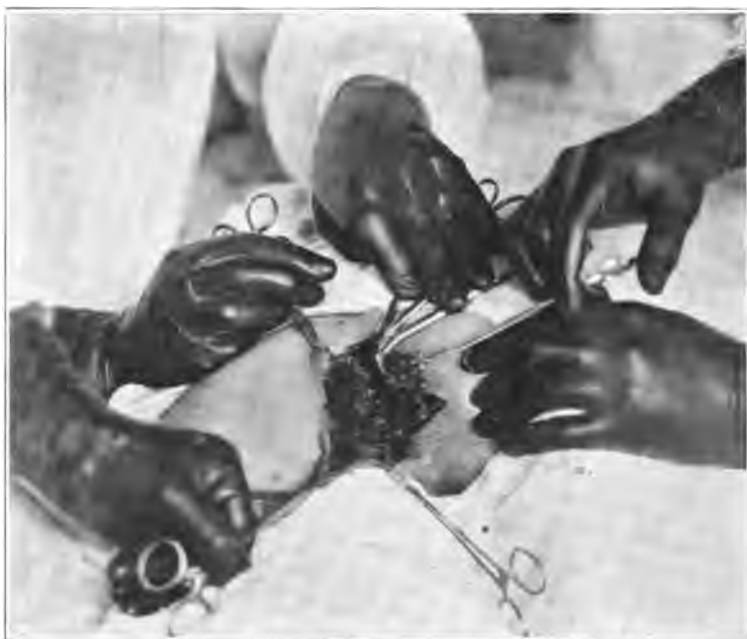

Fig. 118.—Another case illustrating extent to which dissection must be fearlessly carried to get results in multiple fistulæ.

cavities, first brought out by Emil G. Beck, of Chicago, has opened up an interesting field in the non-operative treatment of anorectal fistula. The paste recommended by Beck consists of bismuth subnitrate, 1 part, and vaselin, 2 parts.

The technic is as follows:

The patient's bowels are thoroughly irrigated, and the fistulous tract irrigated as well as possible. A cone-pointed glass syringe (Fig. 102) with asbestos packing around the plunger is filled with

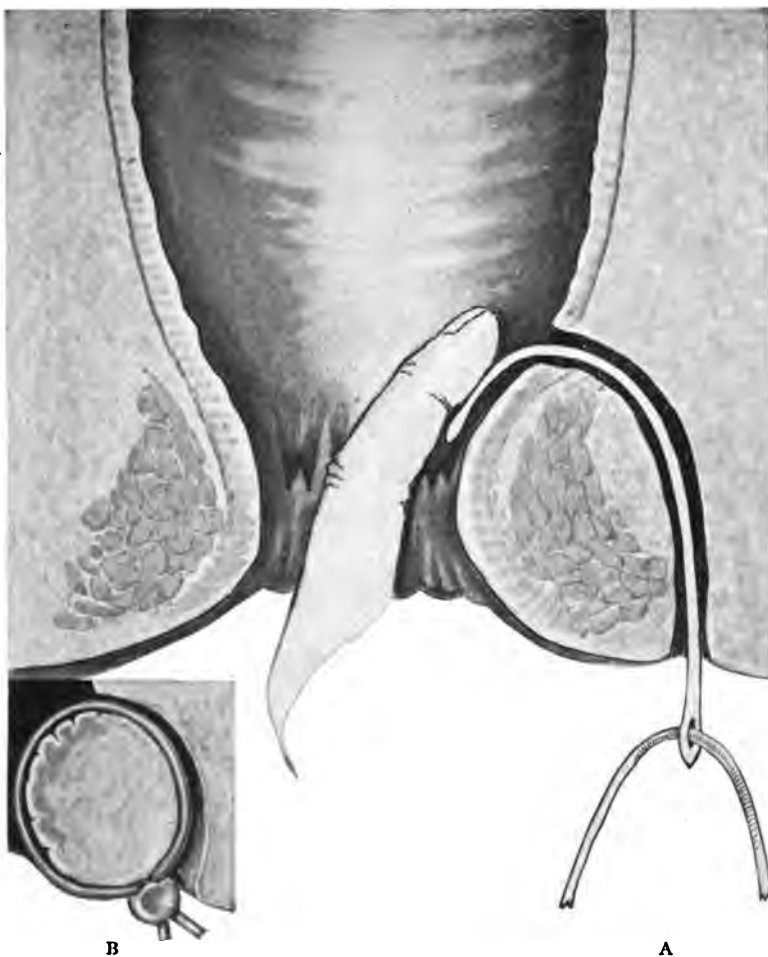


Fig. 119.—A. Technic of passing flexible silver probe, threaded with rubber ligature, through simple direct anal fistula.

B. Showing method of constricting the area between fistula, anal mucous membrane, and skin by means of the rubber ligature drawn taut and fastened with a perforated shot. (See Fig. 120.)

the mixture, which has previously been sterilized and allowed to cool to a temperature that will not irritate the patient. The point of the syringe is pressed well into the main opening of the fistula

(Fig. 103), if more than one exists, and the paste slowly injected. Should there be an internal opening or communication with the bowel, the finger of the hand not manipulating the syringe is inserted into the rectum to close that opening, thus preventing the paste entering the bowel and aiding in forcing it into all the diverticuli and tortuous tracts. The same precaution is observed

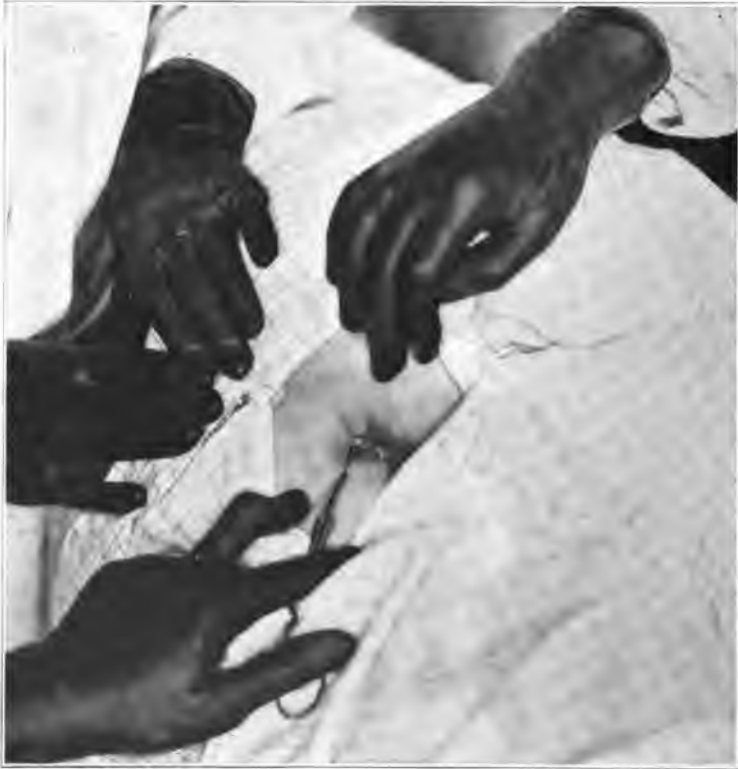

Fig. 120.—Silver wire looped through fistula and fastened with perforated shot.

where there is more than one external communicating opening. The syringe is not removed as soon as the tracts seem to be filled, but is held firmly in position with slight continuous pressure on the piston. A gauze dressing and T-bandage are then applied. From one to five injections suffice for the average case, and they should be given either once or twice a week. Some of the au-

thor's cases have required from two weeks to six months for a cure. While this method does not supplant the radical cure of fistula by operation, it should be thoroughly tried only in those cases where operative procedures are refused or not thought advisable.

### ANAL FISTULA IN THE TUBERCULOUS PATIENT

The only reason that the discussion of fistula in a tuberculous patient is taken up among these varieties of fistula, which can be treated under local anesthesia, is the fact that the tuberculous patient is a very poor subject for general anesthesia. The ap-

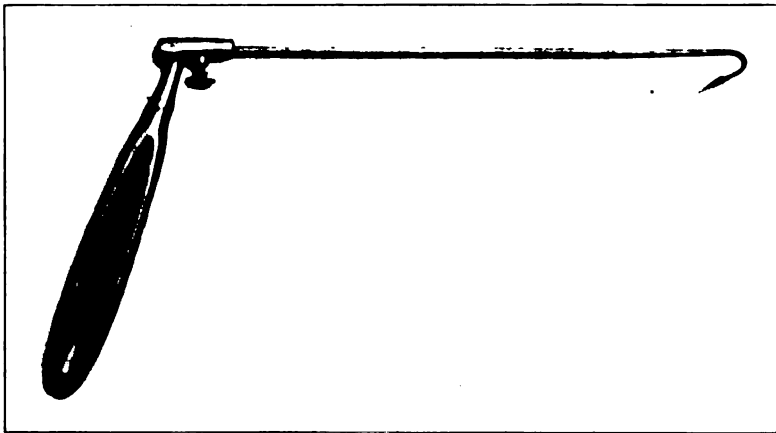


Fig. 121.—Author's cryptotome with adjustable handle.

parent connection between fistula and tuberculosis is due to the fact of the tuberculous patient's resisting powers being far below par. Abscesses in the anorectal region tend to fistula formation frequently enough in those individuals who have a normal resisting power; therefore it stands to reason that this should be more so in those suffering from any of the wasting diseases, and particularly the most common one, tuberculosis. The tuberculous patient's intestinal tract is constantly flooded with tubercle bacilli, and an abscess cavity communicating with the bowel forms a convenient location for them to locate and propagate. The old idea that the operation for tuberculous fistula has any bad in-

fluence on the patient's pulmonary condition is absolutely untenable. As a matter of fact, the local symptoms and inconvenience caused by the fistula make the patient much more irritable and add to his already overwhelming burden.

**Symptoms.**—The symptoms are those accompanying anal fistula, as described above, the constitutional symptoms of tuberculosis being also present.

**Diagnosis.**—The only points of difference between anal fistula, complicated with tuberculosis, and ordinary fistula are the presence in the discharge of *Bacillus tuberculosis*, and the pink, flabby-looking, unhealthy granulations found around the external opening. There is also a tendency to undermining of the skin edges and to silkiness of the circumanal hair.

**Treatment.**—The treatment of a tuberculous fistula is the same as that outlined above for the different varieties of ordinary anal fistula, with the exception that, when the fistulous tract is laid open after lightly curetting, its inner surface is swabbed with pure lactic or glacial acetic acid. Iodoform or iodized gauze is used for packing and dressing on account of the peculiarly antagonistic effect of iodine on the tubercle bacillus. The patient should be encouraged to live an out-of-door life, and his general bodily nutrition and physical condition looked after the same as those of any other tuberculous patient.

The injection of bismuth paste has in these cases occasionally proved very beneficial, and should be given a thorough trial, particularly in those patients in whom there exists some contraindications to surgery.



## CHAPTER X

### HEMORRHOIDS

Hemorrhoids, which is the most common disease of the ano-rectal region presenting a pathological change in the tissues, is also the most frequently self-treated condition affecting this region. We see more quack advertisements about, more nostrum remedies presented for, more irregular practitioners holding themselves out to cure hemorrhoids than any other disease (with the possible exception of venereal disease). In many quarters intelligent people, who would not think of consulting an unethical practitioner for any other condition, will consult the so-called "pile specialist"—who holds himself forth in the daily press—because they believe that members of the regular profession do not treat rectal diseases. It is perfectly astonishing to what an extent this belief is held; in fact, the author is sorry to say that he knows of instances where members of our profession, in good standing, have in the past referred cases of rectal disease to advertising, so-called rectal specialists.

There must be reasons for this, and the reasons are: the lack of instruction to the medical student on the subject of rectal disease, in the first place; the paucity of such instruction when given as an incident in the teaching of general surgery; the repugnance with which the average practitioner approaches a case requiring rectal examination; the cursory character of such examination; the distaste of the average practitioner for local treatment of the ano-rectal region; the inability to make a correct diagnosis; and the superficial treatment given and the early discharge of the patient by the practitioner, who is anxious to get rid of a case that is unpleasant for him to treat—all are responsible for the position which the average general practitioner occupies today in the diagnosis and treatment of rectal diseases.

It is the action of the profession itself which has created the

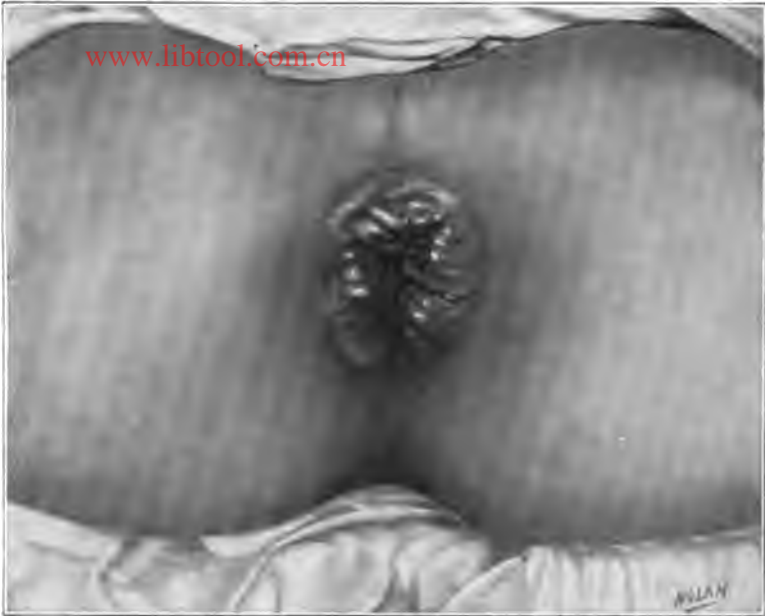

Fig. 122.—Interno-external hemorrhoids.

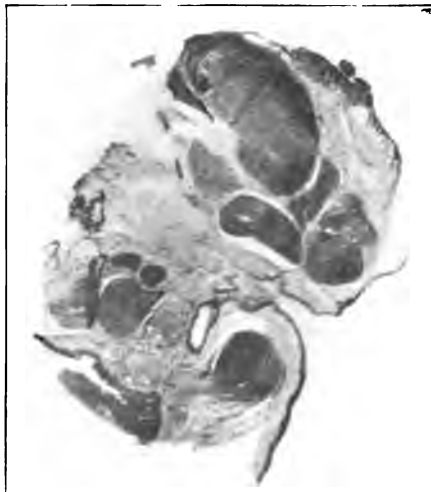

Fig. 123.—Section of interno-external pile (photo-micrograph X4). Upon the right-hand side of the illustration the upper half has a covering of mucous membrane, the lower half a covering of skin; between these there is a sulcus, which corresponds with the pectinate line. The upper half is therefore internal pile; the lower, external pile. The structure of the interior of both portions is practically identical—loose areolar tissue with dilated thrombosed veins.—After Ball.

special field of proctology—the anus and rectum being organs peculiar to themselves and being subject to many medical and surgical diseases in the same way as the eye, the ear, the nose, the genital and urinary organs; and call for just as much special medical as surgical care. The general surgeon knows nothing about, and cares less for, the medical treatment of these organs; and the general practitioner who is able to treat the medical

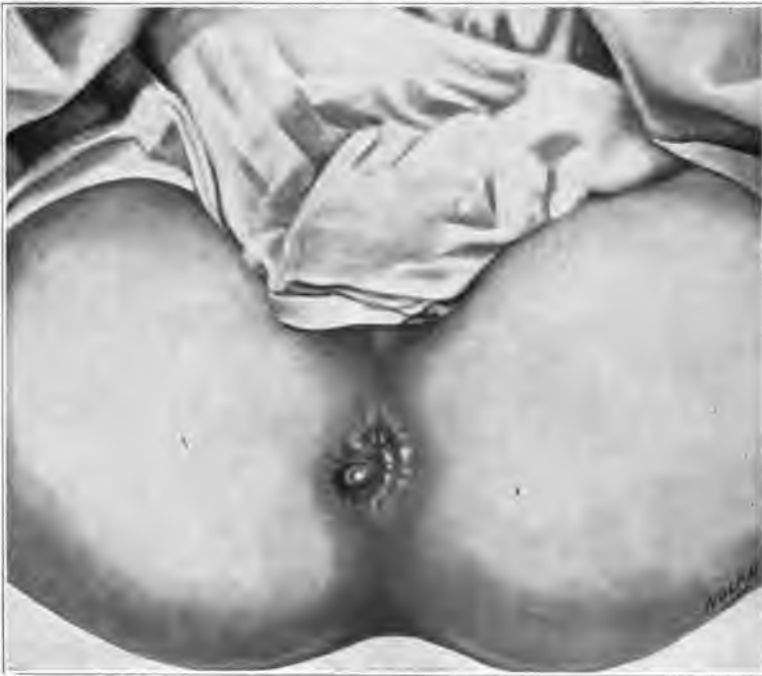

Fig. 124.—Acute external thrombotic hemorrhoid.

conditions is not, as a rule, properly equipped to do so. Thus, the proctologist came into existence—a man who, by special study of this particular region of the body, is able to give special care of either a surgical or medical nature, and often both in the same case, as may be required. With his attention directed particularly to this line of work, his operative measures are directed largely along the lines of conservatism. He endeavors to save

as much tissue as he can and cut as little as possible and by intelligent after-care to promote healing much nearer to the normal, as a rule, than does the man who "cuts a fistula and ties a pile," and allows it to go at that.

That the average general practitioner is fully as capable of treating many anorectal diseases as the proctologist, if he has at his hand a practical work outlining indicated therapeutic measures in a plain, simple way, goes without saying.

The treatment of hemorrhoids in the hands of the practitioner has undergone vast changes since special attention has been directed along this line. In many ways it has been much simplified, and the results have been extremely satisfactory.

### VARIETIES

Hemorrhoids are tumors or swellings produced by pathologic changes in the veins of the anus and rectum, accompanied by more or less infiltration of the surrounding tissues and hypertrophy of the anal skin. They are usually divided into three classes, according to location: *external*, *internal*, and *externo-internal*—the external being those outside the sphincteric region and covered by integument; the internal being covered with mucous membrane, and whether situated inside the bowel or prolapsed outside, they are still internal hemorrhoids. An internal hemorrhoid being prolapsed and remaining prolapsed will appear externally, but if it is covered by mucous membrane it is an internal hemorrhoid. The externo-internal variety (Figs. 122-123) is a combination of the two preceding, being covered by both mucous membrane and skin. The external, again, is divided into thrombotic, integumentary, and varicose.

The thrombotic variety (Figs. 124, 125, 126, 127) usually appears suddenly; may range in size from a pea to a large grape; is rounded, of a bluish or purplish hue, and extremely painful. It feels much larger to the patient than it really is, and is characterized by its sudden onset. The integumentary variety (Fig. 128) is a sac or pouch of thickened skin, usually the remains of an old acute thrombotic hemorrhoid which has undergone absorption. The varicose variety consists of a collection of small varicose veins covered by skin and situated at or outside the anal orifice.

The internal variety is divided into the capillary or granular, and the varicose. The capillary hemorrhoid may not appear as a tumor at all, but simply a circumscribed reddened area which bleeds upon touch. Where there is an enlargement, it looks not unlike a raspberry. Its color is brighter than the varicose variety, and it bleeds more freely. The varicose internal hemorrhoid is caused by a varicosity of the veins of the superior hemorrhoidal plexus, the varicose veins, together with the infiltrated tissues sur-

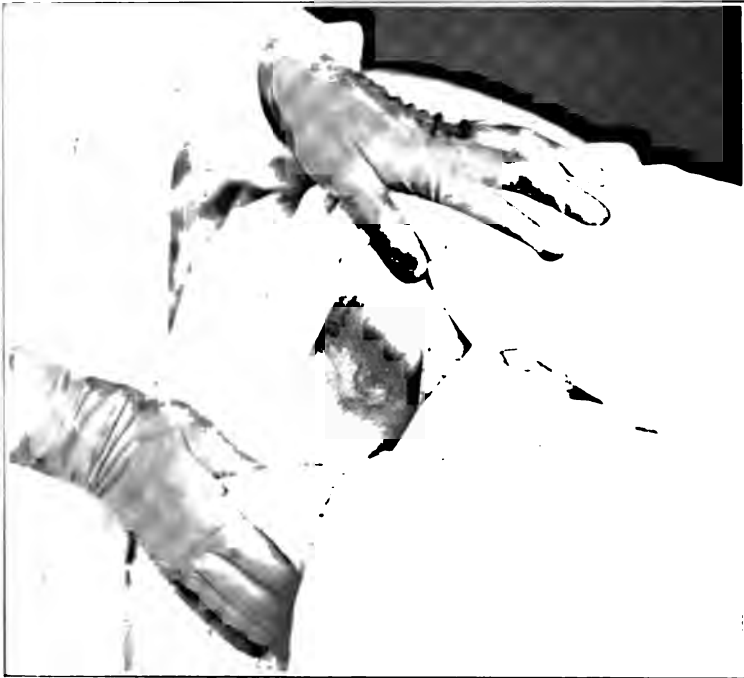

Fig. 125.—Ulcerating acute thrombotic hemorrhoid.

rounding them, forming rounded tumors of varying sizes. The internal hemorrhoids may also be divided into pedunculated and sessile, either of which variety may protrude through the anus.

### CAUSES

A great many different causes have been assigned for hemorrhoids. The principal predisposing cause is the erect position

which man assumes, and the lack of valves in the rectal veins, causing the weight of the column of blood to rest on the veins of the lower rectum and anus. Anything which will abnormally increase this weight, or the pressure on the vein wall will, of

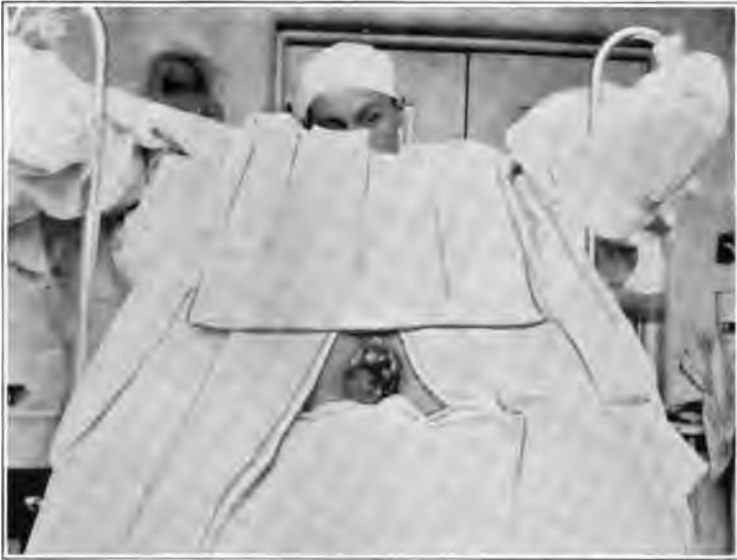

Fig. 126.—Acute thrombotic hemorrhoids of unusual size



Fig. 127.—External thrombotic hemorrhoids. This specimen, removed from one of the author's cases, illustrates the thrombotic nature of the condition. There were four, large, distinct thrombi present in this case, and they were removed *en masse*.

course, cause dilatation and enlargement. Constipation is an occasional cause of hemorrhoids. The large, hard stool, as it passes down through the rectum, pushing the blood ahead of it, and milking the veins, causes unusual pressure in the lower portions of the hemorrhoidal plexus at the anal canal. A more common cause,

however, than constipation is the effort to relieve constipation by means of purgatives, the unnatural straining and the irritating liquid stools being responsible for more cases of hemorrhoids than constipation itself. Overeating and lack of exercise, or anything which causes a congestion of the portal circulation, are important causative factors in their production. Occupation enters largely into their etiology. Men who are on their feet continually—such as policemen, letter-carriers, pedestrians, railroad men, traveling men—are all peculiarly subject to hemorrhoids. Men are more

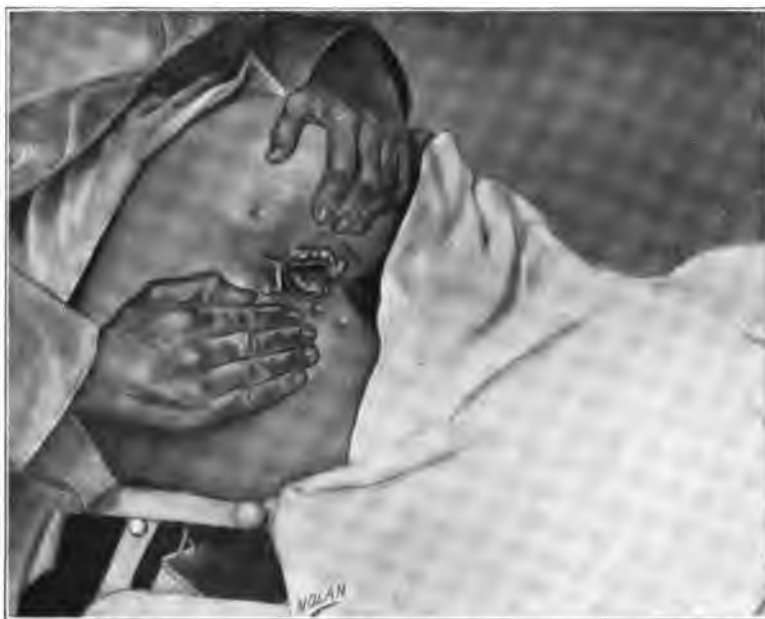

Fig. 128 —External cutaneous hemorrhoids. Drawn from one of the author's cases suffering from tertiary syphilis.

often treated for hemorrhoids than women, not so much because they are more subject to hemorrhoids, but because women are treated for many gynecological conditions, the relief of which relieves the hemorrhoids. Many women who suffer from hemorrhoids caused by the pressure of the pregnant uterus will be spontaneously cured after delivery.

The most common cause, however, is, in the opinion of the writer, the abuse of the cathartic habit.

**SYMPTOMS**

[www.libtool.com.cn](http://www.libtool.com.cn)

The three principal symptoms associated with internal hemorrhoids are bleeding, pain, and prolapse.

**Bleeding.**—The bleeding is of especial interest. Many patients suffering from hemorrhoids scarcely ever, if at all, present the

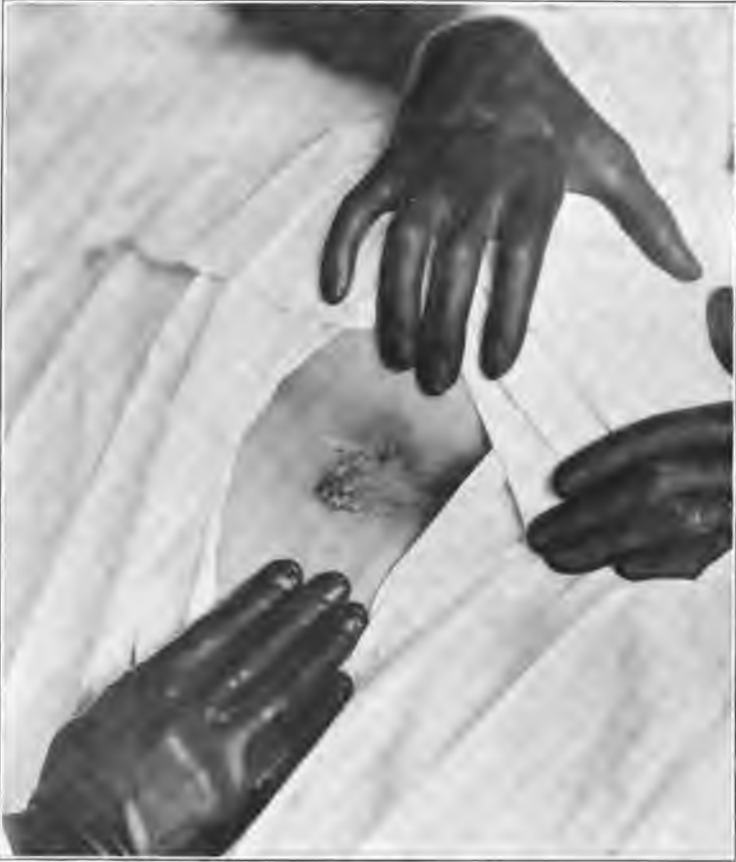

Fig. 129.—Granulomata (syphilitic) sometimes erroneously diagnosed as external hemorrhoids.

symptom of hemorrhage. In these cases the mucous membrane covering the hemorrhoid is thick and is not easily ruptured, and the hemorrhoids may protrude without hemorrhage. Where bleed-



ing is observed, it may be very slight, consisting of a few drops following the stool, or is simply noticed on the toilet paper after stool. In other cases it is very profuse, several ounces being lost with each stool, and some patients have become profoundly anemic from this cause alone. It might be mentioned, in passing, that it is extremely important in every case of anemia to inquire as to whether the patient is suffering from hemorrhoids or not; as not infrequently the rectal hemorrhage will be found to be the cause of the trouble, and its relief will be followed by a prompt

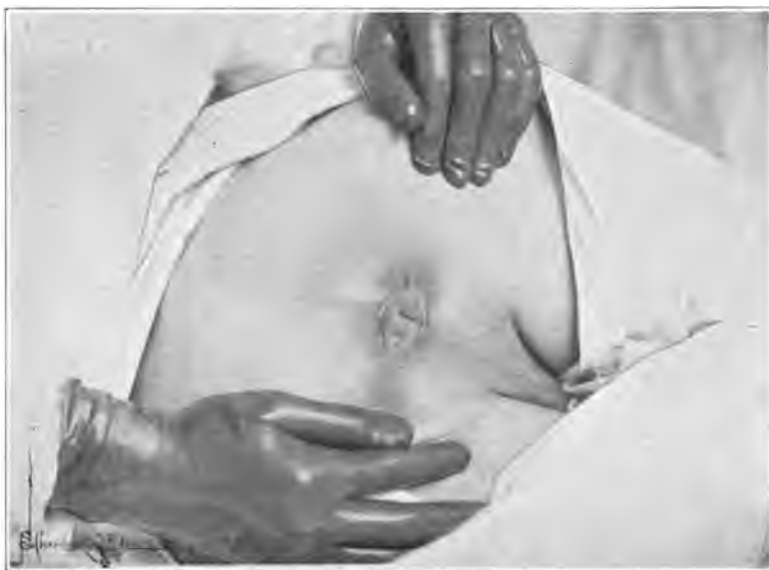

Fig. 130. Single prolapsing internal hemorrhoid.

return of the normal amount and quantity of blood. The author has observed in anoscopic examination typical arterial spurting from the midst of a hemorrhoidal mass.

Before leaving the subject of bleeding from hemorrhoids, the author wishes to utter a word of caution about *making a diagnosis of hemorrhoids from the symptom of rectal hemorrhage alone*. Many a poor unfortunate has gone to an untimely end because beginning malignant disease was erroneously diagnosed as hemorrhoids from the symptom of bleeding alone. It makes no dif-

ference as to the age of the patient or whether there is pain present or absent, the symptom of hemorrhage should never be taken for granted as denoting the presence of hemorrhoids, and even where hemorrhoids are observed, no one should be satisfied that he has made a correct diagnosis until he has made a proctoscopic examination (which must include the upper rectum and sigmoid) and the presence of commencing malignant disease has been absolutely excluded (Frontispiece).

It is not the intention of the author in this work to cite cases,

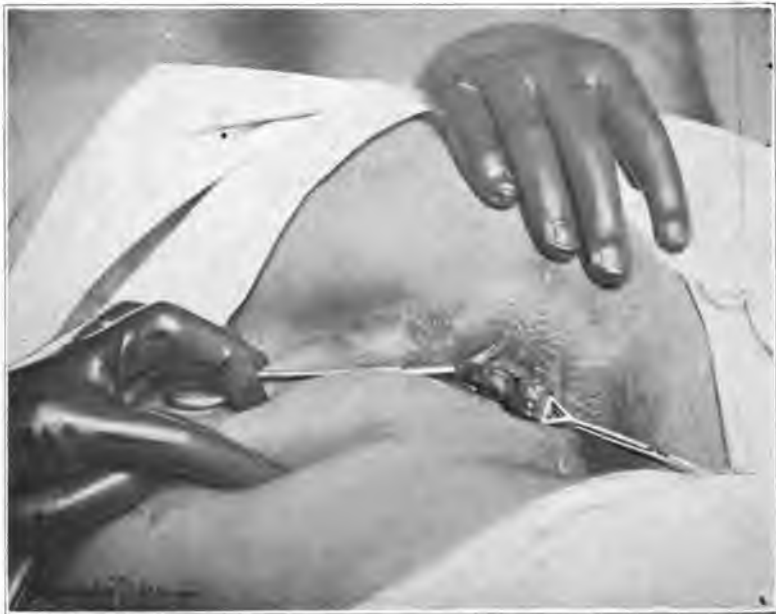

Fig. 131.—Prolapsing internal hemorrhoids at anterior and posterior commissure.

but he could cite numerous ones seen in consultation where the diagnosis of malignant diseases was made too late to save the patient's life, because the patient had been allowed to go for months—being treated for hemorrhoids without ever having had a rectal examination made. He had also seen numerous cases of anal fissure diagnosed as hemorrhoids simply from the appearance of blood following stool.

**Pain.**—The pain of internal hemorrhoids is somewhat characteristic, but not pathognomonic. It is more a dull aching sensa-

tion accompanied by a feeling of fulness with or without throbbing. It is seldom of an acute nature. The patient complains of a constant sense of weight and dragging in the rectum and in the sacral region, and is usually more or less mentally depressed. Many patients having hemorrhoids suffer from no pain whatever.

The pain accompanying the acute thrombotic pile is sudden, lancinating in character, and is accompanied by the appearance of the tumor. The pain soon becomes of an intense, throbbing character, and the relief given upon the incision of the hemorrhoid and

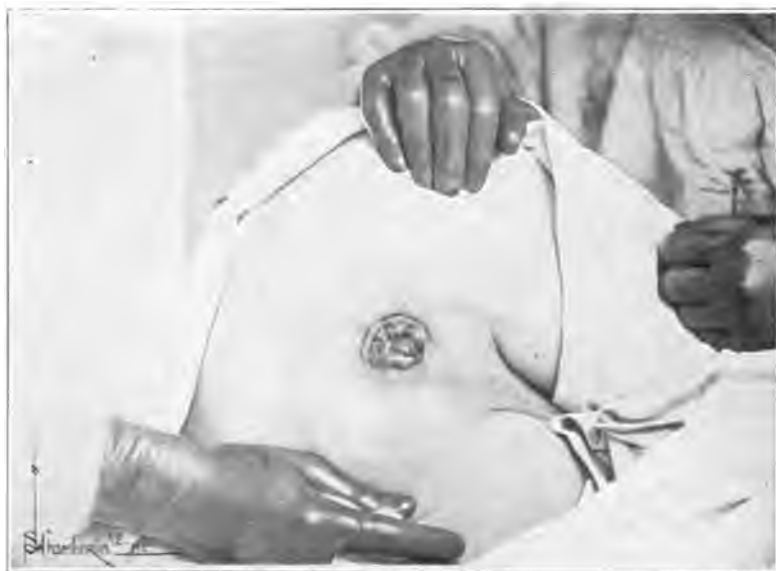

Fig. 132.--Prolapsing internal hemorrhoids. A suitable case for local anesthesia.

removal of the clot has to be observed or experienced to be appreciated. The other varieties of external hemorrhoids are not accompanied by pain at all, unless inflamed, but may be accompanied by considerable pruritus.

**Prolapse.**—In those cases of internal hemorrhoids which prolapse (Figs. 130-134), the prolapse is slight at first, gradually increasing with time. At first the prolapse is replaced readily by the patient after stool, but as time goes on and the prolapse becomes aggravated, it will come down not only with the stool

but when the patient is up and about and walking. It finally remains ~~down and can only be~~ replaced when the patient is lying down, or in the knee-shoulder position, and even when held by pads or retaining devices soon slips out again, when the patient resumes the erect posture and starts to walk.

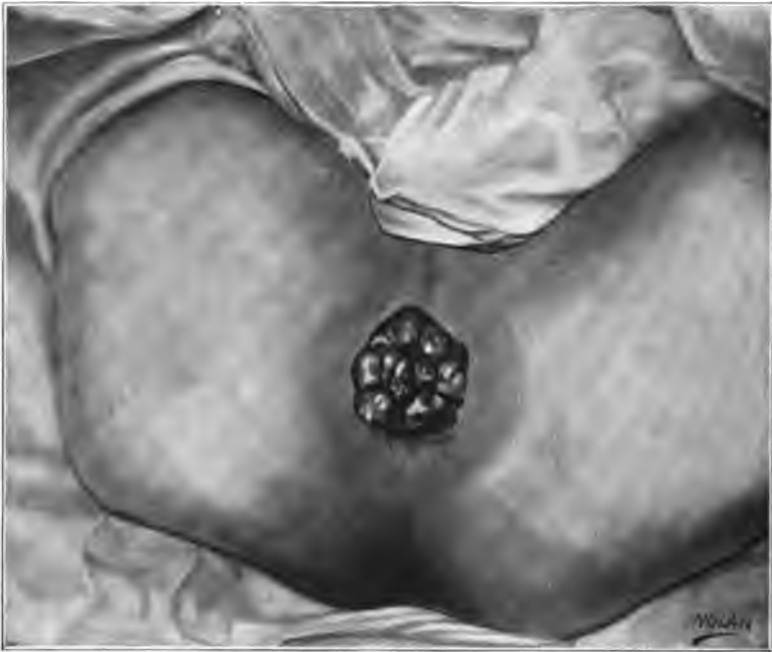

Fig 133.—Prolapsing internal hemorrhoids. This illustrates the extent to which internal hemorrhoids may prolapse. This case was of twenty years' standing, and unless the hemorrhoids were prolapsed after stool, there was nothing to distinguish the external appearance of the anus in this case from the normal.

## DIAGNOSIS

One would think that much space devoted to the diagnosis of hemorrhoids would be superfluous and that the condition almost diagnoses itself, but it is because of the many unfortunate erroneous diagnoses of other conditions for hemorrhoids that the author wishes to dwell somewhat upon this point.

In the first place, the average patient, when consulting a physician for suspected hemorrhoidal or other rectal troubles, is asked to stand in front of a table (Fig. 11) and bend over on it for a

“rectal examination,” and the physician inserts his index finger as far as the patient will allow him, and that is all; or he may take a bivalve rectal speculum (Fig. 135), and if he succeeds in inserting it far enough, will proceed to dilate. Usually, before he has gone very far, the patient is off the table and refuses to

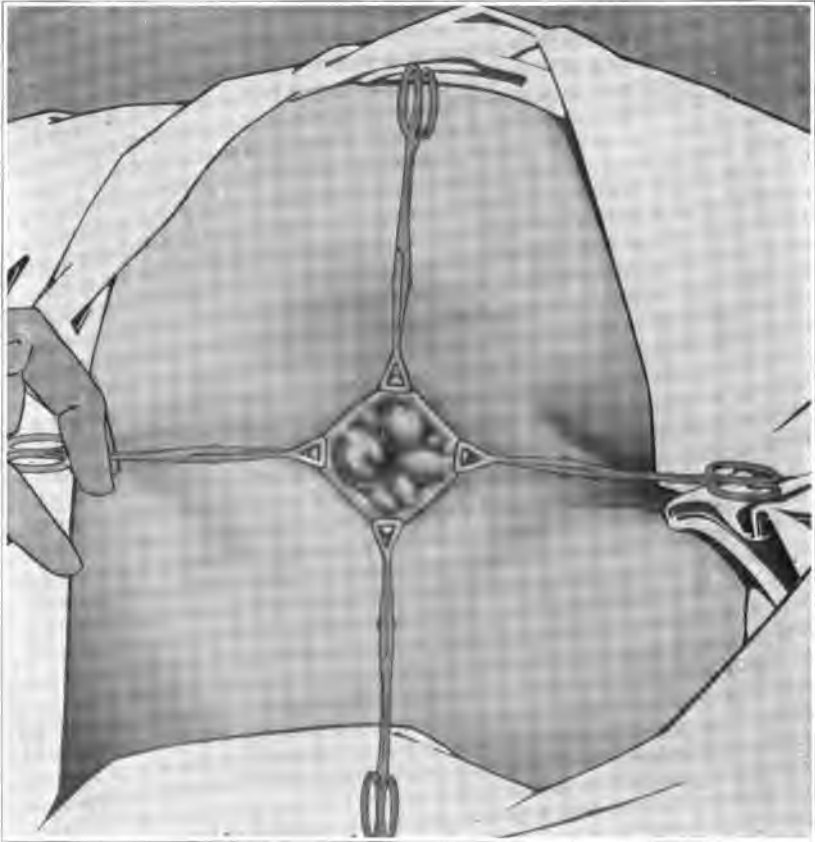


Fig. 134.—Prolapsing internal hemorrhoids exposed ready for operation.

allow a repetition of the attempt, and that is about as far as the average rectal examination goes. This was even in our recent mobilization of an army of over four million men, the type of rectal examination given recruits. Thousands of beds in overseas army hospitals were occupied by patients whose rectal diseases should

www.libtool.com.cn

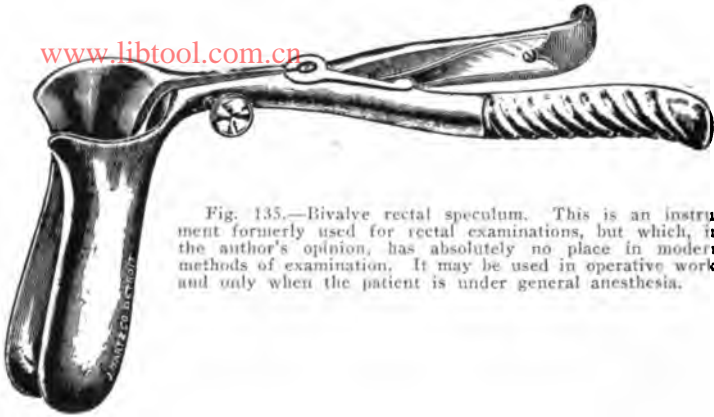


Fig. 135.—Bivalve rectal speculum. This is an instrument formerly used for rectal examinations, but which, in the author's opinion, has absolutely no place in modern methods of examination. It may be used in operative work, and only when the patient is under general anesthesia.

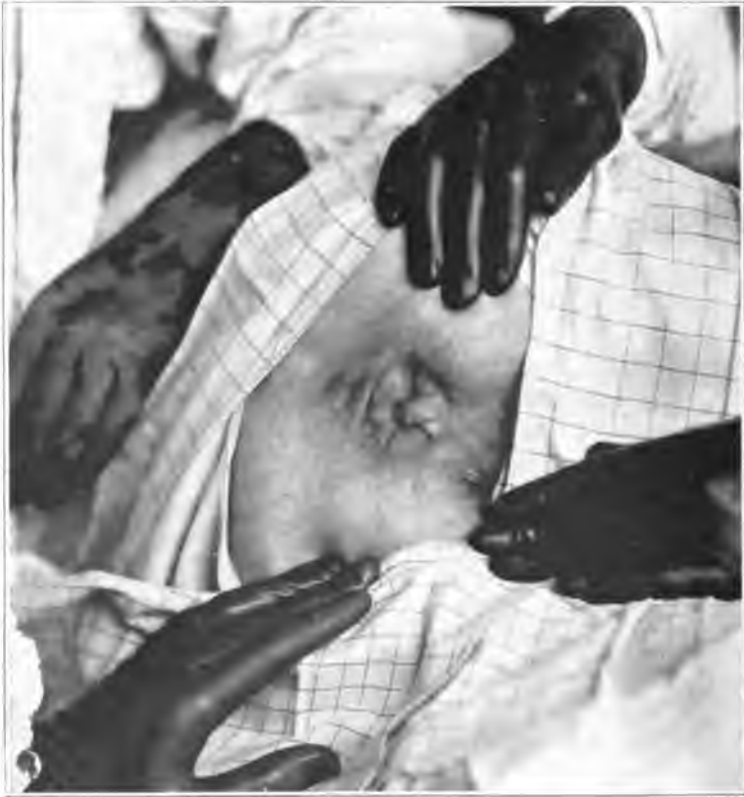

Fig. 136.—Circumanal injection of anesthetic completed.

have been discovered at home if proper and modern diagnostic methods had been taught at medical training camps, and these methods used.

Now a complete examination (Chapter III) of not only the rectum, but the lower sigmoidal cavity as well, may be accomplished, practically without pain, and without any dilating specu-

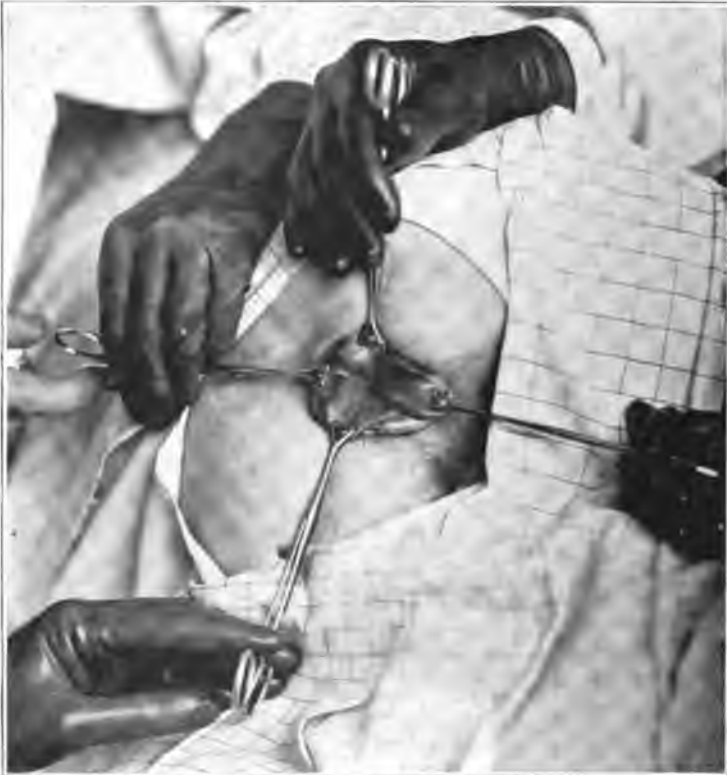

Fig. 137.—Showing complete anesthesia and sphincteric relaxation.

lum. Cylindrical proctoscopes of various lengths are used, and through them everything from the anal orifice to the lower sigmoidal cavity can be examined ocularly, and an absolutely correct view of the actual condition obtained.

In making an examination for hemorrhoids, first ask the patient to lie upon the table in either the right or left Sims' position according to the personal preference of the examiner. With the

finger protected by a thin-rubber finger cot, and properly lubricated, you proceed as follows:

After making a careful inspection of the anus and surrounding tissues, press the point of the finger against the anus, asking the patient to bear down as if he were trying to force the finger out. The palmar surface of the finger should be toward the posterior commissure of the anus. Allow the finger to slowly enter until you have entered the lower rectal cavity; then, slowly turning your finger from side to side, note the conditions. As the finger is being withdrawn, it should be swept around slowly, taking note of the absence or presence of protrusions or abrasions, depressions, elevations—in fact, everything which does not feel like the normal velvety smoothness of the anal canal. An important thing to remember is not to try to feel too high. These conditions will all be found within the first two or two and one-half inches, and if one does not insert the finger too far, he will be able to detect a great many things in this small area. One must remember that hemorrhoids of considerable size may not present any unusual feeling to the examining finger, because of the pressure of the finger emptying them of blood, and they are more or less effaced at the time. However, one can become sufficiently expert, so that he can detect the presence of even these soft elevations, and the sulci between them.

If the hemorrhoids are accompanied by a painful fissure, one may not be able to insert the finger without the use of local anesthesia, the technic of which will be found in Chapter XV. After digital examination has been completed, an anoscope is introduced, the obturator withdrawn, and the patient asked to bear down. This will prolapse hemorrhoids into the instrument, where they can be examined without any difficulty, or have the patient assume the squatting position and “strain” the hemorrhoids out. Then introduce the proctoscope, and following this, the sigmoidoscope. In introducing the proctoscope, however, one must employ the knee-shoulder position. It is in this position only that satisfactory dilatation of the rectal cavity by pressure of the atmospheric air can be obtained. The folds and creases are all smoothed out, and every portion of the rectal lining mucous membrane can be explored with the eye; the size and condition of the rectal valves can be determined, and the presence or absence of ulcers of the rectal wall as



well. The sigmoidoscope is entered in this position, the exaggerated lithotomy or inverted position, and having an obturator the end of which can be turned at an angle, it can round the rectosigmoidal curve without difficulty. Even the pneumatic sigmoidoscope is used with better success in this position, because the pelvic organs all fall away from the bowel and allow freer dilatation.

Thus it will be seen that this entire region can be successfully and completely examined without using an instrument which will dilate the sphincter any more than the base of one's index finger. No dilatation is required, and no pain is experienced by the patient. Of course, during the examination it may be required to swab out or

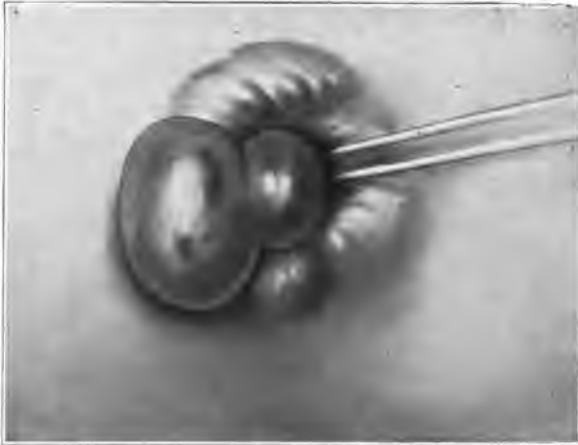

Fig. 138.—A single interno-external hemorrhoid injected with anesthetic solution ready to operate.

irrigate the rectum, all of which can be readily done through the instruments mentioned.

**Differential.**—In the differential diagnosis between hemorrhoids and other conditions, which may simulate some of their symptoms, one might mention first, fissure.

**FISSURE.**—Fissure of the anus, which may accompany hemorrhoids, is more often found alone. The pain of fissure is almost diagnostic; it is sharp, cutting, most intense during the passage of a stool. It remains often for several hours following stool, and is accompanied by more or less tenesmus and spasm of the sphincter muscle. The bleeding of fissure always accompanies or follows the stool. It may consist merely of a blood streak on the stool or sev-

eral drops of blood following the stool, or it may merely be a spot or smear on the toilet paper. The presence of a fissure causes the patient to put off the bowel movement as long as possible, and when he does defecate, the hard fecal masses cause more pain and discomfort than before. Digital examination reveals a fissure with more or less indurated surrounding tissue, situated most often at the posterior commissure, or in either the right or left latero-posterior quadrants.

ULCER.—Ulcer of the rectum may be incorrectly diagnosed as hemorrhoids, on account of more or less slight hemorrhage which

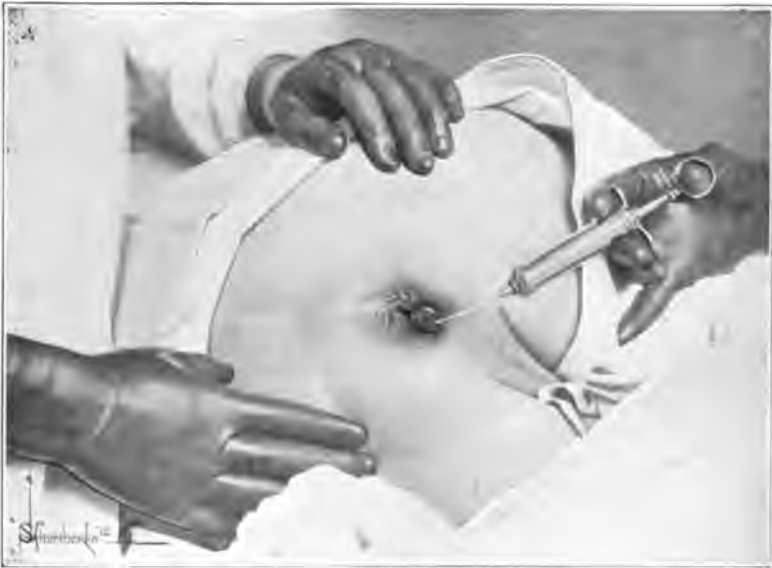

Fig. 139.—Injection of anesthetic solution into a prolapsing hemorrhoid, showing the amount of distention necessary for anesthesia.

may accompany it. Ulcer, however, is usually accompanied by diarrhea, and ocular examination, after eliciting a history of blood in the stool, will settle the diagnosis at once. The same may be said of proctitis. An intensely congested and injected rectal mucous membrane may bleed on stool; but if the conscientious practitioner examines every patient who presents the symptom of blood in the stool, many sources of hemorrhage other than hemorrhoids will be detected, and the correct diagnosis made.

CANCER.—Of course, the one important thing always to bear in mind when the symptom of hemorrhage is present is the possibility

of the presence of cancer. Cancer, well advanced, may be found in patients who present the appearance of perfect health. When a patient of any age, from childhood up (just as often below forty as above), presents a history of rectal hemorrhage, which has been preceded by more or less digestive disturbance, including diarrhea alternating with constipation of several weeks' or months' standing, with considerable intestinal gas—even though there is no evidence of cachexia or loss of weight—one should be extremely suspicious of malignancy somewhere in the intestinal tract. If the blood is of a dark color either of a tarry nature or genuine coffee-

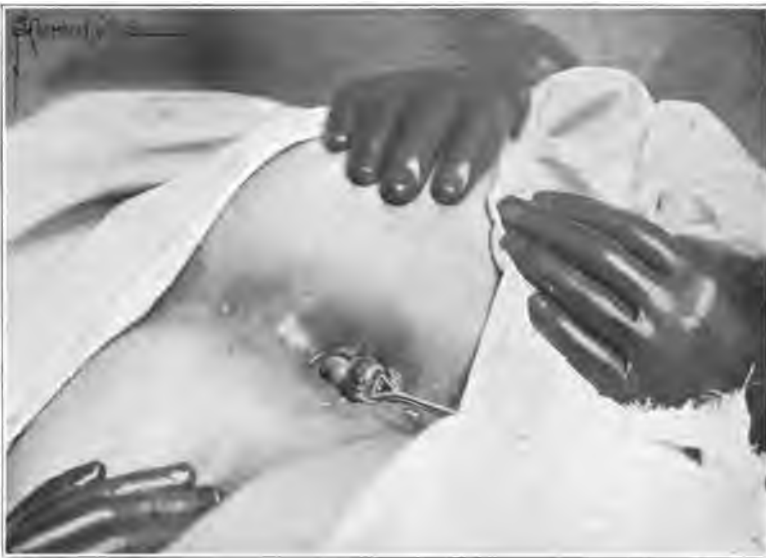

Fig. 140.—A prolapsing interno-external hemorrhoid at anterior commissure, anesthetized ready to operate.

ground, the location of the cancer is higher up. If the blood is fresh, bright red in color, and closely follows the stool, and has a more or less nauseating odor accompanying it (an odor which is almost pathognomonic), one should examine very carefully for commencing cancer in the rectum or sigmoid. When one considers that fifty per cent of all cancers occur in the gastrointestinal tract, and when one realizes that sixteen per cent of all cancers of the digestive tract occur in the rectum or sigmoid, one can readily understand how important it is to examine every case which presents the symptoms of rectal hemorrhage.

**PROTRUSIONS.**—Various protrusions may be mistakenly diagnosed as hemorrhoids. Polypi, which may occur at any age, but occur more often in children, protrude with the stool. They are harder, more fibrous in character than hemorrhoids, and when replaced by the finger, go back into the rectum with more or less of a snap, which is somewhat characteristic of this condition. Anoscopic examination shows the polypus to be a small, rounded, hard, fibrous

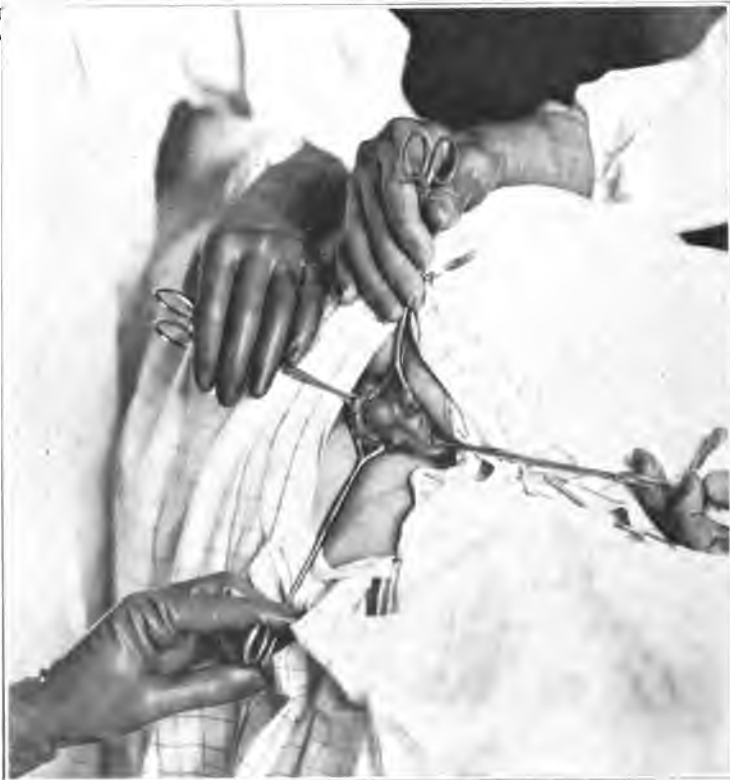

Fig. 141.—Distention completed, showing internal hemorrhoids presenting.

tumor, attached by a pedicle narrower than itself, its usual attachment being somewhat higher in the lower rectal cavity than that of a hemorrhoid. Enlarged anal papillæ have been diagnosed as connective-tissue piles. The enlarged papilla, however, is small, always triangular, though occasionally long drawn out and somewhat ribbon-shaped. It is pinkish in color and does not contain

varicose veins. The point or tip is always downward, and it is attached by its base or widest portion. They are situated at the juncture of the anus and rectum, at the lower edges of the crypts of Morgagni.

Venereal warts of large size have been incorrectly diagnosed as external integumentary piles (Fig. 129), but close inspection, after obtaining a history of discharge from venereal disease, should make the diagnosis evident. Occasionally the protrusion of an anal or perianal abscess may simulate an inflamed external hemorrhoid. However, with the finger of one hand in the rectum and the other

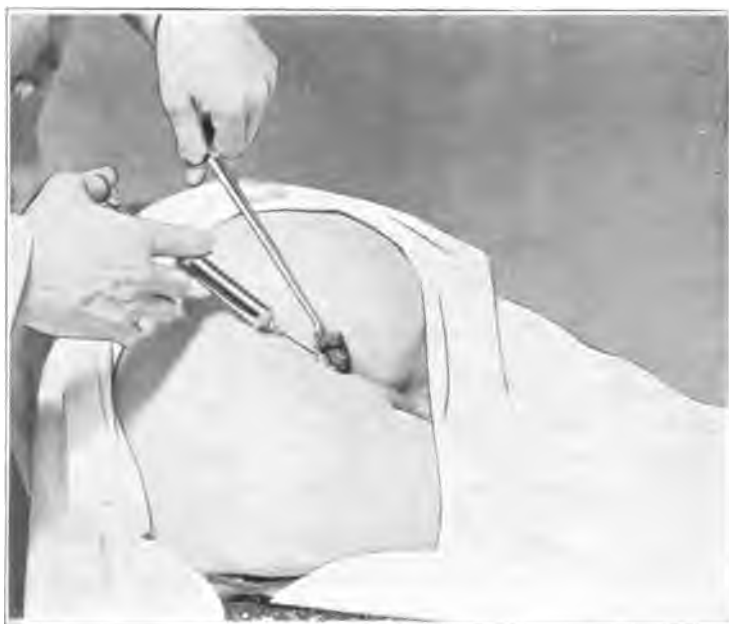


Fig. 142. -Method of injecting prolapsing pedunculated internal hemorrhoids.

hand on the protrusion, the site of the abscess cavity can be made out, and fluctuation often determined. The sudden onset, accompanied by the intense pain, swelling, redness, and rise of temperature, always points to abscess formation rather than to hemorrhoids.

The protrusion which is often mistaken for prolapsed hemorrhoids is prolapsus ani or recti. There are three degrees of prolapsus:

1. Simple eversion of the anal mucous membrane.
2. The ~~descent outside of the~~ descent outside of the rectum of more or less of all coats of the rectum.
3. The descent of the entire rectum with more or less of the sigmoid, which may come down to the anal orifice but not necessarily protrude.

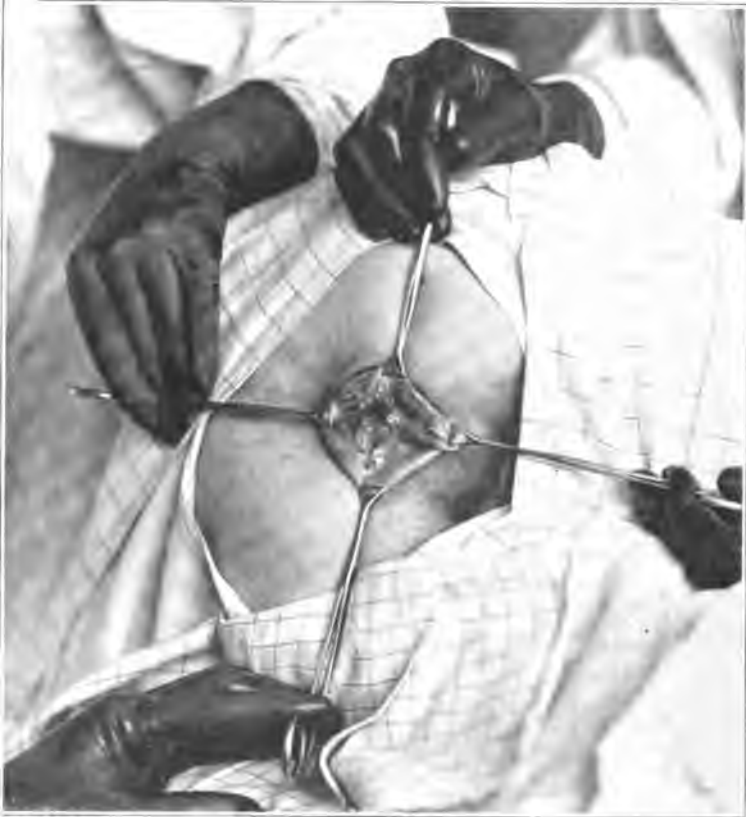


Fig. 143.—Perfect exposure of operative field by use of Pennington forceps.

Prolapsed mucous membrane is differentiated from prolapsed hemorrhoids by its smooth, velvety touch, reddish color, and the absence of varicose veins. It is continuous with the rectal mucous membrane, and a distinct sulcus can be made out between the anus and the protrusion in the second and third varieties. In the first variety, careful examination will show it to be mucous membrane

continuous with anal skin. Of course, in aggravated cases of prolapsed hemorrhoids more or less prolapse of the mucous membrane of the anus will accompany it, and the diagnosis is self-evident.

### TREATMENT

The treatment of hemorrhoids we shall divide into palliative and radical.

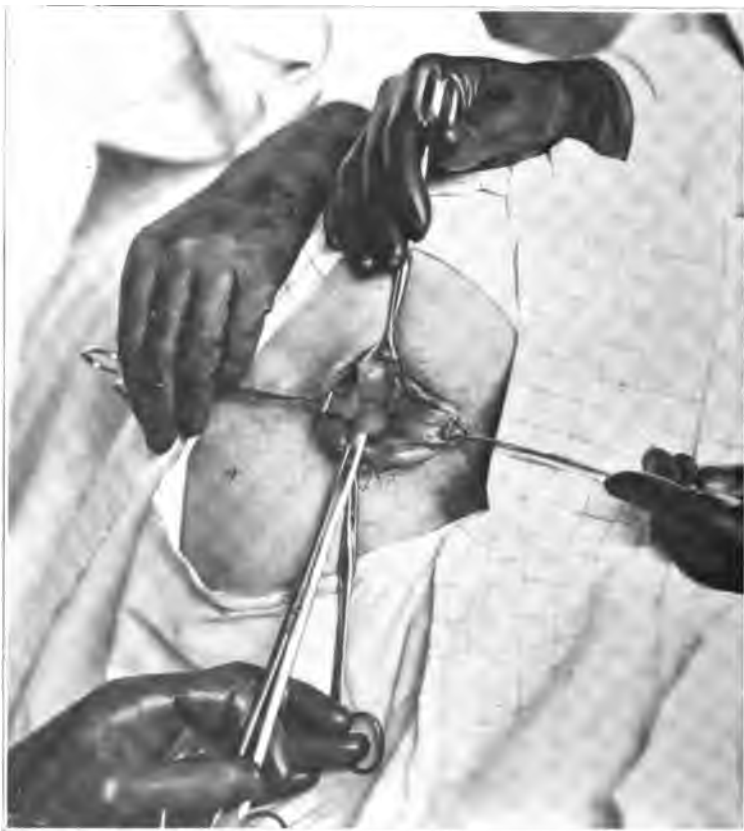

Fig. 144.—Grasping hemorrhoid with author's hemorrhoid forceps.

**Palliative.**—The palliative treatment of hemorrhoids is, however, *not a cure*, but a relief of acute symptoms for a more or less short period of time. When the patient presents himself suffering from acute prolapsed internal hemorrhoids with more or less strangulations by a contracted sphincter, the first thing to do is to reduce the

prolapse. This is not always so easy as it seems. The contraction of a sphincter on the hemorrhoids shuts off the return blood supply, and the hemorrhoids swell so much that they cannot be replaced without anesthesia. If however, a solution of adrenalin chlorid (1:1000) or glycerin be applied by means of compresses, the blood-vessels will shrink to such an extent that reduction is often possible. Sometimes the application of cold or alum solutions will cause sufficient shrinkage to make reduction easy. Chloretone,  $\frac{1}{2}$  per cent, apothecin 1 per cent, or eucain 1 to 4 per cent may be added to these solutions to render them analgesic. Occasionally, applications of fluidextract of ergot will help in maintaining the contraction of the vessels after adrenalin has brought them down. An ointment containing adrenalin, 1:1000, chloretone, 20 grains to the ounce in lanolin, injected into the anus after stool and three or four times a day, at regular intervals through a long-nozzled collapsible



Fig. 145.—Author's hemorrhoidal forceps.

tube, will often assist in allaying an acute attack of hemorrhoids. However, all of these treatments are merely palliative, and the hemorrhoid upon the slightest irritation will enlarge, prolapse, and even strangulate again.

Some patients who absolutely refuse more radical measures will submit to cauterization of the hemorrhoid by the thermocautery, thus causing a deposition of scar tissue on the surface of the hemorrhoid, which by its contraction somewhat lessens its size, and repeated applications of the cautery will reduce the hemorrhoid so that it will not be noticeable for some time. Occasionally such irritants as glacial acetic acid, chromic acid, and saturated solution of nitrate of silver have been used for a like purpose. The puncture of the hemorrhoidal mass in various places by means of the electric needle, as advocated by Kelsey, has been of some assistance in reducing the size of internal hemorrhoids, but never entirely removes them.



INJECTION TREATMENT.—The “injection treatment,” which is the treatment usually advocated by most of the irregulars, may be applied in a number of ways. The patient’s rectum is cleansed by means of a simple enema, followed by one of saturated solution of boric acid or some other antiseptic. The hemorrhoid, which should be of the prolapsing variety and one that can be easily ex-

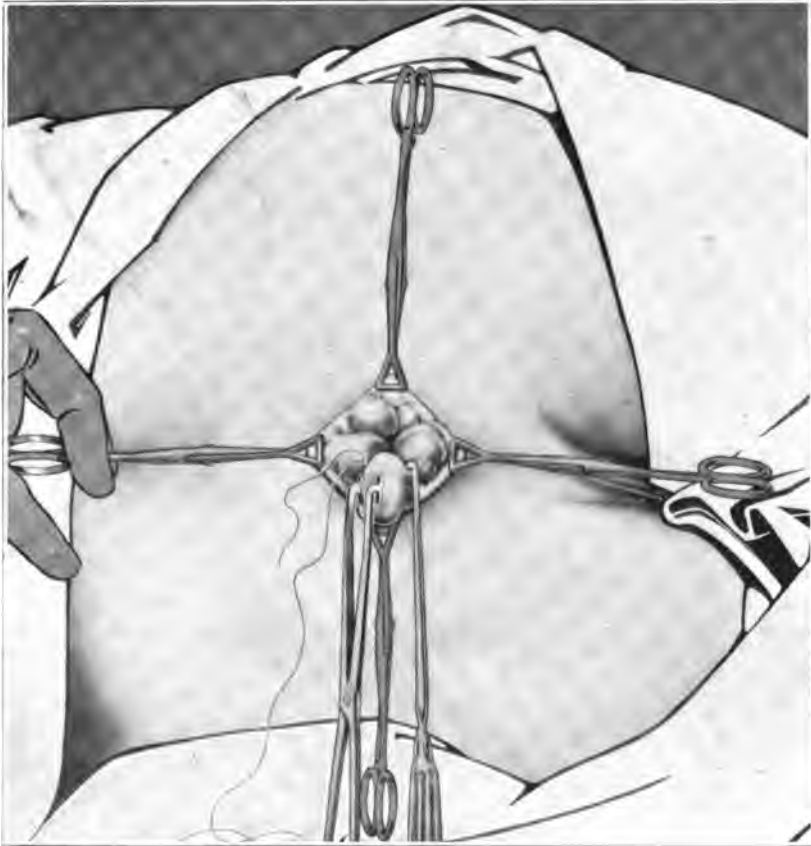


Fig. 146.— Passing submucous ligature.

truded into the anoscope, or outside, is injected down to its base with either a mild solution containing carbolic acid up to 5 or 10 per cent, when one wishes to cause a mild inflammation and gradual occlusion of the blood-vessels by the deposition of fibrous tissue, or a strong solution of carbolic acid running from 20 per cent to 50

per cent, when one wishes an immediate slough of the hemorrhoidal mass. [www.libtool.com.cn](http://www.libtool.com.cn)

When one has but one or two, or not to exceed four, prolapsing hemorrhoids, this method may be applicable, each hemorrhoid being injected at the time. In some cases two or three injections are

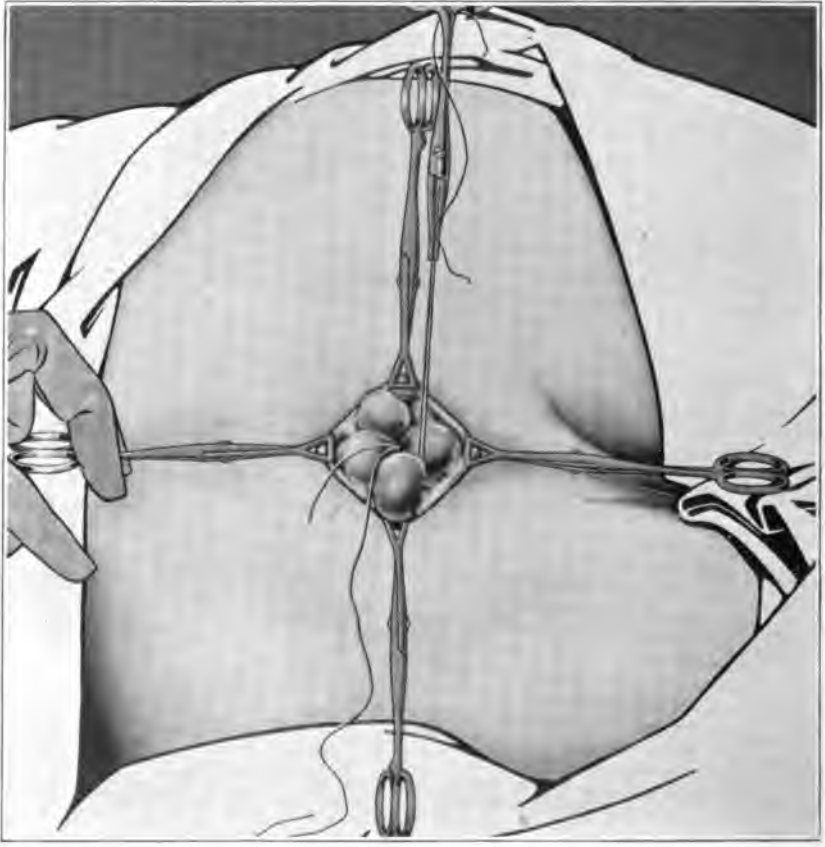


Fig. 147.—Ligature tied with a long and a short end.

necessary for each hemorrhoid at intervals of five or six days, but on account of the danger of injecting a blood-vessel, and on account of the inability to limit the slough caused by carbolic acid, it is rather *an unsafe method*; and repeated instances of destruction of large areas of tissue, and sepsis, have been reported.

A rather ingenious method of applying the injection treatment has been advocated by Franck, of Berlin. He employs a 50 per cent solution of carbolic acid in alcohol, and uses it as follows: The hemorrhoid is rendered tense by the application of a wire snare around its base; this is gradually tightened so as to cause the tumor



Fig. 148.—Rectal retractor modified from Sims' speculum.



Fig. 149.—Author's blunt-pointed ligature carrier.

to be slowly congested; the needle is then planted in the center of the mass, and several drops of the solution slowly injected. The snare is not removed until the whole mass has undergone thrombosis. Each time it is treated in a like manner, and a dressing of some drying powder is applied. In seven or eight days the necrotic

tissue will slough off, and the granulating surface will be healed in three or four days. This long period of granulation is another objection to the application of the injection method.

The best and safest of the injection treatments is the use of 5-10 per cent solutions of quinin-urea hydrochlorid as advocated by

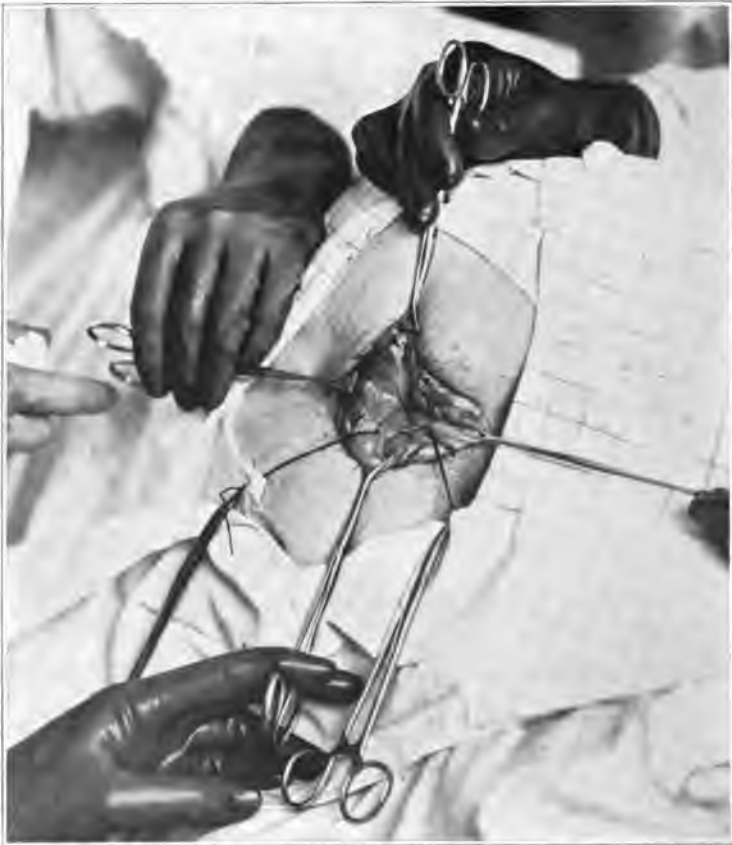

Fig. 150.—All ligatures tied in situ.

E. H. Terrell of Richmond, Va. From 5 to 20 drops of the solution are injected well into the center of each hemorrhoid, not more than one or two at a sitting. The patient returns daily until all are injected. The hemorrhoids gradually shrink, until at the end of two or three weeks they have almost disappeared.

The contraindication to the use of the strong quinin-urea solutions in anesthesia—the interference with circulation—is here employed as a curative agent.

With the introduction of local anesthesia in the radical treatment of anorectal diseases, the field for the injection method has been greatly encroached upon. It seems to the author much more rational to remove the hemorrhoid by a clean-cut surgical incision, under local anesthesia, and have the patient up and about on the second day, and the wound healed in from a week to ten days (this

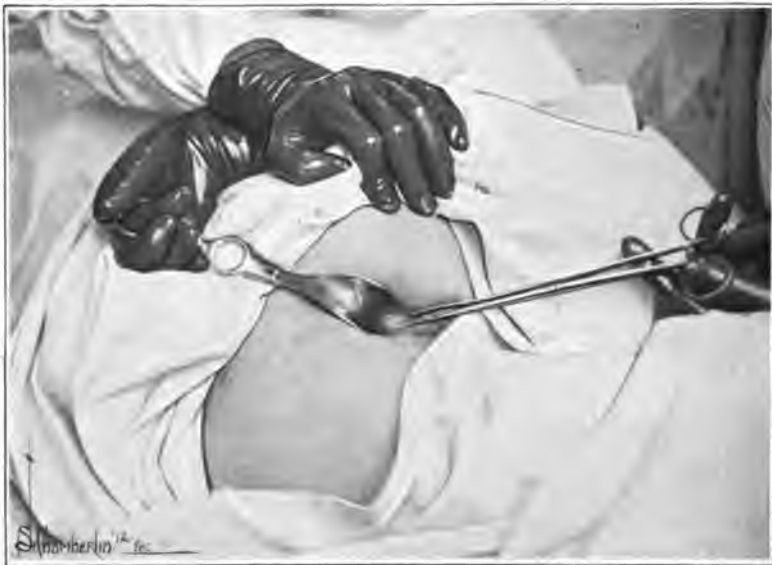

Fig. 151.—Internal hemorrhoid anesthetized, ready to remove in grasp of author's hemorrhoidal forceps.

under local anesthesia in office practice) than to use the uncertain, unscientific injection methods. Therefore, the author will confine himself in this chapter to a description of the various methods of operating on hemorrhoids under local anesthesia, as applicable in office practice.

**Operative Treatment Under Local Anesthesia.**—The technic of producing local anesthesia is, briefly, as follows (Chapter XV):

The patient, who has previously had a boric-acid enema, is placed on the table in the Sims position. A large glass hypodermic syringe

is filled with the solution of choice, which may be apothecin, procain, quinin and urea hydrochlorid, cocain, eucain, alypin, novocain, chloretone, or simple sterilized water, as the case may demand. Aposthesin  $\frac{1}{2}$  per cent or beta-eucain lactate, any strength varying from  $\frac{1}{2}$  to  $\frac{1}{10}$  per cent, is used for anesthetizing the sphincter and is injected in the following manner:

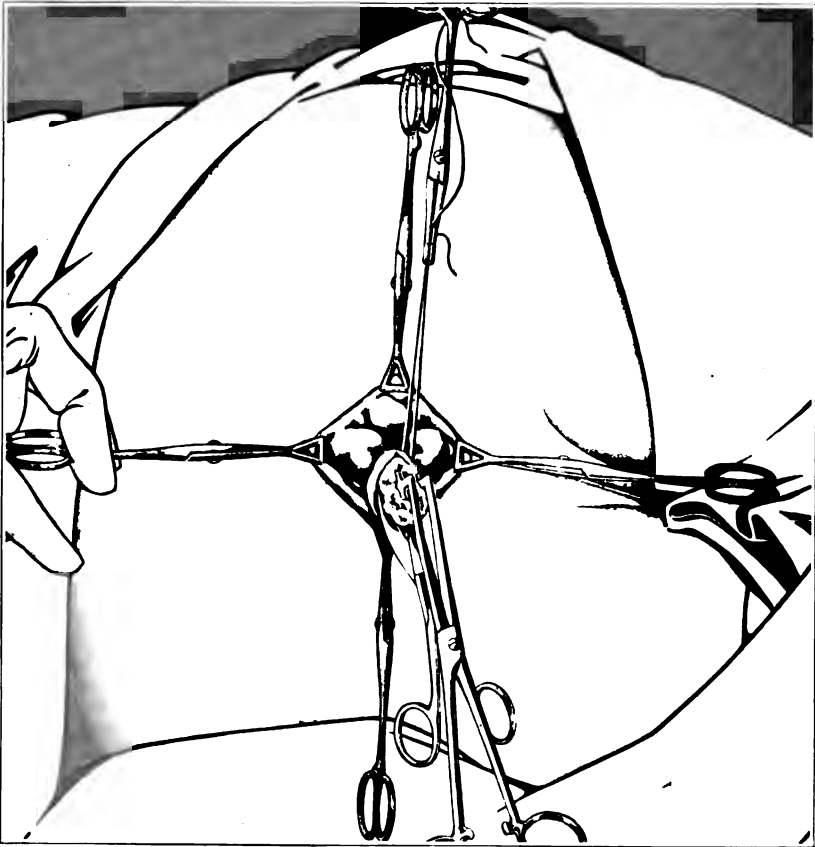


Fig. 152.-Excision of hemorrhoidal tissues, conserving mucosa.

After sterilizing the parts, a point one-half inch below and posterior to the posterior commissure of the anus is selected. The application of a swab dipped in pure carbolic acid is used to deaden the pain which accompanies the introduction of the needle (Fig.

82). With one index finger in the anus, hooking down the sphincter the needle, in the other hand is passed inward, upward, and laterally, in a V-shaped direction for about three fourths of an inch, going down into the sphincter muscle, but not through it. From ten drops to a dram of the solution is slowly injected, and the needle is retracted to the point of puncture, but not withdrawn; then it is pushed up on the other side in the same manner, keeping about one-half inch away from the anal aperture (Fig. 190).

Then at least five minutes are allowed to pass to give the anes-

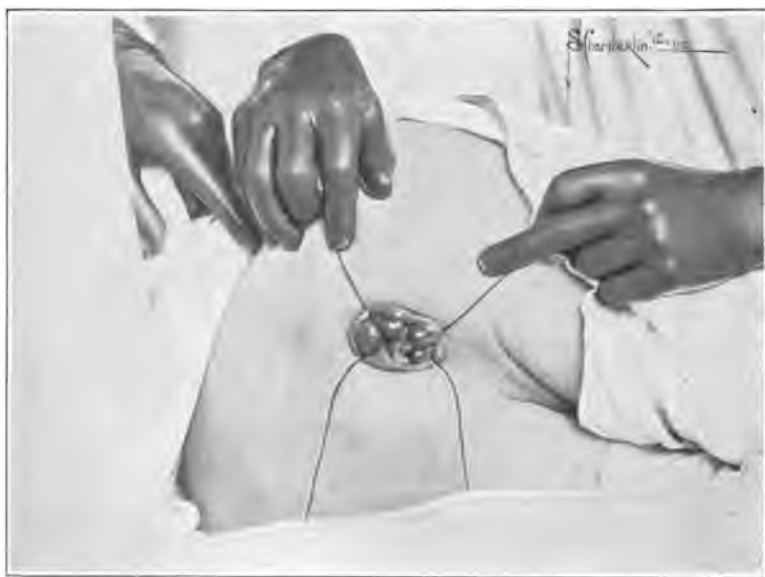

Fig. 153.—The blood supply of all hemorrhoids controlled by four ligatures.

thetic time to take effect. The sphincters will then be found sufficiently relaxed and dilated for any ordinary rectal operation (Fig. 137).

When the sphincter is dilated, the hemorrhoid is injected from its base to its apex, with  $\frac{1}{2}$  per cent solution of quinin and urea hydrochlorid. The particular point to remember is that distention must be carried until the tissues are blanched and the hemorrhoid is in appearance not unlike a Malaga grape (Figs. 138, 139, 140, 141).

It is very seldom necessary to ligate any vessels, as their retraction very soon causes the hemorrhage to cease.

The operation is then proceeded with according to the technic outlined below.

A suppository, containing three grains of thymol iodid, two grains of chloretone, and five grains of quinin and urea hydrochlorid, may be inserted if desired, and a dressing applied, but the

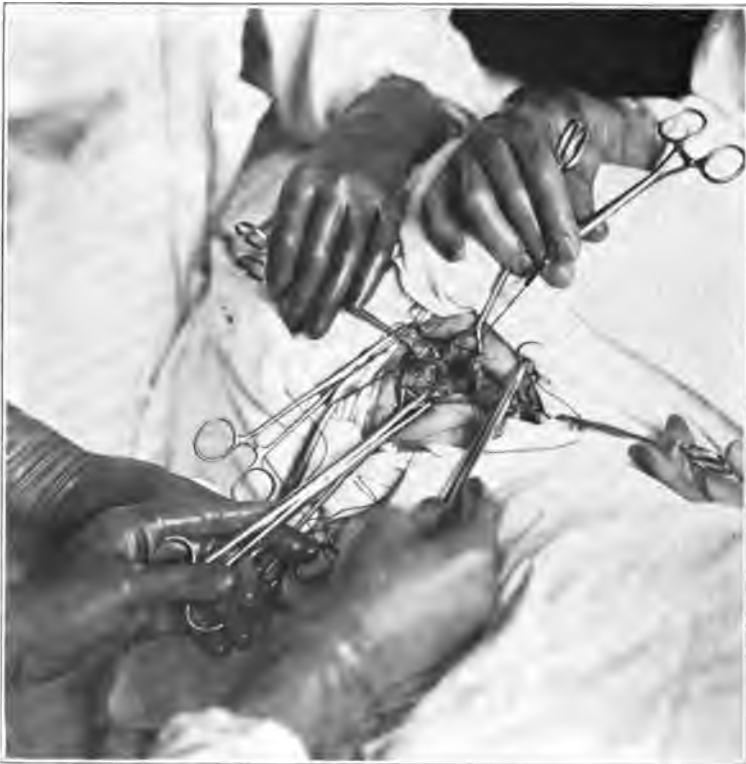


Fig. 154.—Long end of ligature tied in needle.

patient is not allowed to get up from the table for about ten minutes, then is asked to rise slowly and either sit down or lie down as he wishes. I have found that, when a patient is allowed to get up immediately, some dizziness or faintness is complained of, and I formerly attributed it to the chemical anesthetics injected, until I found that it also occurred in those patients in whom sterile water alone was used as an anesthetic.



**EXCISION.**—The hemorrhoid having a pedicle is injected at its base (Fig. 142) with  $\frac{1}{2}$  per cent solution quinin and urea hydrochlorid—the distention carried to blanching of the tissues, the base transfixed with a double-threaded needle (chromic catgut being used), and the ligature double tied. The hemorrhoid is then cut off, leaving sufficient stump to prevent slipping of the ligature. Each one is treated in like manner, a suppository of the composition men-

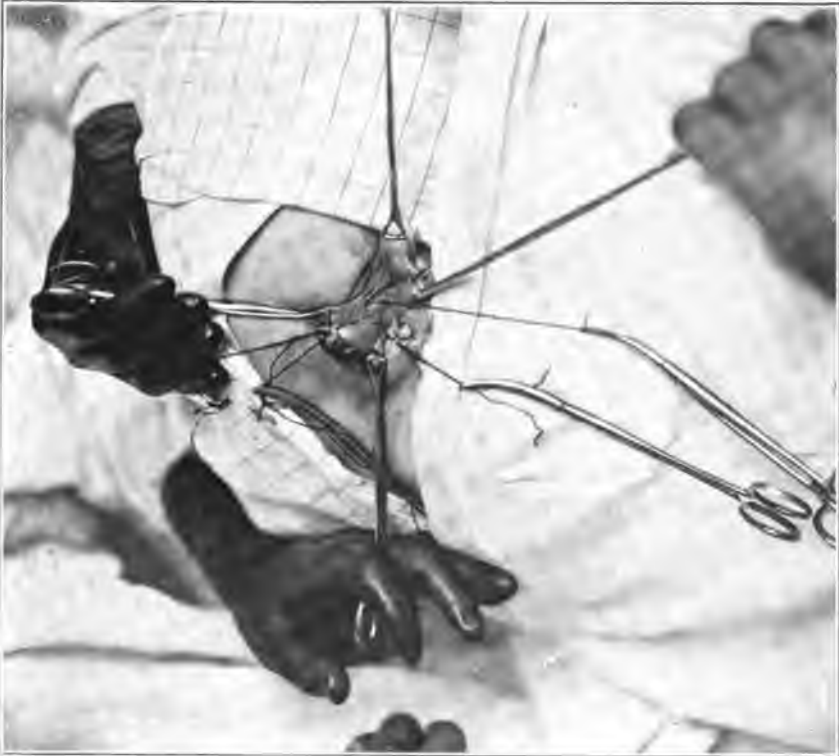


Fig. 155.—All hemorrhoids ligated and ligatures ready to be used as sutures.

tioned above inserted, the bowels kept from moving for two or three days, and the patient allowed to be up and around after the first twenty-four hours. The patient is sent home usually in a taxicab (occasionally they will walk or take the car), and is advised to lie on either one side or the other for twenty-four hours and then resume his occupation. It is surprising with how little discomfort they are able to get around and how quickly they recover.

The hemorrhoid, which is sessile or non-pedunculated, is distended in the same manner as above. The most dependent portion is grasped with the author's pile forceps (Fig. 144) or toothed forceps; it is dissected up from its base with either knife or scissors to healthy tissue, care being taken to include in the dissection the vessels which enter the hemorrhoid from above. The upper part of the flap is transfixed and tied off, as is the pedicle in the above variety, when the tumor is cut off with the scissors; others treated in like manner, and the after-treatment is the same as above. It is a very

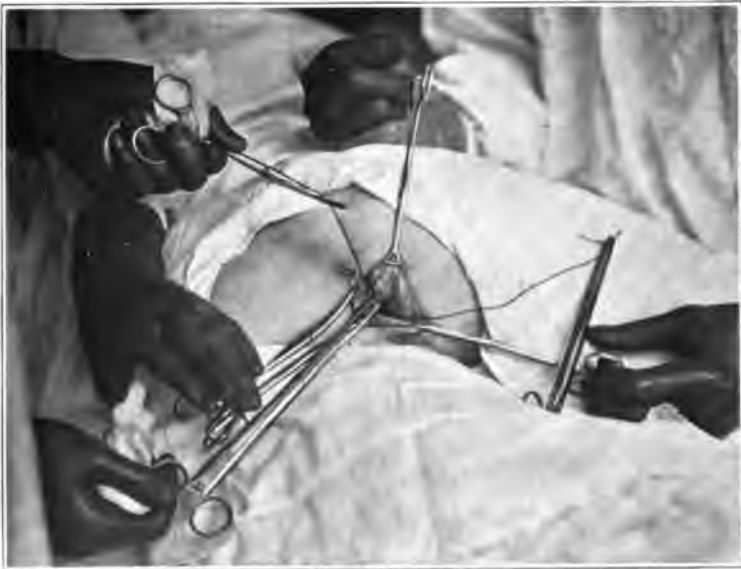

Fig. 156.—Long ends of ligatures tied to their respective short ends, drawing wound edges together.

rare thing for the author to have hemorrhage severe enough to require ligation of the vessels. Where there is more or less oozing, a piece of rubber-tubing, about four inches long and surrounded by gauze, is inserted, and the pressure of the gauze against the raw surface very soon checks oozing. This is removed in anywhere from one to twenty-four hours.

**AUTHOR'S BLOODLESS OPERATION.**—A somewhat simple method is the author's technic for the removal of most all forms of internal hemorrhoids without the profuse hemorrhage with which this oper-

ation is usually associated in the minds of most medical practitioners. From the observation that most patients suffering from hemorrhoids of the internal variety are more or less anemic from the continued and constant loss of blood, as a result of their hemorrhoidal trouble, he decided to use a technic that would minimize operative hemorrhage and conserve the patient's blood supply. With

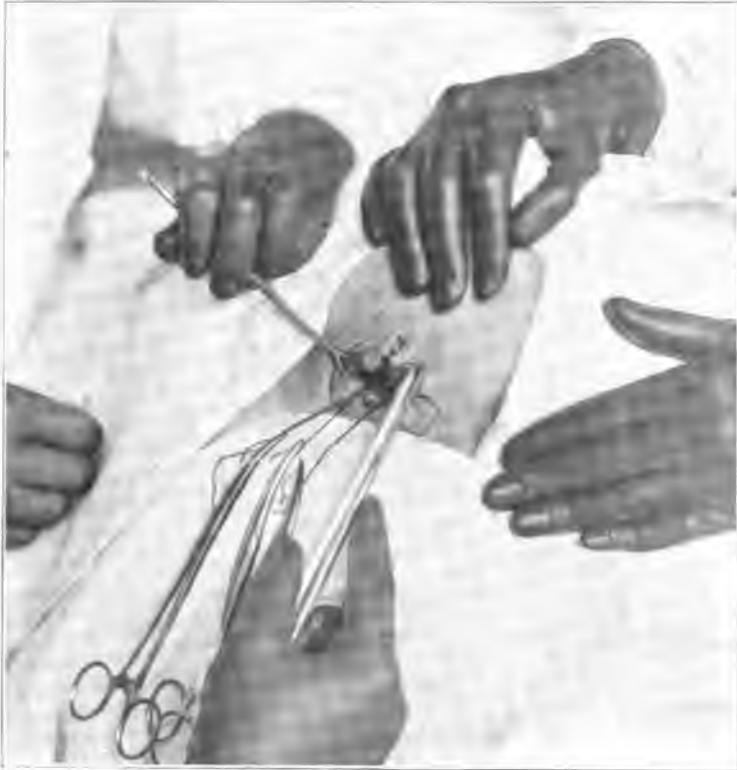

Fig. 157.—Edges in position for suturing.

this aim in view, he has developed and has been using a very simple technic which is presented below:

It is applicable under local as well as general anesthesia, and therefore can be used in those weak, run-down patients suffering from any of the wasting diseases, in whom the use of a general anesthetic would be inadvisable, if not positively dangerous. The method

is applicable to any variety of internal hemorrhoids, and particularly to the pedunculated and prolapsing varieties. Interno-external hemorrhoids can also be treated by this method. Very few instruments are required, and in most cases dilatation of the sphincters is not required. The technic under general anesthesia is much the same as under local anesthesia, and inasmuch as local anesthesia is

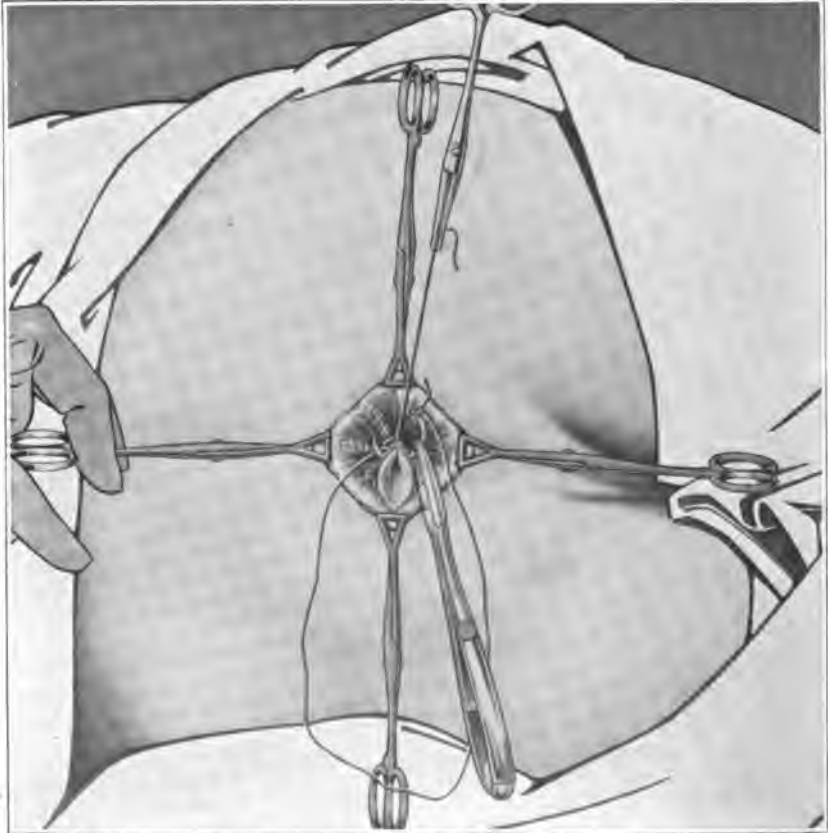


Fig. 158.—Technic of suturing.

a good deal safer and fully as satisfactory as general anesthesia for this work, the author will describe the operation as performed by him under local anesthesia.

The instruments required are four to six Pennington triangular forceps or a rectal retractor (Fig. 109) or Sims' speculum; the

author's blunt-pointed ligature carrier, the author's pile forceps, scalpel, sharp-pointed scissors, curved on the flat, aseptic hypodermic syringe with sharp needle, and chromic catgut. The patient is given one-fourth grain of morphin and  $\frac{1}{150}$  grain of hyosein about a half-hour before the operation is performed; the bowels are washed out with a soap-suds enema, followed by a boracic acid enema. He

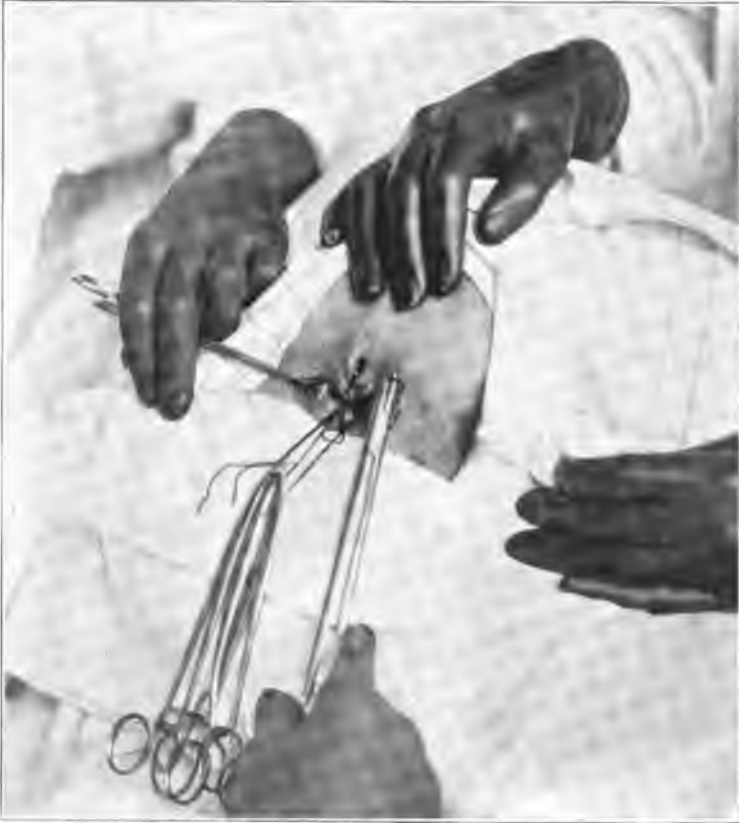

Fig. 159.—Completing the suturing.

is then placed on the operating-table in the Sims lateral position; the skin around the anus is scrubbed, shaved, and sterilized. The sphincters are then anesthetized by the injection of 20 to 30 minims of  $\frac{1}{2}$  per cent solution of apothecin or  $\frac{1}{4}$  per cent beta-eucain lactate solution, which has been sterilized by boiling, according to the technic described above.

The skin surrounding the entire anal circumference is injected as well, so as to allow the grasping at four equidistant points with the Pennington triangular forceps. This gives us, on gentle traction, the best exposure of the operative field, that it is possible to procure (Figs. 143 et seq.).

When relaxation and exposure have been accomplished, the most dependent hemorrhoid is injected with  $\frac{1}{2}$  per cent solution of quinin and urea hydrochlorid, and the distention carried until the tissues are blanched. Anesthesia is then complete. The lower extremity of the hemorrhoid is then grasped with the author's pile forceps (Figs. 144, 145) and pulled down so that it is on the stretch. The blunt-pointed ligature carrier, threaded with No. 2 catgut, is passed in through the mucous membrane on one side, down to the base of the hemorrhoid and around to the opposite side, in such a manner as to include the upper half of the mucous membrane covering the pile, and the blood-vessels underneath, but not encircling the entire hemorrhoid as in ligating a pedicle (Fig. 146). This ligature should be placed just at or above the juncture of the pile and the healthy mucous membrane of the rectum. It is then firmly tied (Fig. 147), and it will be found that the blood supply of the pile has been included in the ligature and shut off (Fig. 150). The piles at either side are treated in like manner and lastly the upper ones. A suppository containing:

Chloretone .....	gr. ij
Thymolis iodidi .....	gr. ij
Quininae hydrochloridi carbamidati.....	gr. x

is inserted, the patient keeping in the recumbent position for ten minutes, and then allowed to rise from the table and go to his bed. If there should be considerable swelling during the first twenty-four hours, this, with its accompanying pain, can be relieved by the application of hourly compresses soaked in the following solution:

℞ Adrenalin chlorid (1:1000).....	ʒss
Chloretone .....	gr. xxx
Glycerini .....	ʒiv

The swelling subsides in from two to four days, and the pile gradually shrinks until at the end of four weeks there is nothing left but a little hard "nub" of connective tissue, which can then be re-

moved painlessly with the scissors. This, which is the simplest form of technic, is applicable in those desperate cases of anemia where the continual loss of blood from the hemorrhoids is greater than the patient's blood production. It can be done in ten or fifteen minutes and involves the least expenditure of nerve endurance and suffering of the patient. In cases where the necessity for haste is not quite so imperative, and these cases are the great majority, I use the following modification of the technic:

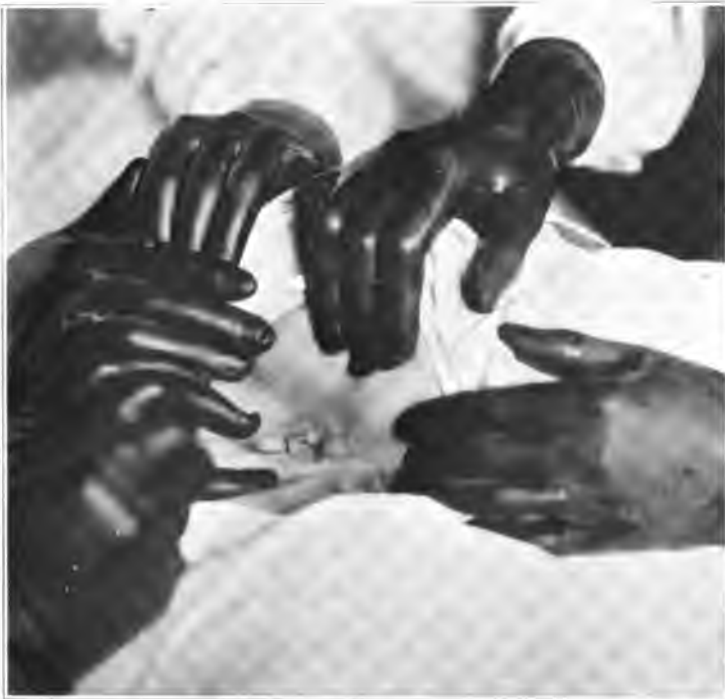

Fig. 160.—Skin closure.

After the hemorrhoid is anesthetized as above, and the ligature applied in the same manner, the pile is grasped in the author's pile forceps, and an incision made in its longitudinal axis, and extending down to its distal extremity; then, with the curved scissors, the blood-vessels and connective tissue which make up the body of the pile are dissected out *en masse* (Fig 152) and cut off about one quarter of an inch from the ligature. The wound is left open to

heal by granulation, which it does in a very few days. This dispenses with the hemorrhoid at once and does away with the swelling, pain, and discomfort which necessarily follow the preceding technic.

In cases where we have pedunculated, prolapsing hemorrhoids, it is not necessary to dilate the sphincter or use the retractor. Following an enema, the patient is asked to strain while in the squatting position or lying on his side, while the operator is everting

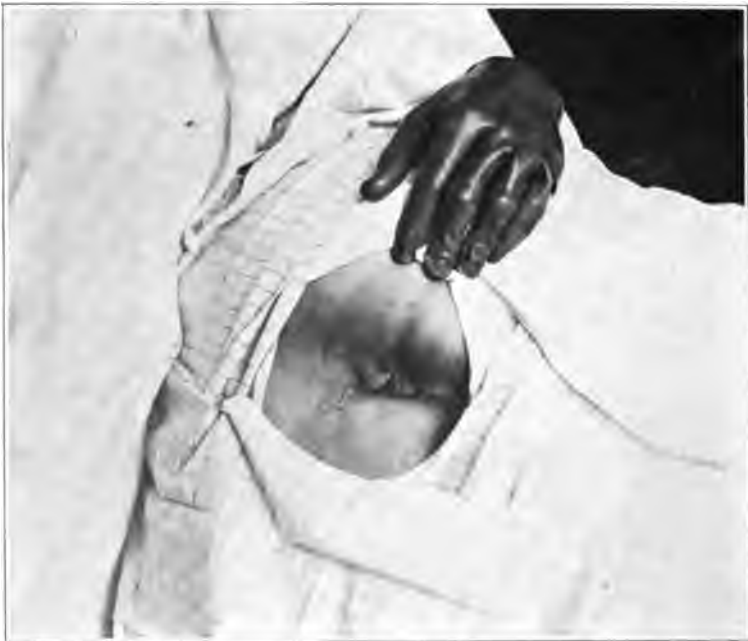

Fig. 161.—Operation completed.

and pressing back the sphincter muscles by pressure just outside the outer margins of the external sphincters. The pile which is prolapsed by this method is injected with 1 per cent solution of quinin and urea hydrochlorid. Its pedicle is transfixated with the blunt ligature carrier double threaded with catgut, and tied off in two sections. The pile is then cut away one quarter of an inch from the ligature, and the stump cauterized with 95 per cent carbolic acid. The other pedunculated hemorrhoids are treated in



like manner, the analgesic suppository inserted, and the operation is completed. [www.libtool.com.cn](http://www.libtool.com.cn)

Modifications of this technic include the substitution of the rectal retractor (Figs. 148, 151) for the triangular forceps in the exposure of the hemorrhoids; also the using of the long end of the ligature as a suture for closure of the incisions (Figs. 147, 150, 152, 154-161). This is sometimes done for hemostatic reasons in hemophilics, or others where there is more than the usual amount of oozing.

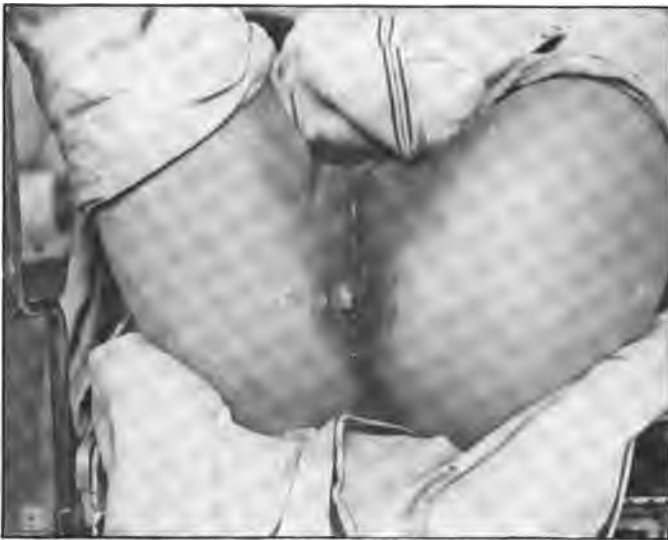

Fig. 162.—Distention of external hemorrhoids with sterile water. This photograph is taken from the same case as Fig. 67, and comparison of the two will be of interest.

The after-care is very simple, the bowels being confined for two or three days. A dram of compound licorice powder at night, followed by a six to ten ounce soap suds or oil enema in the morning, will produce an easy and satisfactory movement at the end of that time. A tablespoonful of liquid petrolatum, daily before retiring, will keep the bowels in good order, and daily soft movements will follow. The only dressing required is a powder, such as compound stearate of zinc, which should be applied sufficiently often to keep the parts protected. Some of the many advantages of this method are as follows:

1. The technic is simplicity itself.
2. It is applicable under local anesthesia.
3. It takes a shorter time than any other method which successfully disposes of the hemorrhoid.
4. It is surer, safer, and quicker than the "injection method," and is applicable in every case where the injection method can be used, as well as in other varieties of hemorrhoids where the injection is contraindicated.
5. It should be the method of choice in all patients suffering from anemia, tuberculosis, hemophilia, and in pregnancy—because of all the foregoing reasons, and the fact that it does not involve the loss of blood. The principle of tying before cutting reduces the waste of blood to a minimum, and makes for rapid convalescence.
6. There being no confinement in bed after the first twenty-four hours, the patient may be up and about, going out of doors, getting fresh air, sunlight, and exercise, which are nature's best curative agents in convalescence after any operation or disease, and of the greatest value to patients suffering from any of the wasting diseases mentioned above.

**SUBMUCOUS EXCISION.**—In the sessile variety, another way of treating these is simply to make an incision in the longitudinal axis of the bowel through the center of the mass, and then by the use of the author's angular rectal scissors (Fig. 62) to macerate and destroy the blood-vessels, beneath the mucous membrane on either side of the incision. The blood supply being destroyed and the macerated tissue cleaned out with a curette, the wound is allowed to heal without suture, and usually does in four or five days. Of course, this method is accomplished by some hemorrhage, but never severe enough, however, to require ligation. The after-treatment is the same as in the other varieties.

**CLAMP AND CAUTERY OPERATION.**—The clamp and cautery operation is not applicable, of course, under local anesthesia, and I mention it merely to condemn it. I do not believe that the use of a red-hot iron in a cavity lined with mucous membrane is rational, and while I am aware that many surgeons have used it with many successful results, I have seen strictures following its use which were caused by the overgrowth of scar tissue—which

is more prone to follow a burn than any other form of wound. A clean-cut surgical incision, to my mind, is more rational and is not followed by the extensive sloughing or the extensive cicatrix. Crushing the hemorrhoid with the angiotribe has also been used by some operators, and offers the objection that it destroys too much mucous membrane and is followed by a more or less chronic granulating surface taking weeks to heal.

**WHITEHEAD OPERATION.**—The Whitehead operation is, in the author's opinion very seldom, if ever, indicated.

**OTHER METHODS.**—Other methods of disposing of large redundant hemorrhoidal masses by means of elliptical flaps, longitudinal incisions, and plastic work are used to obviate the necessity of doing any operation, which is almost certain to be followed by sepsis, retraction of flaps, and subsequent cicatricial contraction. The author has yet to see a case of hemorrhoids accompanied by prolapse so severe that he has not been able to remedy it without sacrificing the normal contour of the anus.

**REMOVAL OF ACUTE THROMBOTIC HEMORRHOIDS.**—The acute thrombotic variety (Fig. 124) is peculiarly amenable to treatment under local anesthesia. On account of its sudden onset and the acute suffering which it produces, the patient will present himself for treatment within a few hours after its onset. Examination in the lateral position shows a rounded, bluish or purple tumor, varying in size from that of a pea to a large grape, located just at the anal margin, usually on one side. It usually occurs singly. After the usual preparation, the hemorrhoid is injected from its outermost aspect with 10 or 12 drops of  $\frac{1}{2}$  per cent solution of apothesisin or eucain lactate—the injection being carried just underneath the skin or mucous membrane, and not down into the pile. After allowing five minutes for the anesthetic to take effect, an incision is made through the skin and down to the clot, parallel to the long axis of the anus and extending for about one quarter of an inch into the skin beyond the tumor. The tissues around the tumor and below it are again injected, when it is dissected out by means of a small-toothed forceps and the curved scissors. After the clot (Fig. 127) is removed, look carefully into the wound to see whether a second clot has formed below, and if so, it must be removed at the same time. The edges of the wound are trimmed

back in an elliptical manner, so as to leave a gaping wound, which will heal by granulation from the bottom, without any possibility of the edges of the wound turning in and retarding its healing. A one-half-inch strip of tape or gauze may be lightly inserted into the wound, and a sterile dressing applied. This gauze is removed in twenty-four hours, when it will not be found necessary, as a general rule, to re-dress the wound. It should be seen and dressed daily, and some mild antiseptic powder may be applied, such as thymol iodid, boric acid, boro-chloretone, stearate of zinc, or acetanilid. The patient, immediately after this operation, experiences a keen sense of relief from the removal of the tension caused by the thrombotic mass.

**REMOVAL OF EXTERNAL INTEGUMENTARY HEMORRHOIDS.**—The removal of external hemorrhoids of the integumentary (Fig. 67) variety is very easily accomplished under local anesthesia. After the parts are cleansed, shaved, and sterilized, with the patient placed in the left lateral or lithotomy position, the most dependent pile is selected, the point of puncture touched with a drop of pure carbolic acid or sprayed with ethyl chlorid until the tissues are blanched, when the spray is removed, and as soon as it has regained its natural color the injection is made. As in all operations involving the skin, the first injection should be of  $\frac{1}{2}$  per cent solution of apothecin or eucaïn lactate, care being taken to inject the first ten or fifteen drops just underneath the skin along the line of the proposed incision so as to form a wheal or welt. An incision is then made on a line radiating at right angles from the anal orifice to the distal extremity of the tumor; then the subcutaneous tissues are infiltrated with  $\frac{1}{4}$  per cent solution of the anesthetic used or sterile water. The hemorrhoidal mass is then seized with the author's hemorrhoidal forceps and removed with flat curved scissors. The skin edges are trimmed back on either side in the shape of an ellipse, so as to include all of the redundant tissue which forms the covering of the pile. One must be cautious about cutting away too much skin. The distention with the anesthetic solution somewhat distorts and distends the skin, and the infiltration extends beyond the part to be removed, making it appear much larger and extensive than it is in reality (Fig. 162). It is a wise plan, therefore, to carefully mark out, before pro-

ceeding to operate, the extent of the proposed incision by means of a small swab moistened with silver nitrate. Each hemorrhoid is treated in like manner, working from below upward, and the wound is allowed to heal by granulation. There is no objection to putting a couple or silkworm stitches in each wound, if desired; but the author has found healing fully as satisfactory without stitching, and the time of operation is materially lessened, which is an important factor in all work under local anesthesia.

The after-care is similar to that outlined in the treatment of acute thrombotic hemorrhoids. The healing following the operation for external hemorrhoids should be complete in a week or ten days.

During the healing process, the patient should be required to use an inflated air cushion, or pillow, when sitting, and to lie upon either side rather than upon the back. As has been stated above in the treatment of internal hemorrhoids, it is wise to put the patient upon a light diet, consisting of meat-broths, and strained vegetable soups, with the addition of eggs and gelatins, for the first three or four days. The bowels should be confined until the third day, when by means of a dram or two of licorice powder given the night before, followed in the morning by a suds or ten-ounce oil enema, the bowels should be moved. The movements thereafter should be kept soft by the administration of half-ounce doses of white refined petroleum oil daily at bedtime, and the diet gradually increased. After the first movement, daily evacuation of the bowels should be secured.

**REMOVAL OF INTERNO-EXTERNAL HEMORRHOIDS.**—The same technic as outlined for the removal of internal hemorrhoids above is to be followed in the case of the combined varieties. The infiltration is carried out so as to include the external tumors, and the incisions extended likewise. The after-care is also identical.

## CHAPTER XI

### RECTAL POLYPI—HYPERTROPHIED ANAL PAPILLÆ—CRYPTITIS

#### **POLYPUS**

A polypus is a non-malignant tumor, whose chief characteristic is its attachment to the rectal wall by a pedicle, which is always narrower than the tumor (Figs. 163, 164). It occurs more often in children than in adults. Polypi may be found singly or in such large numbers as to entirely fill the rectal cavity or whole colon (Figs. 165, 166) and will be found complicating anal fissure, hemorrhoids, prolapse, and other rectal diseases.

The usual location of a single polypus is in the lower end of the rectal canal from one to two inches from the anal opening. Rarely cases have been seen in which the polypus was found attached by a pedicle four or five inches long as high as the rectosigmoidal juncture.

The types of polypi most commonly seen are either the soft myxomatous or adenomatous variety, or the hard fibroid polypus. In appearance, the soft granular polypus resembles a raspberry, and bleeds readily at the touch. The fibroid variety is hard, rounded, and lighter in color than the normal rectal mucous membrane.

**Symptoms.**—The usual symptoms, outside of the appearance of the polypus itself, are the passage of blood and mucus, and straining efforts after stool—the patient complaining of a feeling as if more fecal matter were in the rectum, but it was impossible to evacuate it.

**Diagnosis.**—The diagnosis is very simple, as they are often discovered protruding from the anus. A peculiar characteristic of polypi is the snapping sensation which they give to the finger as they are returned to the rectum. On making a digital examination, with the patient in the lateral position, one should insert the finger as high as possible, and then sweep it from side to side,

completely encircling the rectum on its withdrawal, when the polypi will be discovered, usually just above the internal sphincter. As the finger is withdrawn, the polypi can often be brought with it, outside the sphincter. By means of proctoscopic examination, polypi situated higher in the rectum may be discovered.

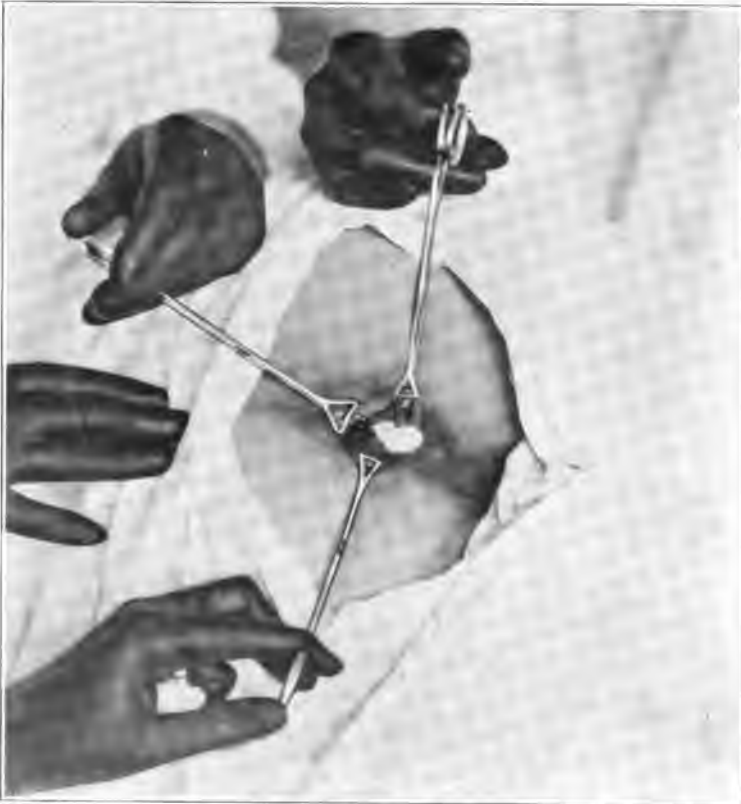

Fig. 163.—Anal polypus.

**Treatment.**—In the treatment of polypi, local anesthesia is often not necessary. They can be snared off with ease through the anoscope or proctoscope with little or no pain. Where a polypus is situated low, so that it can be extruded through the anus, the pedicle may be infiltrated with  $\frac{1}{4}$  per cent solution of apothecin or eucain, or  $\frac{1}{2}$  per cent quinin and urea hydrochlorid, transfixed

with a double-threaded needle, and the pedicle tied off in two sections with ~~va double~~ **double ligature**. The polypus is then snipped off with scissors, leaving as little stump as is possible. It is practically never necessary to anesthetize the sphincter, and no after-treatment is required.

### HYPERTROPHY OF THE ANAL PAPILLÆ

In devoting ~~some~~ space to the anal papillæ, the author has done so with the view of bringing before the profession a condition

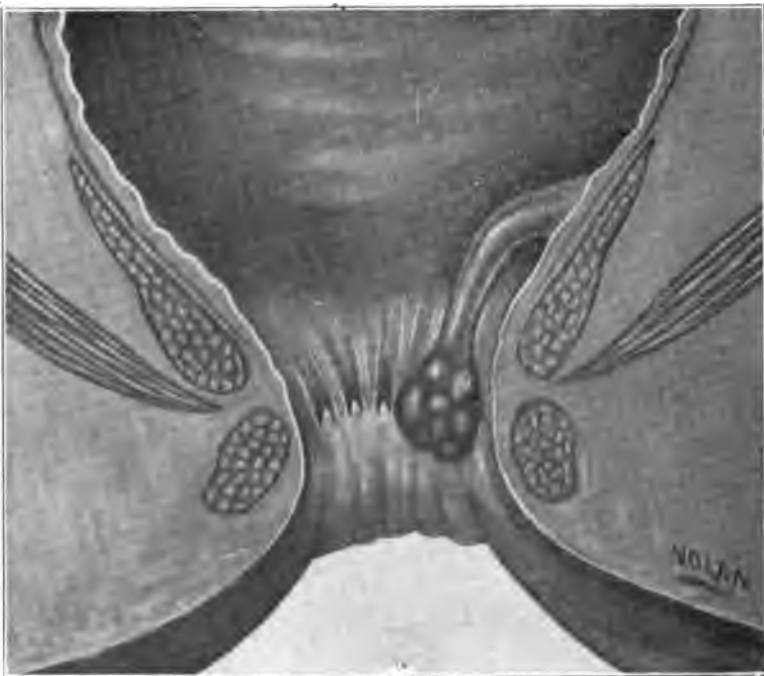


Fig. 164.—Rectal polypus.

which is practically never recognized by the general practitioner, and usually overlooked by the general surgeon, who includes rectal surgery as an *incident* in his practice. It is one of the many minor conditions which originate in the anal canal, which, while never causing such serious symptoms as to endanger health or life, or causing such great suffering as to incapacitate the patient



from his daily occupation, nevertheless, is of no small interest to the medical practitioner because of the amount of discomfort it causes.

This may amount only to a feeling of uneasiness, but the hypertrophied anal papilla is often responsible for symptoms ridiculously out of proportion to the size and severity of the lesion.

Many irregular practitioners, who hold themselves out as "rectal specialists," have made great capital out of the anal papillæ and have attributed to them the causation of nearly every disease in the calendar. As a result, many of the profession have gone to the other extreme, and have completely ignored the existence of what has been proved to be definite diseased conditions of definite anatomical entities.

When a patient complaining of indefinite rectal or anal symptoms consults his physician, too often he is dismissed with some proprietary ointment, without any effort being made to locate the cause of the trouble. The special study of the rectum, with its allied organs, the anus and the sigmoid, has brought to view many interesting conditions which have been overlooked in the past, and it is with the view of clearing up some of the obscure and indefinable symptoms which originate in the region of the anus, that the author is devoting this space to hypertrophy of the anal papillæ.

It is in the anal canal, where most of the pathological conditions which cause pain and suffering, and reflexes without number, originate. Nature has been unusually lavish in her sensory nerve supply to these organs, and lesions in this region produce referred disturbances in many other and remote organs. When one considers that the anal canal measures from two-thirds to an inch and a quarter in length and its circumference about one and one-quarter inches in the contracted condition, one can readily see that it is not a large area to examine and study, and diseased conditions in this region should not be difficult to discover, diagnose, and remedy.

The anus is peculiarly susceptible to injury and disease. First, because its lining membrane, being neither skin with its tough resisting power nor mucous membrane with its generous vascular supply, but a sort of transitional tissue, neither one nor the other, is easily injured. Secondly, any lesion occurring in this region

[www.libtool.com.cn](http://www.libtool.com.cn)

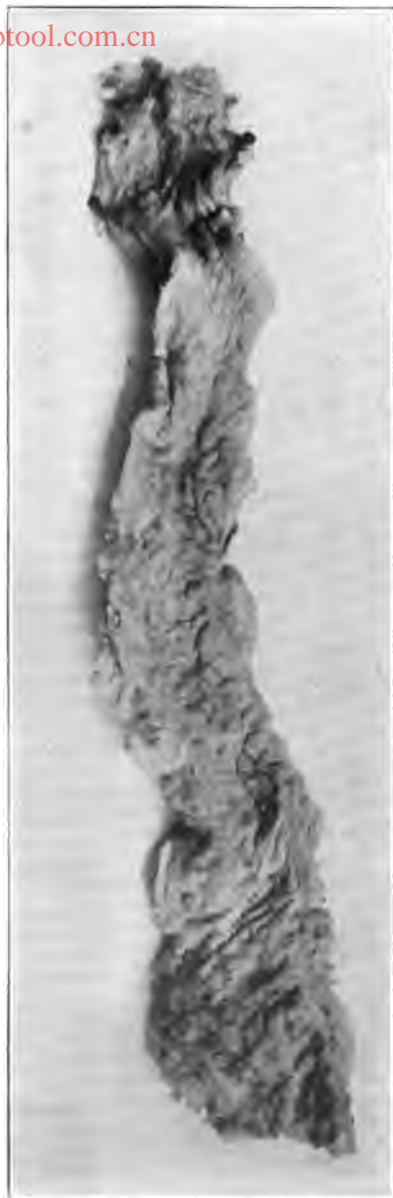

Fig. 165.—Specimen from partial colectomy for multiple colonic polyposis.

[www.libtool.com.cn](http://www.libtool.com.cn)

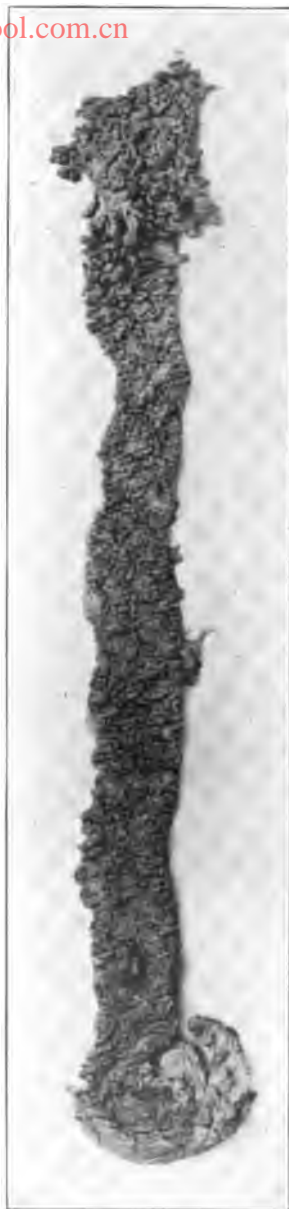

Fig. 166.—Specimen from total colectomy for multiple polyposis.

has a small chance of recovery because of its meager blood supply, and ~~its constantly changing~~ position, and because of trauma and infection from the contents of the bowel which are constantly passing over it.

In order to understand more intelligently the condition under discussion, it might be well to say a few words about the normal

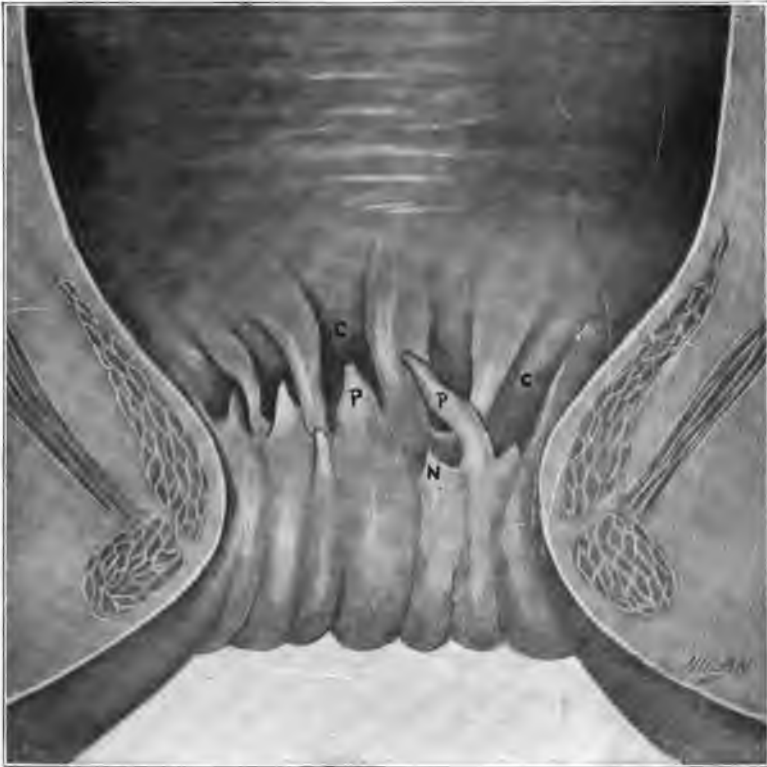

Fig. 167.—Sectional view of the anal canal showing hypertrophied anal papillæ and crypts of Morgagni.

C. Opening of crypts of Morgagni.  
 P. Hypertrophied papillæ.  
 N. Normal papilla.

anatomy of the anal papillæ (Fig. 164). These papillæ occur as an irregular line of small saw-tooth-like projections encircling the point of the juncture of the anus with the rectum, sometimes called the *linea dentata*. These papillæ, varying in number from five to a dozen, are usually situated at the edges of the *semilunar anal valves*

which guard the *crypts of Morgagni*. Andrews considers these papillæ the normal tactile organs of the rectum and endowed with a special rectal sense. They have an abundant nerve supply, which accounts for the many reflex disturbances which originate when they are diseased.

**Examination and Diagnosis.**—In making a digital examination, unless one is rather expert, these papillæ are not always evident to the touch, but are apt to be overlooked unless an ocular inspection is made. When diseased, these papillæ may vary in size

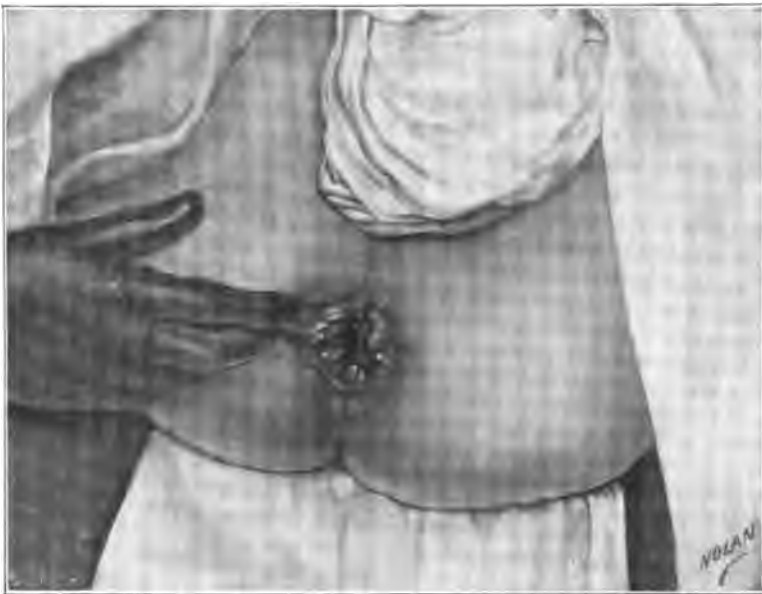

Fig. 168.—Hypertrophied anal papillæ. This well shows the appearance of the anal papillæ when the anal margin is put upon the stretch by strong traction.

from a quarter of an inch in length, by the same breadth at the base, to an inch and a quarter or an inch and a half in the longest diameter (Fig. 167). They are composed largely of an overgrowth of normal tissue. By everting the anus, the tips, and often all of the hypertrophied papillæ themselves, can be brought into view (Fig. 168). They are of a pinkish color, slightly paler than the normal mucous membrane of the rectum.

A distinguishing point between hypertrophied papillæ and polypi is the fact that the hypertrophied papilla is always wider

at its base than the apex, while the polypus is always larger than the pedicle by which it is attached. The polypus is usually rounded or oval in shape, while the papilla is more or less triangular, or ribbon-shaped. Enlarged papillæ have been incorrectly designated as connective-tissue piles. They never show the characteristic varicose appearance of the internal hemorrhoid and are attached at the anorectal line.

Containing some erectile tissue, on examination through the anoscope they will often be seen to stand out at right angles from



Fig. 169.—Proctoscopic view of an aggravated case of hypertrophied anal papillæ.

the mucous membrane, giving the anal canal at this point a fringed appearance (Fig. 169). Many a surgeon, when he can discover no pathological lesion but finds a tight sphincter, overlooks what he may call “little tags of the mucous membrane.” These are very frequently the cause of the tight sphincter, for let it be said here that no sphincter is abnormally tight unless there is some pathological lesion causing it, and a simple divulsion of the sphincter will not relieve the symptoms, as many a surgeon and patient have found to their chagrin and disappointment.

**Symptoms.**—These papillæ, being situated on the edges of the semilunar valves, are pushed and dragged downward during the passage of feces, which are more firm and harsh than normal. At each bowel movement there is a further pull and drag on the papilla, which is gradually stretched and hypertrophied. After it has become sufficiently hypertrophied, it will not retract at once after a movement, but will remain in the grasp of the external sphincter, causing the sphincter to contract. This contraction gradually becomes more tonic, and eventually we have what has been called the "tight contracted sphincter." This gives rise to one of the most characteristic symptoms of hypertrophied papillæ—that of an unsatisfied feeling after stool—a feeling as if some particle of fecal matter were still in the grasp of the sphincter and could not be expelled, also a feeling of irritation and uneasiness, short of itching. As one patient described it to me, "It felt like the bite of some small animal," and he was sure that he had a tapeworm, because he "could feel it nibbling at the anus." Another stated that it felt like a bur, held in the grasp of the sphincter. This feeling can be immediately relieved by the insertion of the lubricated finger and pushing up and replacing the enlarged papillæ which will be found in the grasp of the external sphincter. If they are left to themselves, it will often take from fifteen minutes to an hour and a half for them to gradually retract, when symptoms will entirely disappear. They cause spasm of the sphincter, and the constantly repeated spasms bring on a hypertrophy of the circular muscular fibers, forming the sphincter muscles, and the hypertrophied sphincter is the so-called "tight sphincter."

Another symptom which the hypertrophied papillæ cause is so-called neuralgia of the rectum, being transferred and transmitted pains from the pressure on the nerve-endings of the papillæ. One of the most common symptoms, however, for which hypertrophied papillæ are responsible is pruritus ani. I do not wish to be misunderstood as saying that hypertrophied papillæ are the commonest cause of pruritus ani, because the causes are legion—but they are a common and frequently overlooked cause.

**CRYPTITIS**

[www.libtool.com.cn](http://www.libtool.com.cn)

It will be remembered that each papilla is found at the edge of a semilunar valve, which semilunar valve is the outer boundary of one of the crypts of Morgagni, also known as *rectal pockets* or *mucous crypts*. These crypts, whose function is not thoroughly understood as yet, become clogged with fecal matter, which on account of the shape of the crypt or sac is not readily expelled. The enlarged anal papilla overlying the crypt assists in preventing its escape. The decomposition of this fecal matter or retained secretion, and the consequent irritation of the crypt, set up an inflammation or cryptitis, which may frequently go on to pus formation. The accumulated discharge originating here overflows from the crypt, and as it runs down the mucous membrane of the anus, sets up an irritation, which is made manifest by itching or pruritus, and the moisture complained of by many patients suffering from pruritus will be found to originate from this source.

The feeling of uneasiness following stool, of which some patients complain, is unlike that produced by any other condition. It has been described to me by one patient as a feeling as if he had thorns or pine needles in the anus—a sort of prickling sensation—not painful, but very uncomfortable; and he would find himself constantly shifting from side to side as he sat in a chair. Occasionally the shifting would relieve him, when assisted by some pressure on the anus, thus releasing the papillæ from the grasp of the sphincter.

It is not only the extremely long papillæ for which we must look to cause these symptoms, as those which are only half an inch in length, the tips of which are just engaged in the sphincter, are sufficiently enlarged to cause symptoms.

Another condition which has been found to follow the hypertrophy of an anal papilla is anal fissure. This is caused, as has been demonstrated by Wallis, of St. Mark's Hospital, London, by sufficient pressure during stool to tear the papilla downward from the edges of the crypt, and as succeeding stools continue the tearing process, the edge of the crypt is brought down to the outside of the anus, leaving in its wake a raw, ulcerated furrow (Fig. 80), which is traumatized further by each stool, and



gives rise to the many severe and intolerable symptoms attending anal fissure. [www.libtool.com.cn](http://www.libtool.com.cn)

**Treatment.**—The treatment of this condition is extremely simple and consists in the removal of the papillæ when they are enlarged and the opening and cauterization of the crypts when inflamed or infected. Both conditions are present together so often that their treatment will be considered together as well. The removal of papillæ is accomplished in the following manner:

The anoscope, or fenestrated speculum, is inserted, with the opening directed toward the lowest papilla to be removed. The papilla is injected at its base with  $\frac{1}{2}$  per cent solution of apothessin or eucain, and distended to whiteness. After waiting five minutes, the papilla is removed as close to its base as possible by means of the snare. It is never necessary to anesthetize the sphincter, and oftentimes the anoscope or speculum is not required. By eversion of the anus (Fig. 168), the papilla may be brought into view and anesthetized and removed while thus exposed.

No dressing is required, the hemorrhage, which is slight, soon ceases, and no after-care is necessary, other than that employed following the operation for simple fissure.

When one of the Morgagnian crypts is inflamed, the area surrounding the crypt, including the papilla, should be injected and distended with the  $\frac{1}{4}$  per cent solution of apothessin or eucain, and a V-shaped incision made from above—the base being at the mouth of the crypt and the apex one-half inch below its center. This incision should be deep enough to open well the crypt. The flap, which includes the papilla, is removed, and its base cauterized with a saturated solution of silver nitrate. A suppository containing two grains each of chloretone and thymol iodid and five grains of quinin and urea hydrochlorid is then inserted. Where more than one crypt is involved, the same technic is employed for all, the lowermost crypt being operated first, and the others injected just before operating. Where a crypt is acutely inflamed, without an enlarged papilla, the simple incision with the author's cryptotome (Fig. 121), or similar instrument will suffice. The after-care is the same as has been described for hypertrophied papillæ.

## CHAPTER XII

### PROCTITIS AND SIGMOIDITIS

This consists of a catarrhal inflammation, either acute or chronic, affecting the mucous membrane lining of the rectum, sigmoid flexure, or entire colon. There are many varieties of inflammation affecting the rectum and sigmoid due to the invasion by the micro-organisms of gonorrhoea, syphilis, diphtheria, erysipelas, and dysentery. With the exception of the last-named variety, the inflammation caused by the micro-organisms of dysentery, the other varieties accompany or are caused by diseases affecting other organs and occur as a complication, and will not be described in this chapter. Amebic dysentery will be discussed fully in a separate chapter. The author, therefore, will limit himself to discussion of simple catarrhal proctitis and sigmoiditis, acute and chronic.

### ACUTE PROCTITIS AND SIGMOIDITIS

**Etiology.**—This disease occurs at all ages, children being affected as frequently as adults. Among the predisposing and causative factors are sudden changes in climate, weather, or mode of living; the ingestion of highly seasoned foods, condiments; and excesses in the use of alcohol or tobacco. Constipation is occasionally a causative factor, but the presence in the rectum of intestinal parasites, impacted feces, or foreign bodies, as well as infection of the rectum, from unclean enema tips or examining instruments, are more often responsible for its onset. Patients suffering from “rheumatism” and gout or those who are peculiarly susceptible to sudden chilling of the skin surface are particularly liable to attacks of acute catarrhal proctitis. Acute indigestion, with its attendant fermentation of food products in the intestinal tract, and ptomaine poisoning are very prolific sources, and inflammation by extension from any acute pelvic disorder is not uncommon. The use of drastic cathartics is also an etiologic factor of no small importance, and the ingestion of many food articles,

which in some individuals causes urticaria of the skin surfaces, will often be responsible for an attack of acute catarrhal proctitis.

**Symptoms.**—Its onset is attended oftentimes by a chill, slight rise of temperature, and a sense of uneasiness in the rectum and lower abdomen; oftentimes accompanied by backache, particularly over the sacral region, and occasionally shooting pains down the limbs. This is followed in a few hours by a sense of fulness and heat in the rectum, with a constantly increasing desire for stool. Disturbances of the bladder are noted, particularly a desire to urinate frequently and a burning sensation while doing so. The patient is most comfortable lying on his side. The movements become soft, and frequent evacuations occur. At first the move-



Fig. 170.—De Vilbiss spray tube, provided with an adjustable tip so that the spray may be thrown in any direction.

ments are those of ordinary diarrhea; after the first day or so, the movements consist more largely of feces mixed with mucus and sometimes tinged with blood. If the disease progresses and ulceration occurs, the movements contain blood and pus, and a mucopurulent discharge will be noted at the anal orifice between movements. In children, this condition frequently brings about prolapse of the rectum, and occasionally also in adults.

**Diagnosis.**—With the history of an onset, such as has been given above, examination of the rectal cavity is indicated. With the patient in the knee-shoulder position the proctoscope should be inserted, and the rectum inflated. If the insertion of the

proctoscope is accompanied by considerable pain, as it will be in many cases suffering from proctitis, the sphincters should be first anesthetized according to the technic outlined in Chapter XV. The appearance of the mucous membrane of the rectum is somewhat characteristic. Upon ocular examination, the rectal mucous membrane is bright red in color, its appearance being not unlike that of the inflamed conjunctiva, the difference being that the rectal mucous membrane will be more of a brick-red color, and the mucous membrane appears somewhat velvety and edematous. An increased quantity of stringy, yellowish mucus will be noted. The blood-vessels of the rectal wall, and particularly on the valves of Houston, will be found deeply injected and clearly outlined, standing out distinctly from the red mucous membrane.




Fig. 171.—Author's rectal spray tube.

**Treatment.**—The treatment of acute catarrhal proctitis is dietetic, systemic, and local. In those cases depending for their origin upon the presence in the rectum or sigmoid of impacted feces or foreign bodies, their removal is first indicated. Where the proctitis is caused by ptomaine poisoning from decomposition of food material in the intestinal tract, prompt and free catharsis is the first essential. Patients suffering from systemic or constitutional diseases in whom the proctitis is merely a complication should of course receive general medical treatment for the underlying constitutional or systemic trouble.

Where irritating or improper food material is the causative

factor, or the indulgence in alcoholic stimulants or tobacco in excess is responsible, ~~their interdiction~~ and withdrawal are obvious.

In the local treatment of acute catarrhal proctitis, copious irrigations of the rectum, sigmoid, and colon with normal saline solution, at a temperature of 110 to 115° F., given two or three times during the twenty-four hours, has in many cases been sufficient.

In irrigating the colon, the positions in which the best results are achieved are the knee-shoulder, left lateral or Sims', or the lithotomy. Where either of the last two positions are employed,

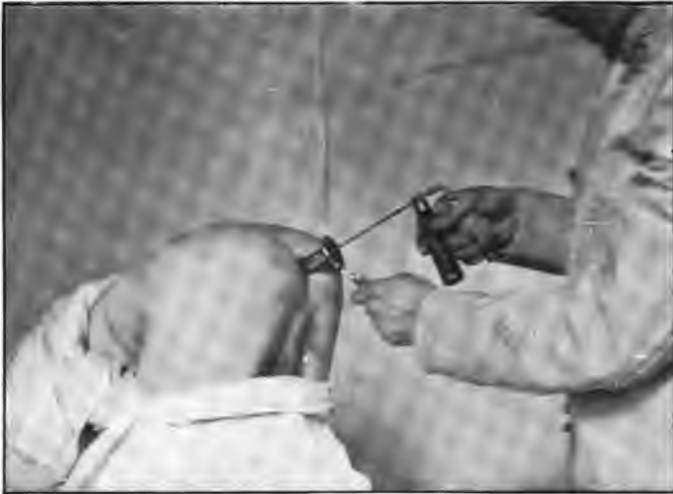

Fig. 172.—Spraying the rectum with the patient in the knee-shoulder position. On account of the ballooning of the rectal cavity by air inflation in the knee-shoulder position, this position is ideal for the application of sprays to the rectal surfaces.

the hips should be elevated considerably higher than the head (Fig. 181). The irrigator, or fountain syringe, to be placed from one and a half to two feet above the level of the anus, and the flow checked by pressure on the tubing, when there is a desire on the part of the patient to expel the fluid before a sufficient quantity has been administered. This uncomfortable feeling is due to the overdistention of the bowel at certain points when the inflow is interrupted by either the normal sacculations or spasmodic contraction of the circular muscular fibers. This sensation will soon pass away, however, if the inflow is checked for a moment so as

to allow the solution already in the bowel to flow higher up. Changing the ~~position of the patient~~ <sup>position of the patient</sup> from one side to the other and massaging the abdomen gently will greatly assist in the distribution of the irrigating fluid. By this method, the majority of patients will be able to retain a sufficiently large amount of the irrigating fluid to flush thoroughly the entire colon.

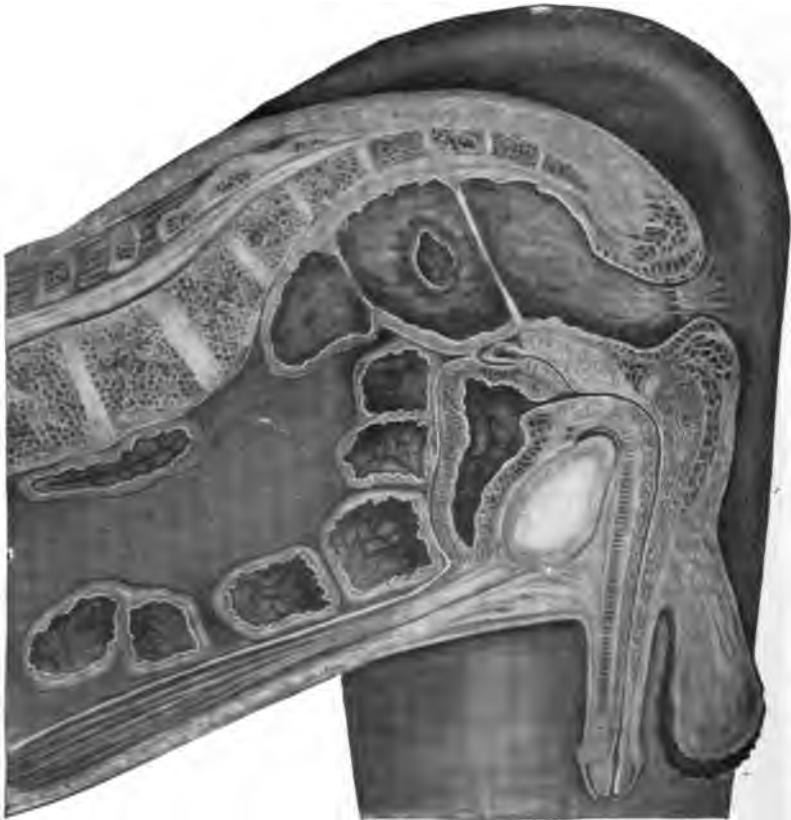

Fig. 173.—Ulcer of the rectum. This case well illustrates the importance in proctoscopy of examining the cavity behind each rectal valve. In this patient the ulceration was situated on the right lateral wall of the rectum, and had not the first rectal valve been pushed aside by the proctoscope, its presence might have escaped unnoticed.

In those cases where the mucous discharge from the rectum or sigmoid is profuse, the use of nitrate of silver solution in strengths ranging from one to five per cent, by means of the rectal spray (Fig. 170), has been found very efficacious. The author uses a

nine-inch metal spray tube, which is attached to the hand atomizer or used with compressed air. Its distal extremity is closed, but from its circumference, about one sixteenth of an inch from the end, the solution issues in all directions from four small apertures, so that the solution is not thrown any higher into the bowel than one wishes, but bathes all surfaces alike (Fig. 171). The rectum and sigmoid are best sprayed with the patient in the knee-shoulder position (Fig. 172). In some cases, where the mucous flow appears to come from higher up in the bowel, irrigations of the colon with various astringent solutions are indicated. Two to five per cent solutions of alum answer very nicely, and the aqueous fluidextract of *krameria*, from five per cent to twenty per cent as advocated by Tuttle, has proved of value in the author's hands.

While many authors advocate the confining of the patient in bed during the treatment of acute catarrhal proctitis, the author has found no difficulty in securing results by allowing the patient to be up and around for a greater portion of the day. He believes that better drainage of the intestinal tract is secured at all times by the upright position. In some cases where results are not obtained by spraying with aqueous solutions, and where there is a tendency for the bowel wall to ulcerate, the insufflation of various powders will be found of great value—iodosyl, compound stearate of zinc with balsam of Peru or boric acid, and thymol iodid have all been found very satisfactory in these cases.

Ulcerating spots should be treated with pure ichthyol or solutions of 5 per cent or 10 per cent of nitrate of silver. The author is not in sympathy with the use of solutions of the stronger chemical antiseptics, such as the bichlorid of mercury or carbolic acid, even when used in very weak solutions. He believes that more harm is accomplished by the action of the irritating chemical solutions on the weak and debilitated lining mucous membrane than whatever little good they accomplish by their action as antiseptics.

In irrigating or flushing the colon, the recurrent-flow soft-rubber colon tube, devised by J. L. Jelks, of Memphis, Tenn., will be found a very useful piece of apparatus (Fig. 180). For the technic of its use the reader is referred to the following chapter. During the treatment of a case of proctitis or sigmoiditis, the patient should be kept on a light and nonirritating diet in which the

vegetable elements are largely eliminated. The thin cereal gruels prepared from oatmeal, rice and barley, egg-albumen, the various flavored gelatins and liquid peptone solutions, as well as butter-milk, will be found best for use in these cases. The use of chocolate has also been found of great value as an addition to the dietary. Four to six ounces daily will take the place of an equal quantity of meat and leave less residue. Milk is contraindicated on account of its tendency to constipate, and the fact that it forms hard curds which only further irritate the already sensitive bowel.

Internal medication is not of much avail; the use of five grain tablets of trimethol and ichthyol in 2 to 5 grain doses, given in double capsules four times daily, the author believes, has given some good results. He has found the employment of white refined petroleum oil to be of particular value in proctitis. It seems to have a specially soothing effect on the inflamed and irritated mucous membrane of the bowel, and while it does not produce or stimulate peristalsis, it causes easy and free evacuation by its mechanical softening and lubricating effect. Being a mineral oil of no food value and having no medicinal effect, it is not acted upon by the digestive secretions, and passes through the intestinal canal unchanged.

The patient should be instructed to drink six to eight glasses of water daily; if there is any doubt as to the purity of the water, it should be boiled and then kept in bottles on ice. In order to remove the flat taste of boiled water, the author would suggest that before use it be poured into an open vessel or pitcher and stirred up with a revolving egg beater. This aerates the water so that it again tastes fresh and clean, and effectually removes the unpalatable taste which is one of the drawbacks to the use of water sterilized by boiling. The use of flaxseed tea is often of assistance in these cases. If properly prepared, it is of distinct value. A good way to prepare flaxseed tea is as follows: Take four or five tablespoonfuls of whole flaxseed and place in a shallow pan. Pour over this a quart of boiling water, place the pan over the flame and allow to boil for five minutes, then strain through muslin and allow it to cool. It is best kept on ice until ready to use. If it is desired to sweeten or flavor the flaxseed tea, lemon juice, oil of peppermint or wintergreen, and sugar may



be added in quantities to taste while the tea is still hot. A tea-cupful should be taken as hot as can be comfortably borne every night at bedtime. This will often act as a mild laxative and seems to have some soothing influence on the mucous membrane of the bowel.

### CHRONIC PROCTITIS AND SIGMOIDITIS

This disease is usually of two varieties, hypertrophic and atrophic. The atrophic variety is the most common variety of chronic proctitis or sigmoiditis. The hypertrophic variety may follow an attack of acute proctitis or sigmoiditis but is often produced by other diseased conditions outside the bowel. Pressure from abdominal tumors, movable kidneys, uterine displacements, extension from pelvic cellulitis, and adhesions following inflammatory conditions of the pelvis may all set up attacks of hypertrophic proctitis and sigmoiditis. Appendicitis has also been noted as an etiological cause.

The atrophic variety may often be brought about by a long period of chronic constipation, the abuse or excessive use of cathartics extending over a long period of time, excesses in both eating and drinking, particularly in people of sedentary habits. Other causes of a more local nature are repeated attacks of fecal impaction, the enema habit, foreign bodies in the rectum and unnatural practices.

**Chronic Hypertrophic Proctitis.**—This variety is distinguished from the atrophic variety by the fact that the mucous membrane and submucosa are always thickened, and the glands as well as the interglandular connective tissue hypertrophied and increased. The anal papillæ are usually very much enlarged in this condition. On proctoscopic examination the appearance of the mucous membrane is somewhat characteristic. Tuttle well described it as follows:

Through the proctoscope it appears edematous, paler than usual, and covered with a thin coat of whitish secretion. The swollen membrane bulges out into the fenestra of the conical speculum or falls down and completely covers the end of the proctoscope. When the mucopus is wiped off, the membrane presents through the magnifying glass a cauliflower-like appearance, whitish and granular. It does not bleed easily, and the end of a fine probe being pressed down upon its surface, the tissues will meet together above it. By scraping with a rectal scoop one may

obtain a certain amount of mucopurulent fluid, consisting of pus-cells, leucocytes, and various bacteria, together with small masses of fecal matter and undigested particles of food.

**SYMPTOMS.**—The disease may be of insidious onset, or it may be the continuation of an attack of acute catarrhal proctitis. The patient is usually in a run-down condition, and presents the usual symptoms of such a state, such as impaired appetite, foul breath, indigestion, gaseous eructations, diarrhea, occasionally alternating with constipation, a frequent desire to defecate without much result, and an unsatisfied feeling as if something more were to pass away after the stool. Where the passages are loose, the stools are inclined to be of a pea-soup consistency, consisting quite largely of mucopurulent material, or there may be small hardened boluses or scybala covered with sticky mucus, or mucopus. On account of the hypertrophied condition of the mucous membrane, prolapse is met with in some cases, and pruritus ani is a frequent symptom. The secretion keeps the region of the sphincter constantly moist and is occasionally so profuse and constant that the patient has to wear an absorbent dressing to prevent it from soiling the clothes. On account of the constant moisture of the part, condylomata are occasionally found, particularly at the posterior aspect of the anus and anal canal.

**DIAGNOSIS.**—The diagnosis is made upon proctoscopic and sigmoidoscopic examination. The characteristic hypertrophied appearance of the mucous membrane, with the presence of mucopurulent discharge, with or without ulceration of the mucous membrane, accompanied by a history of symptoms such as have been given above, should make the diagnosis not difficult. The condition is, fortunately, not very common.

**TREATMENT.**—If upon examination of the patient such extrarectal causes as appendicitis, floating kidney, or abdominal or pelvic growths impinging upon the bowel are discovered, the indicated surgical measures for their relief should be carried out. The patient's dietary should be corrected, and all condiments, alcoholic stimulants, pastries, salads, sweets, fresh fruits, and freshly baked foods prohibited.

In order to give as little work to the intestines as possible, the patient should be put on a diet which is largely assimilable: such as, eggs, buttermilk, gelatins, chocolate, lean meat, poultry,

freshwater fish, and small quantities of green vegetables, such as spinach, beet tops, lettuce endive, and kale. The patient should be encouraged to drink large quantities of cold water and should try to have a bowel movement at regular hours. Liquid petrolatum in doses varying from one to four drams three or four times a day should be administered, on account of its soothing influence upon the mucous membrane of the intestinal tract, and because by its admixture with the feces it prevents the formation of hard, irritating masses.

Where symptoms of intestinal indigestion are present the author has found pancreatin in ten-grain doses, taken with or directly following the meal, of considerable value. Ichthyol in double capsules, in doses of from two to five grains four times daily, seems to be of some service. Trimethol in 5-grain enteric tablets, administered four times daily, is useful. The bowels should be flushed morning and night with some astringent solution, such as is used for the treatment of acute catarrhal proctitis. Tuttle recommends very highly the use of one to three quarts of a two to ten per cent solution of aqueous fluidextract of krameria. This is best given with the patient in the knee-shoulder position and through a Jelks' recurrent-flow colon tube. The preparation of the aqueous fluidextract of krameria is described by Tuttle as follows:

Macerate one pound of bark of krameria in a long percolating tube for twenty-four hours. After this a mixture of 20 per cent glycerin and 80 per cent water is allowed to percolate through it. The percolate should be constantly stirred and refiltered through the bark the second time. The filtrate is then evaporated down to one pound, thus obtaining an aqueous fluidextract, containing grain for grain all the therapeutic properties of the bark. The preparation should be kept in a dark place and not exposed to the air.

If, on proctoscopic or sigmoidoscopic examination, localized ulcerated areas (Fig. 173) are discovered, they should be sprayed with a 1 to 3 per cent solution of nitrate of silver or 5 per cent solution of ichthyol. They may be stimulated by the application of nitrate of silver, 10 per cent, or pure ichthyol or balsam of Peru, using a long-handled applicator. The general condition of the patient must be improved by ordinary tonic measures and the encouragement of moderate exercise in the open air and sunshine.

**Chronic Atrophic Proctitis and Sigmoiditis.**—This variety is more

common than the hypertrophic, and consists of a general atrophy of both the glands and intraglandular structures of the rectum and sigmoid. It differs from the hypertrophic variety in that it does not frequently extend higher than the sigmoid flexure, and there is a thinning or destruction of the mucous membrane lining of the bowel. The pathology of the condition is well described by Tuttle as follows:

One observes upon examining the mucous membrane in these cases an irregular, bosselated, or granular appearance. The surface is dry, rough, inelastic, and without any salient vegetations. Attached to the surface here and there are small masses of dry fecal material, and occasionally little islands of necrotic epithelium or pseudomembrane.

Microscopic examination shows the epithelium absent in many places, but always present in the deeper portions of the crypts of Lieberkühn. These follicles are generally atrophied, the intratubular tissue decreased, and their goblet-cells are few in number. The cylindrical epithelium is said to assume the stratified pavement type in this disease. This change does not extend more than one or two centimeters above the anorectal line; it is confined to the superficial structure of the membrane, and does not involve the tubules.

The connective tissue of the submucous coat is dense and slightly thickened; it does not contain embryonic tissue and elastic fibers, as in the hypertrophic form. The solitary follicles are often enlarged and distended. At points there are distinct granulations, and ulcerations, accompanied with hyperemia and multiplication of the blood-vessels, but there is no alteration in the blood-vessel walls.

**SYMPTOMS.**—As has been stated, this condition supervenes frequently on an old long-standing case of constipation. The stools are small, hard, and dry, and their passage is painful; they are often streaked with blood, pus, and mucus. The patient suffers from tenesmus, referred pain in the sacral region and down the legs. The rectum feels hot, and after stool it feels as if it were not emptied. This feeling is not like the sense of fulness which is more characteristic of the hypertrophic variety; but more a sense of uneasiness which focuses the patient's attention upon the rectum, which makes him feel that the emptying of the rectum will bring him relief. Pruritus ani is a frequent symptom as well, as is spasm of the sphincters. On account of the contracted condition of the anal canal, the passages are frequently followed by the production of small fissures or cracks in the mucous membrane. Their presence adds a stinging or burning sensation to the other symptoms of the disease. These fissures are very superficial and are not to be confounded in any sense with the true

or typical anal fissure. They consist merely of linear abrasions in the lining membrane of the anal canal, and lack any tendency to chronicity which is characteristic of a true fissure. Hemorrhoids are said to be found frequently accompanying this condition.

With the patient in the knee-shoulder position, proctoscopic examination shows the mucous membrane to be reddened, but not markedly as in the acute variety, dry, covered here and there with small flecks of dry fecal matter. The insertion of the proctoscope is usually accompanied by some hemorrhage due to the passage of the instrument. On examination of the rectal walls numerous pin-point ulcerations are met with. The mucous secretion, which is very slight in this condition, clings to the bowel wall, and is characterized by thickness and tenacity. In this variety the mucous membrane does not fall together before the proctoscope, and the rectum gives the appearance of being a stiff tube, while the rectal valves stand out very markedly. Ulcers other than the pin-point variety are not uncommon, and tend, when present, to become chronic and gradually to encircle the bowel, producing a strictured condition.

**TREATMENT.**—In this condition the presence or absence of syphilis should be ascertained. Where either from the ignorance of the patient of his true condition or from his reticence about the matter one cannot obtain a definite history, the Wassermann test, or serum diagnosis, should be resorted to. If positive, the ordinary measures for the treatment of syphilis in the third stage should be employed, the intravenous administration of salvarsan being of the greatest value in those cases.

The diet is exactly the same as that outlined for hypertrophic proctitis, with the exception that the patient may have fatty food, bread (not freshly baked), toast, rice, sago, and custards. Where intestinal indigestion is present, pancreatin should be administered and liquid petrolatum given, as outlined in the treatment of the hypertrophic variety. As this condition is usually confined to the rectum and lower sigmoid, the high irrigations will not be necessary, but the solutions mentioned are equally applicable for the flushing of the sigmoid and rectum in this variety. After irrigating the rectum, the patient should be put in the knee-shoulder

position, and under the guidance of the eye, ulcerated patches on the mucous membrane should be touched up through the proctoscope with two to five per cent solution of nitrate of silver, iodine, or pure ichthyol. Ichthyol in five per cent aqueous solution is very valuable as a spray in this condition, as is the fluid extract of krameria in strengths ranging from twenty to thirty per cent. The treatment of the accompanying conditions, such as fissures, hemorrhoids, and pruritus, should be carried out as outlined under the respective chapters. What has been said before regarding exercise and fresh air is equally applicable in this condition.

Do not commit the grievous error of treating a patient for a localized proctitis or sigmoiditis when the disease affects the whole colon. While mild cases of colitis will respond to the treatment outlined in this chapter, many cases of colitis will require physiologic rest, and this can only be accomplished by cecostomy or temporary colostomy. Colonic irrigations from above may also be required before a cure can be effected.

## CHAPTER XIII

### DYSENTERY

By JOHN L. JELKS, M.D., F.A.C.S., Memphis, Tenn.

#### GENERAL CONSIDERATIONS

**Synonyms.**—Colitis, *die rote Ruhr*, or *Dysenterie* (German), *Difficultas intestinorum* (Latin), *Δυσ ζντερον* (Greek).

**Definition.**—An acute or chronic inflammatory disease, usually affecting the large intestine, beginning in the rectum, but sometimes extending into the small bowel. In the acute form it is characterized by pain, tenesmus, and frequent passages of bloody mucus. In the chronic form the patient suffers recurrent attacks of diarrhea alternating with constipation.

**Historical.**—Dysentery was one of the best known diseases of antiquity. Even before the time of Hippocrates, reference to it was made, the earliest being that found in the papyrus of Ebers. Hippocrates, in the year 460 B. C., was the first writer to give a fairly accurate description of its symptomatology, pathology, and sequelæ.

Other well-known writers were Celsus, the medical Cicero of his day (45 A. D.), Aretæus, Galen, and Alexander of Tralles. Then for more than a century little further knowledge was imparted until the time of Antonio Benivieni (1506), and Thomas (1833), who refuted many of the erroneous ideas of his predecessors. Woodward (1879) gave a most excellent history of this disease.<sup>1</sup> Kartulis, in Egypt (1885), Flexner (1890), Councilman and Lafleur (1892), Shiga, of Japan (1879), Strong and Musgrave, McDill, of Manila, and Harris of Atlanta, of the present era, have contributed perhaps the most valued writings. Osler, Tuttle, and Surgeon General Sternberg, of the United States Army, are also among those who have furnished data in our own country.

The author of this chapter has also made close study of this disease in the Southern states.

<sup>1</sup>Medical and Surgical History of the War of the Rebellion, Vol. 2.

**Geographical Distribution.**—Dysentery does not respect any country, climate, or race. Ayers very truthfully states that where man is found there some of its forms appear. A. Hirsch says that it has a wide distribution over the inhabited earth at all historic times. It is without doubt one of the four great epidemic diseases of the world. In the tropics its ravages have been most deadly, destroying more lives than cholera, and to the armies it has been more destructive than powder and shot (Osler), and it has been shown that the ameba is the prevailing etiologic factor in the disease as observed in the Southern states. Dysentery is a destructive giant compared to which strong drink is a mere phantom (McGregor). The worst outbreaks occur as epidemics in the tropics and decrease as we leave this latitude, while in the higher latitudes it seldom appears in this type, though now and then in greater or less epidemics. A very striking fact relative to this affection is that it involves the cold zones. Epidemics have been reported in Alaska, Sweden, Russia, Greenland, and Iceland, also other of the colder countries.

**General Etiology.**—**SEASON.**—Among the predisposing causes season is the most important. More cases of dysentery are found during the summer and autumn months. This is due to several reasons. Sudden changes in temperature, especially sudden rises, have a most marked effect. It is most prevalent in the warm climates, and as stated above, it is most deadly in the tropics. Therefore, *climate* should be mentioned as one of the causative factors.

**RACE.**—Race itself does not seem to affect this disease. Strange though it may seem, the negro race in the South has not seemed to suffer much, with reference to this disease; notwithstanding the baneful consequences of poor hygienic conditions, as overcrowding, improper food, poor ventilation, filth, thin clothing, and especially syphilis—a disease almost universal among this race, either inherited or acquired. These, however, must all be included under predisposing causes.

**SEX.**—Under etiology, we should also mention sex. Within our experience, which is not at variance with that of other writers, dysentery is much more common among males.

**POOR HYGIENE.**—In the slums of our cities, where filth abounds



and where proper sewerage is lacking, we find more cases of dysentery than in the sections where the hygienic conditions are better. Many cases are found in institutions, such as insane asylums, barracks, jails, and army camps. Wherever there is overcrowding, there is very likely to be found a large percentage of dysenteric cases. During the Civil War, Woodward reported 259,071 cases of acute dysentery, and 28,451 of the chronic form, in the Federal service alone. In the Marne counter-offensive in July and August, 1918, thousands of cases of the bacillary type occurred among the troops of the American Expeditionary Forces. The disease was definitely proved to be fly-borne.

**TOPOGRAPHY AND CONDITION OF SOIL.**—Investigators have tried to associate dysentery with certain topographical conditions, or with conditions in the soil, but have been unable to do so.

Epidemics have proved more fatal in the country than in the city.

Soil that is badly contaminated with dysenteric excreta is a great source of infection. Czernicki tells about dysentery breaking out in two French squadrons in 1875 that were on the same ground occupied a short time previously by a cavalry regiment which had been affected with the same disease.

The writer has often found nests of dysenteric cases in the low flat mill districts of the city, and in marshy lowland sections of the country. No doubt, owing to the character of the soil in these localities, seepage contamination of drinking-water sources sometimes occurs. Houses built upon a low damp soil are unsanitary, and when the surrounding soil always remains saturated with moisture, there exists a favorable condition for the development of dysentery. The peculiar emanations from soil of this kind have always been considered very harmful. It is thought that they have a depressing influence upon the inhabitants, and thus make easier the inroads of diseases.

In one ill-drained district of Memphis, the author has treated many cases of amebic dysentery within a radius of two blocks, and other cases were treated that had been infected in the same territory. It is also an interesting fact to note here that two families, in which were four of the patients, purchased vegetables from the same Italian huckster.

There is yet another reason why we find more cases in marshy lowland districts. Here we find the greatest growth of vegetation, which, when conditions are favorable, furnishes a most suitable nidus for the propagation and development of amebæ, bacteria, and other micro-organisms.

**Foods.**—Certain articles of food are unquestionably predisposing causes of dysentery. This fact is not due so much to an idiosyncrasy to some particular foods, but mainly to the microorganisms which they contain, and to the putrefactive changes which occur within the intestinal tract. All groundling vegetables and fruits, especially those shipped from the tropics, and from infected districts are possible sources of infection.

Undoubtedly infections with the amebæ have been traceable to eating such vegetables as lettuce, strawberries, cress, and potatoes.

Amebic, flagellate and pellagrous diarrheas have been directly traceable to infected gardens and homes wherein antecedent cases had been treated months and even years before.

Eating food in excess, and the resulting attacks of indigestion, often pave the way for dysentery.

**DRINKING WATER.**—The author has given much thought to water supply as a medium through which dysenteric infections are conveyed. This is undoubtedly the most common source. We have been impressed by the fact that many cases are found among sportsmen, also timbermen who spend much of their time in the woods, and who drink, when necessity requires, from surface pools, springs, and slashes.

The author has treated cases of amebic dysentery from a country district with which he is quite familiar, and has knowledge of the fact that the disease was contracted in the same infected neighborhood in which twenty years previously another case has lived, which proved fatal. The fact has been elicited that many of the author's cases had neighbors who were suffering in like manner, and who were procuring their drinking water from the same source.

There are certain rivers in China whose waters are known to cause dysentery.

In 1863, the number of cases among the workmen constructing the Suez Canal was decreased when the better water of the Nile was used.

The author has treated one case of amebic dysentery in the person of a physician, who thinks undoubtedly that the infection was obtained from drinking Mississippi River water while on board a river steamer. Thevenol says, "Nothing is so prone to lead to disorganization of the large intestine as infected water." Impure water itself does not produce dysentery, but only when it contains the special micro-organisms.

### ACUTE CATARRHAL DYSENTERY OR SPORADIC BACILLARY DYSENTERY

This form is the least severe and most common form that is encountered. It occurs both sporadically and endemically. This type is characterized by the frequent passage of great quantities of mucus.

**Etiology.**—Children principally are infected with this form, but we often see it in adults, most often complicating other diseases. It is the kind of dysentery that accompanies all of the exanthemata. We see it, in fact, complicating almost all of the acute infectious diseases. Still another important cause is the ingestion of certain kinds of foods, or other irritating substances. The ordinary attacks of enterocolitis in babies during the summer months come in this classification. Most of these attacks are due to milk poisoning (bacterial and putrefactive changes).

**Pathology.**—Macroscopically a superficial, acute inflammation involving the large intestine, but sometimes extending into the small bowel, is seen. The tendency of such cases is to recover without necrosis. Sometimes, though, in the more severe attacks, the mucosa will become injected to such a degree that small ulcerations occur. In these cases the mucus is often stained or streaked with blood.

Microscopically, are seen the *Bacillus coli communis*, also the *Trichomonas intestinalis*, and *Paramaccium coli*, and occasionally the *Cercomonas intestinalis*. We also find red blood-corpuscles and leucocytes, and always large numbers of desquamated epithelioid cells, dotted about with fat globules and vacuoles.

**Symptoms.**—The onset is sudden and usually ushered in by an attack of cholera morbus, or by an attack of acute indigestion. Sometimes a more or less distinct chill may occur at the onset.

Nausea and vomiting are not rare symptoms.

The tongue has a moist coat at first but soon becomes dry.

From the first there is diarrhea. Pain is complained of over the entire abdomen, also tenesmus, and severe griping pains. The patient is extremely restless and cannot get relief from a desire to stool. The bowel movements are at first free, and watery, or sero-sanguineous, but later on, contain only small quantities of mucus streaked or stained with blood, and have an offensive odor.

A slight elevation of temperature usually accompanies this form, but in more severe cases, it may reach 103° F. There is corresponding acceleration of the pulse, and the patient complains every few minutes of thirst.

The stools, during the first day or two of the attack, contain, in addition to the above-mentioned materials, small fecal masses (scybala). Sometimes, during the course of the attack, the stools contain an excess of bile and cause intense burning while passing.

The ordinary cases of acute catarrhal dysentery are self-limited, usually recovering in a week. Some are so mild that treatment is not sought. It must be remembered, however, that the cases which begin with mild symptoms may develop graver ones at any moment.

**Diagnosis.**—The diagnosis is very easy. The cramping pains, tenesmus, and frequent passages of mucus and blood are positively diagnostic. If, however, a case may be obscure, the microscope and proctoscope will at once clear it up.

**Prognosis.**—In most cases the prognosis is favorable, but it is best to be guarded at all times in giving it, since some of the cases, which at first seem quite mild, may terminate adversely. Ordinarily, though, the symptoms will subside in a week, and the patient will recover rapidly. There is always rapid emaciation and weakness.

### DIPHTHERITIC DYSENTERY

**Definition.**—This is an inflammation, usually confined to the lower part of the colon, and rectum, but sometimes extending into the small bowel. It is accompanied by a croupous, or true diphtheritic, exudation. It is one of the epidemic forms found in Japan, also in armies, in insane asylums, and ships, or wherever large numbers of people are crowded together.

**Etiology.**—This form of dysentery is caused by the *Bacillus dysenteriae*, discovered by Shiga in Japan (1897). Flexner and Strong encountered the same bacillus in one of the forms of the disease which prevails in the Philippines and Porto Rico. The bacillus is described by Shiga as being a short rod with rounded ends, and closely resembling the bacillus of typhoid fever. It possesses slight motility. Flexner discovered that the bacillus “is inactive to blood-serum from typhoid fever cases, but reacts with serum from dysenteric cases to which *Bacillus typhosus* does not respond.” Shiga’s bacillus may be found within the body as late as one year after the primary infection.

**Pathology.**—The mucosa, if the attack is not severe, is coated with a yellow exudate. Slight ulceration of the mucous membrane over the tops of the folds of the colon is seen.

In severe attacks, however, all the layers of the colon are involved, and it appears greatly enlarged. The infiltration is so great that extensive necrosis takes place. The mucous membrane over the entire colon presents a puffy or swollen condition, yellow in color. Large areas may slough *en masse*.

Microscopically, this slough is found to consist of a fibrinous and cellular exudative coating over the mucosa.

The glands of Lieberkühn are destroyed, and sometimes no trace of them is found.

**Symptoms.**—The symptoms are practically the same as those of acute dysentery greatly intensified. The onset is more severe. The chill is often present, and the fever is high, running an irregular remittent course. The pulse is greatly accelerated; tormina and tenesmus are most severe.

Delirium is common. Bowel movements may at first be loose and watery. Soon great quantities of sero-sanguineous discharges, containing bloody mucopurulent material, and sloughs of variable sizes, are passed. The distention of the abdomen is greater, and pain is more severe. There is more rapid loss of strength.

**Diagnosis.**—The diagnostic points of most value are the character of the dejections, which may contain pseudomembranes, severe symptoms, and the appearance of epidemics.

The positive diagnosis is by the agglutination test.

**Complications.**—Complications in this form are encountered more frequently [www.libtool.com.cn](http://www.libtool.com.cn)

Perforations sometimes occur and are almost invariably followed by peritonitis.

Liver abscess is another grave complication.

Nephritis, phlebitis, pericarditis, endocarditis, and pleurisy have also been noted.

Grave symptoms referable to the central nervous system, due to toxin poisoning, denote a complication of serious moment.

Recovery sometimes takes place, but usually after a more or less chronic course.

### SECONDARY DIPHThERIC DYSENTERY

The lesions of this form are similar to those of the last described, but not so severe. The secondary, as the name implies, usually follows one of the acute, or chronic, diseases, as pneumonia, nephritis, pericarditis, endocarditis, pulmonary phthisis, typhoid fever, and numbers of other varieties.

**Symptoms.**—The symptoms are sometimes not very noticeable. The griping pains and tenesmus are not very severe as a rule. The patient has about two to six loose bowel movements a day. Anatomically, the inflammation is very superficial, only the upper layers of the mucosa being involved. The inflammation may progress, producing more or less necrosis. Very little blood is found in the stools.

**Prognosis.**—The patient will often perish. Owing to adynamia already existing, much resistance is impossible.

### FLAGELLATE DYSENTERY

**Etiology.**—During the last fifteen years the author's attention has been drawn to the increasing prevalence of flagellate infections, and during more recent years many cases of pure flagellate diarrheas have been observed. Many of these cases have been traced to their origin with a view of ascertaining the source from whence the infection came. In many instances *Cercomona-Intestinalis-Hominis* dysenteries have been as easily traceable to one or more

preceding cases in a neighborhood or home wherein the patient had visited, as could have been traced a typhoid fever infection.

This form of dysentery is at present almost entirely confined to the warm and hot climates, and is very prevalent in the southern tier of the gulf states. The most prevalent form of the disease is that caused by the *Cercomona-Intestinalis-Hominis*, though other flagella may produce diarrhea.

This organism invades the small intestines, is 16 to 20 microns long and 10 to 12 microns broad, or about one fourth the size of a pathogenic ameba. It is capable of very active motility and is propelled by its tail.

These organisms are found in larger numbers after a dose of salts is given which causes them to be washed down into the large intestines. They produce pathology in both small and large intestines. This pathology is very superficial when the infection is an unmixed one, amounting to congestion, erosion of the epithelium and an occasional ecchymosis or circinate abrasions. The stools, ten to thirty in number in twenty-four hours, are more like those of typhoid fever and of pellagra, and the gross pathology seems to be the same that I have observed in the acute diarrhea of pellagra.

**Treatment.**—The diet must be free of carbohydrates, fresh vegetables, pork, and pepper and other irritants. The diet I have found best is bulgarian buttermilk, sweet milk with lime water, junket, albumins, albuminous foods, chicken and other fowl, fish, beef, mutton and gluten bread.

The usual treatments given are not sufficient to establish a cure of these cases. Repeated microscopical examinations after the administration of salts should be made before dismissal, for all symptoms may have disappeared, only to return later, and such cases are carriers of the infection.

Large doses of bismuth subnitrate, hexamethylenamin, zinc sulpho-carbolate, ipecac and methylene are the remedies usually prescribed by the author.

**Treatment by the Trans-duodenal Route.**—Treatment of these cases by the transduodenal route has given good results in some cases. Dr. Anthony Bassler, of New York suggests the following solution to be used through the duodenal tube.

Soda Sulphate 270 grams

www.libpubl.com.cn Soda Chloride 270 grams

Water 900 c.c.

Boil and filter

Use 30 c.c. (1 oz.) to the liter of water.

To this solution may be added methylene, two to five grains to the ounce. This method requires a technician and an equipment, also a patient who is willing to cooperate with the attendant.

It is especially in this form of diarrhea and in the diarrhea of pellagra that there occurs a more or less severe colon bacillemia and bacilluria with grave toxic symptoms, in which the author has on numerous occasions used stock vaccines with almost negative results, but when the bacilli could be recovered from the urine and autogenous vaccines given every 5 to 7 days, the results have been brilliant. The author does not attempt to explain these results of his clinical experience.

One to two drams of bismuth subnitrate, followed in 30 minutes to one hour with 5 grains each of methylene and hexamethylenamin in salol coated capsules every 6 hours for an adult has given good results.

The tormina and meteorism some cases complain of are best relieved by salol grains 5, hyocyamus grain  $\frac{1}{2}$ , camphor grain  $\frac{1}{2}$ , every four to six hours, and the application of heat over the abdomen.

### AMEBIC DYSENTERY

**Synonyms.**—Amebic colitis, amebic enteritis, amebiasis.

Dysentery in this form is both epidemic and endemic in the tropical countries, especially India, Africa, and the Philippine Islands. In the United States sporadic cases are met frequently. Osler says that his cases in the Johns Hopkins Hospital were almost exclusively amebic. It is very rare, indeed, that the author is called upon to treat a case of the severe acute or chronic type in which he is unable to make a positive diagnosis of amebic infection by means of the microscope.

This is the prevalent type of the grave, chronic, and relapsing cases of dysentery in this country, and many of the supposed diphtheritic dysenteries are of this origin. The microscope only, however, can verify or refute this opinion.



Many cases of amebiasis have been diagnosed by the author when no ~~history of dysentery~~ or even diarrhea was obtained. He has also operated on two cases of amebic liver abscess, when the most careful inquiry failed to reveal a past or present history of the symptom dysentery or diarrhea.

**Etiology.**—This form of dysentery is caused by the *Entamæba histolytica* or the *Amæba dysentericæ* (Fig. 174). (Councilman and Lafleur.)

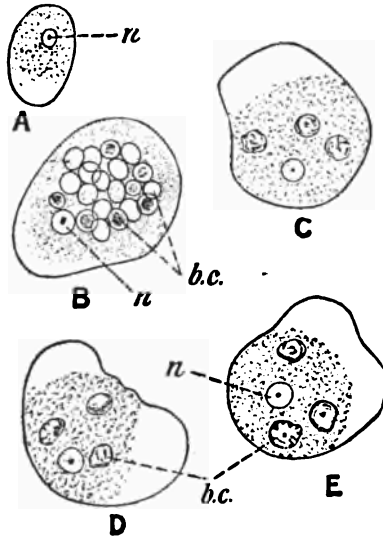


Fig. 174.—*Amæba histolytica* (Schaud). A, young specimen; B, an older specimen crammed with ingested blood-corpuscles; C, D, E, three figures of a living amoeba, which contains a nucleus and three blood-corpuscles, to show the change of form and the ectoplasmic pseudopodia; n, nucleus; b, c., blood-corpuscles.—After Jurgens, from Albutt's System of Medicine.

It is a type of protozoön, unicellular, and motile, several times the size of a red blood-corpuscle. In structure the organisms have an outer colorless zone, called the ectosarc or hyaloplasm, and an inner granular zone, the endosarc or endoplasm. Its nucleus is eccentrically situated, and one or more vacuoles are present. This parasite is phagocytic in character, and may be seen to contain red blood-cells, bacilli, vacuoles, and other particles. It is easily mistaken for a large epithelial cell, or paramoecium, when not in motion. It is ten to fifty microns in size. The *Amæba histolytica* multiplies by segmentation, the nucleus and

endoplasm dividing in such manner as to form several embryo-cells for the corresponding number of new cells. The old cell either dies or enters into the encysted state. After an uncertain period the cell-wall bursts, and liberates the new cells. The mother-cell, containing the daughter-cell, may remain encysted for an indefinite time. In this state it is much smaller than the ameboid form, and is non-pathogenic.

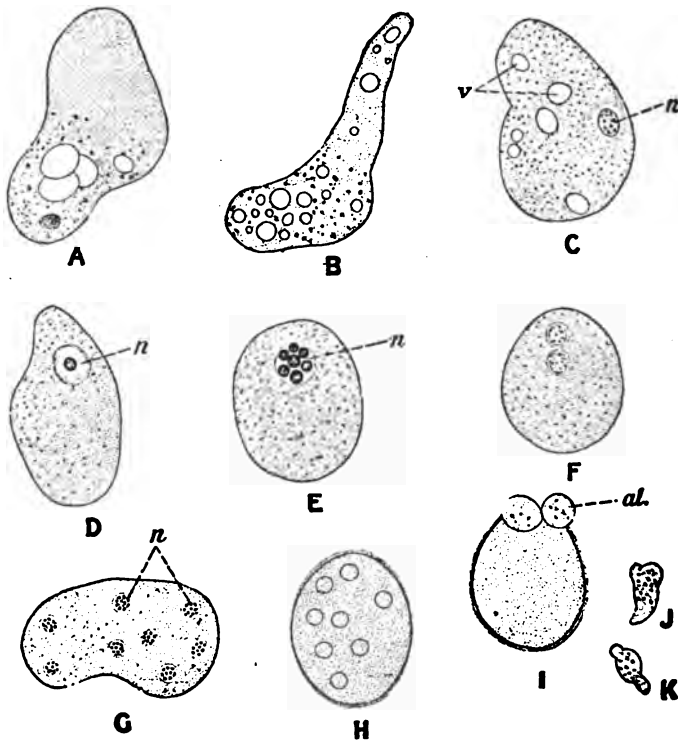


Fig. 175.—*Amœba coli mitis*. A and B, living amebæ, showing changes of form and vacuolation in the protoplasm; C, D, E, amebæ, showing different conditions of the nucleus (n); F, a specimen with two nuclei, preparing for fission; G, a specimen with eight nuclei; preparing for multiple fission; H, an encysted ameba containing eight nuclei; I, a cyst from which young amebæ (al) are escaping; J, K, young amebæ, free.—After Casagrandi and Barbagalli, from Albutt's System of Medicine.

There are two well-recognized species of amebæ, the kind above described, and the *Amœba coli mitis* (Fig. 175), which is occasionally found in healthy persons. This organism is also found in other bowel affections. It is non-phagoeytic, twelve to thirty-six

microns in size. Propagation is by gemmation or budding; a portion of the cell body being thrown out and then broken off, forming a new individual.<sup>2</sup>

All authorities now agree that the bacteria of symbiosis, and other associated micro-organisms, have much to do with the pathogenicity of the amebæ.<sup>3</sup>

I have observed with much interest certain of these symbiotic bodies, as also rod-shaped bacilli contained in the ameba in a class of cases to be referred to later.

The ameba is not the only pathogenic organism to be considered, therefore, during an attack of amebic colitis, for the colon bacillus is known to produce many of the pathological conditions in these cases; so, this and other bacillary infections may at any time supersede in importance and virulency amebic infection; therefore this fact and possible complication must at all times be kept in mind, and in this emergency met with proper treatment and diet.

I have noted that the cases presenting themselves during the summer or autumn usually show the more active and phagocytic amebæ, or, more properly speaking, in those cases in which I have found the more active and phagocytic amebæ, I have also found the greater virulence. In making microscopic examinations of most cases, the parasites are either very inactive or cease motility quickly, rendering necessary at times two or three examinations to make a positive diagnosis or, necessitate staining; in which latter event the following technic which is practiced by the author is most satisfactory.

Schaudinn's sublimate alcohol solution two parts, and one part absolute alcohol are mixed in a Petri's dish. Make a thin smear of fresh specimen on a slide and immerse in the above at once without drying, for 5 minutes, then harden in 80 per cent alcohol for 10 minutes, then wash in distilled water, stain with Hastings stain or other stain which may be preferred, 5 to 20 minutes, wash,

<sup>2</sup>After close observation, covering a great number of cases, the author has become convinced that there exists a pathogenic ameba which does not correspond exactly with the description above given of the *Ameba histolytica*.

This ameba is smaller, the hyaloplasm is not so distinct, though its lighter zone is discernible, and this hyaloplasm or ectosarc can be seen forming pseudopodia. This ameba is both granular and phagocytic, and is often observed very active, hence, in the author's opinion, this ameba is likewise pathogenic.

<sup>3</sup>The *Balantidium* (*Paramecium*) *coli* must be reckoned with as being responsible in part or wholly for some cases of colitis, and this parasite is always considered responsible for a part of the pathological conditions, when observed associated with the ameba.

and dry by blotting, and mount. Examine with high power, oil immersion, in strong light.

By this method the cell nucleus, nuclear membrane, nucleolus, chromatin distribution, segmentation and other morphological characteristics of the different stages of the cell life may be studied. If the ameba is observed in the reproductive stages, the nucleus will be seen dividing into four segments, and finally into four young amebæ, which differentiates this from the *ameba coli mitis*; which latter contains eight nuclei.

The amebæ are introduced into the intestinal tract through the mouth and stomach, but the acid gastric juices prevent their propagation. They pass on into the colon to gain lodgment at favorite points, namely, the ileocecal valve, hepatic and splenic flexures, and especially upon the *plicæ transversalis recti*. In most cases the inflammation begins first in the rectum and extends upward by continuity.

The author has endeavored to explain the periods of exacerbation and amelioration of symptoms, in the following ways:

First.—The *Entamoeba histolytica* is especially fond of feeding on juicy subepithelial structures, and in a given case, this particular crop or generation, within the plentiful surroundings, may become indolent and easily satisfied, and also less active in the process of sporulation.

Second.—The parasite may be in a state of encystation, during which period the amebæ remain dormant or non-pathogenic until finally a different generation produces a more active and phagocytic type.

Third.—Because of the presence of a greater or less number of bacteria of symbiosis, which, in the light of observation of most authorities, seem essential to the activity and virulency of the amebæ.

A further study of the problems of immunity may in the future yield information which will be of paramount importance in amebic dysentery, in reference to both the ameba and the symbiotic bacteria.

This disease is most often contracted through drinking water, raw vegetables, and fruits.

Flies and other insects are possible means of transmission,

It can also be developed through contact, as from the use of syringe tips which had been used in treating an amebic case and not sterilized.

When making a microscopical examination of the feces for amebæ, the following technic will be helpful to the inexperienced microscopist:

Warm the slide slightly. Secure a small bit of the mucus from the stool and place upon the slide. Cover with a cover-glass quickly, and press it gently until the material is thinly distributed. Examine at once with the one-sixth or the oil-immersion objective. This should be done as rapidly as possible, since the amebæ retain motility for only a short time in temperatures much lower than body heat. If now they cannot be found, apply warmth by holding an electric-light bulb to one side of the stage. They may then be seen. Never be positive that the amebæ are not present though not found. They may be in a state of encystation in the tissues, and only after an acute exacerbation of the disease, will they be found.

A still better plan, and the only accurate way, is to examine the scrapings of the ulcerated mucous membrane. This method should always be practiced, when possible, after a saline catharsis.

The most important of the associated organisms are the *Streptococcus*, *Staphylococcus*, *Bacillus coli communis*, *Trichomonas intestinalis*, *Paramæcium*, *Cercomonas intestinalis*, *Lambia intestinalis*, *Bacillus pyocyaneus*, and others.

**Pathology.**—Pathological lesions are almost always confined to the rectum and colon, but occasionally the ileum may become involved.

Appendicitis is quite common.

The mucosa appears red and congested, and covered with mucus, usually tinged with blood.

The infiltration and edema now invade the submucosa, necrosis of the overlying mucous membrane takes place, and the amebic ulcer is formed. This necrosed area may be oval or irregular in shape and appears to project over the level of the mucosa.

The amebæ gain access into the submucosa through the interglandular spaces and carry with them the associated organisms. Here they set up an active inflammation, and produce eecchymosis

and swelling of the glands. The number of the amebæ in the submucosa is great, since they prefer this juicy subepithelial tissue, no doubt because they find food more easily. When they get

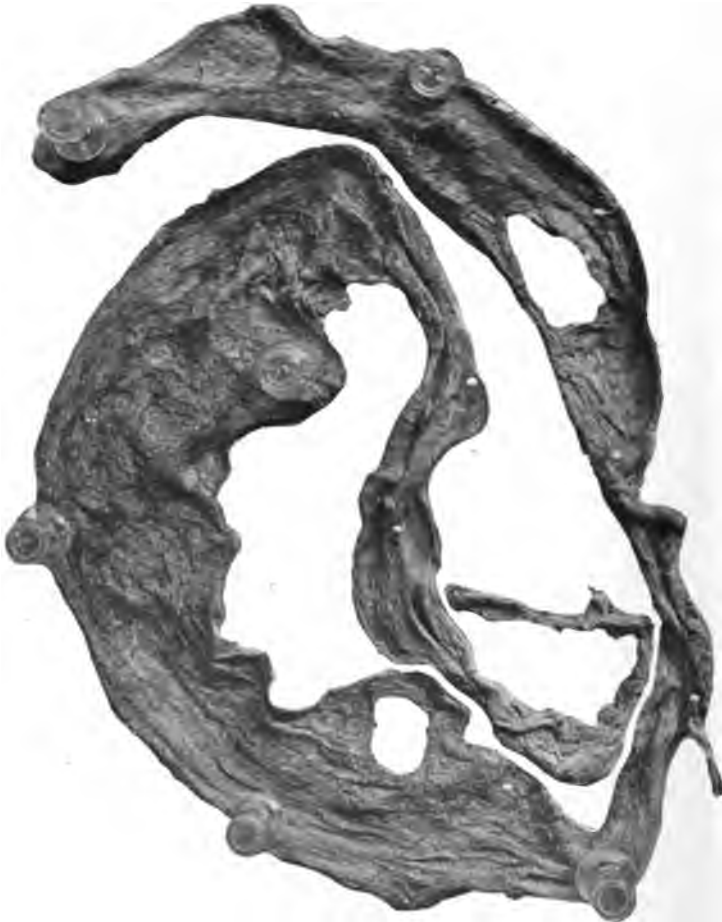

Fig. 176.—Slough of mucous membrane, 28 inches in length, from a fatal case of dysentery. Photograph of specimen from one of Jelks' cases.

into the submucosa, their presence excites a reactive inflammation at once.

It is important to note here that the bacteria of symbiosis play a very important part in the inflammation just described. Necrosis now takes place in the inflammatory area, and sloughing

follows. In grave and fatal cases this undermining process, so to speak, may become so extensive, and the congestion so great, that large areas will necrose and slough. The author has preserved one specimen of this character twenty-eight inches in length (Fig. 176).

The muscular coat of the bowel offers greater resistance to the amebæ, so that they seldom invade it. Occasionally, however, this undermining process will extend into the intermuscular tissue, and produce the same results as before described.

In this way the larger and deeper ulcers form (Fig. 177).

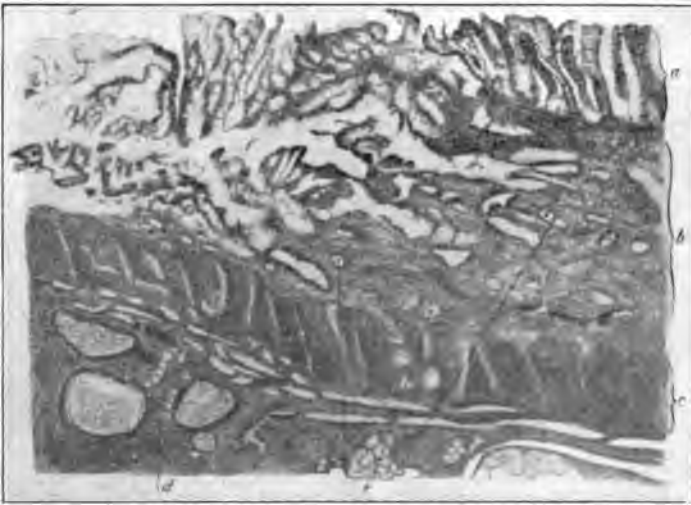

Fig. 177.—Edge of intestinal ulcer. (Toluidin-blue and costn. Beck 1 inch. Oc. 3).—  
Courtesy of Dr. H. F. Harris, Atlanta, Ga.

- a. Mucous coat which projects over ulcer at f.
- b. Submucosa.
- c. Circular layer or muscle-fibers.
- d. Tissues of mesocolon.
- e. Amebæ in dilated lymph-spaces.

The involvement of the rectum in one case was so extensive that the new scar-tissue produced an almost complete stenosis. Higher up the ulcerations usually cover a smaller area. A sharp-edged, clean-cut ulcer results, or a simple erosion only may be observed. This ulcer may involve the greater portion of the thickness of the wall of the bowel, but the undermining is not so extensive and the thickening that results lower down is not so marked here. One post mortem revealed nine distinct perfora-

tions in the splenic flexure, which produced sudden death when the loose attachment of the omentum was broken by gaseous overdistention.

The author wishes also to call attention to certain spots and lines which he considers almost diagnostic when present. By careful examinations with the proctoscope small red papular spots may be seen dotted about among the already well-defined ulcers. Perhaps on the following day the red spots will show a little

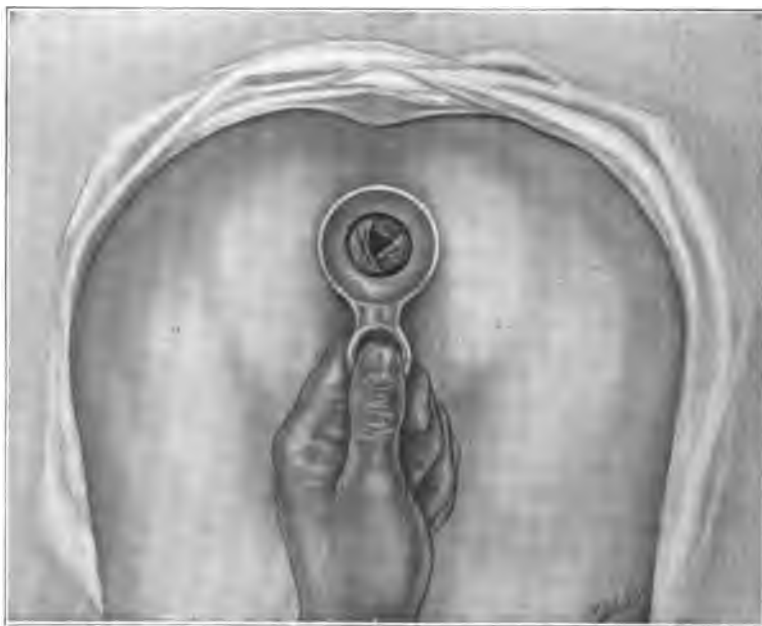

Fig. 178.—Dysenteric ulceration on the valves of Houston.—After Tuttle.

white or yellow point of necrosis in the center. Upon the next examination an ulcer will be seen to have taken its place.

In another instance a few circinate or ringworm-like lines in the mucosa, a picture which is not observed in other forms of intestinal infection, will be seen. These lines or ulcers are chiefly submucous, but sooner or later break into the undermined ulcer, and may then assume any shape. New lines will form, however, to tell the story (Fig. 178).

The author has also observed small openings at points along



the courses of these circinate lines leading to extensive submucous ulcers. At other times the intestinal mucosa presents only a few circinate lines overlying the subepithelial ulcers, while the remaining mucosa presents a red granular appearance.

In a few cases (unmistakably amebic) the disease appeared to be only a hypertrophic proctitis, or a proctosigmoiditis, and in others the mucosa appeared puffy or edematous.

It is very probable in my opinion that some of these conditions were concomitant and due to associated conditions, especially collateral infections. This important fact must not be lost sight of: the pathological conditions produced by the ameba, as also the amebæ themselves, are mostly submucous; while the collateral infections and the conditions produced by them are, as a rule, superficial.

Amebæ have been found free in the peritoneal cavity, and in other parts of the body, especially the liver. Here, when unassociated with collateral organisms, the parasites are non-pyogenic. A true amebic, unassociated infection in the liver would mean simply that; and not an abscess cavity filled with the most offensive pus, as is so often found. Perhaps, in almost all cases, amebæ have been conveyed into the liver, and but for the fact that they were unassociated with pyogenic organisms, abscesses would surely follow. Hepatic abscess complicates probably twenty per cent of all chronic amebic infections; however, exact statistics cannot be obtained.

Councilman found this complication in six out of eight autopsies.

Strong and Musgrave found it in fourteen out of ninety-seven autopsies.

Out of a series of twenty-five cases treated by the author in 1908, four were complicated by hepatic infections. In two of these cases the diagnoses were verified by operations. In one a large abscess of the right lobe was found, and in the other the right lobe was inflamed and firmly adherent to the omentum and hepatic flexure of the colon. A cholecystitis was also present, and required drainage for six weeks.

The infections may be carried into the liver in two ways:

First, and most probable, through the portal vein, which has often been found infected (Plate IV).

Second, by transmission through the intestinal wall.

Craig claims that the kidneys often present the lesions of acute parenchymatous nephritis.

**Symptoms.**—In the more virulent or malignant cases the onset is usually sudden, and may or may not be ushered in with a rigor. The attack is preceded by a period of malaise, often accompanied by constipation. An attack of acute indigestion often precedes this form of dysentery. The patient may have six to forty bowel movements during the first twenty-four hours, usually sero-sanguineous in character. Prostration is early. By the second or third day considerable blood and pus begin to appear, the latter being very offensive in odor. Prostration increases with the further absorption of toxins. Temperature usually rises to 102 to 103 degrees F., and is of the irregular remittent type. Delirium may be pronounced. General abdominal pain and tenesmus with tympanites and tormina are prominent. The facies abdominalis denotes suffering and anxiety. The nose is pinched, and the upper lip is retracted; and the condition now is a grave one. The thighs are flexed upon the abdomen and legs upon the thighs in such manner as to relieve pressure upon the abdominal viscera. Considerable tenesmus precedes and accompanies all bowel movements and may follow for several minutes, though as a rule a greater or less relief follows the passage of only a small amount of bloody mucus. Later the more offensive discharges, containing greater quantities of mucus, pus, and blood, with perhaps mucofibrinous casts, or mucous membrane sloughs, indicate necrosis.

The above symptoms are soon followed by delirium, subnormal temperature, rapid, feeble pulse, clammy perspiration, glazed skin, collapse, and death. If, after the sloughs are passed, the patient survives the sepsis and toxemia, and healing of the ulcers follows, the process is a slow one. These ulcers are finally filled with granulation tissue and fibrinous material, which contract, causing more or less stenosis. The symptoms of sepsis and toxemia from the absorption of necrotic material and toxins very gradually diminish until the patient is able to resume his regular occupation.

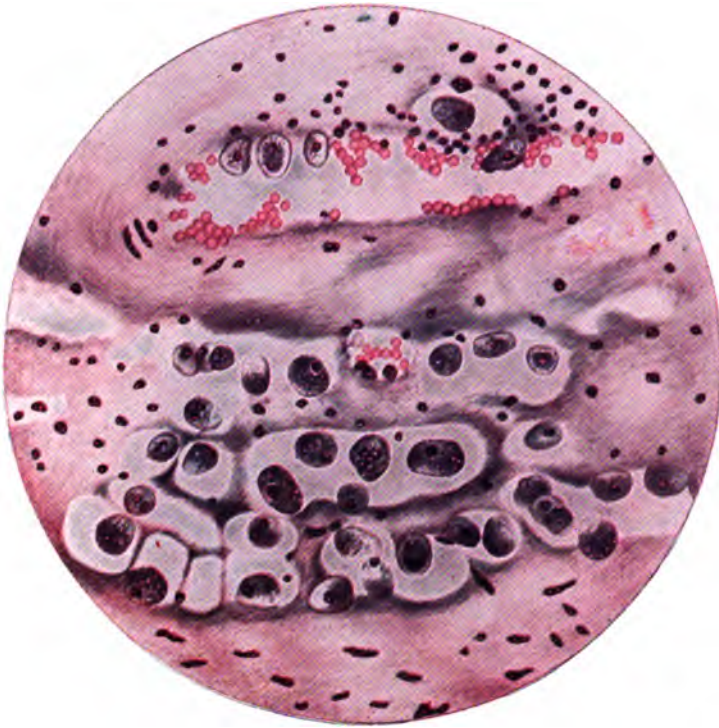

PLATE IV.

Section of intestine just below ulceration. (Toluidin-blue and eosin. Beck,  $\frac{1}{4}$ , Oc. 3.) In upper portion of the field a large vein is seen; the wall of the vessel which is nearest the ulceration is being infiltrated with small cells, and amebæ are breaking down; both red and white cells and amebæ are seen within the lumen of the vessel. In the lower portion of the field many amebæ are seen—some in the tissues, and others in the lymph-spaces and lymph-channel.—Courtesy of H. F. Harris, Atlanta, Ga.

[www.libtool.com.cn](http://www.libtool.com.cn)

The following case reports will be helpful:

CASE 1.—Name, Dr. —; age, 36 years; race, white; occupation, physician; family history, negative; previous state of health, good, until six months previous, during which time he suffered a rapid decline. Symptoms: Lost thirty or forty pounds in weight; complained of slight colicky pains over course of colon; troubled with loose fermentative diarrhea; inactive liver; coated tongue; temperature 99 2/5° F.; pulse, 60; skin, dry and muddy; slight tenderness on pressure over cecum, hepatic and sigmoid flexures; pronounced melancholia, insomnia, and malaise were present. Had not noticed passages of mucus from bowel but spoke of a very offensive odor. Proctoscopy revealed a considerable quantity of sanguino-purulent mucus in the rectum, and the rectal mucosa was covered with same, mixed with some light-brown fecal material. Small circinate lines and punctate ulcers were seen on the rectal walls and valves of Houston. A mild granular proctosigmoiditis was noted. Microscopic examination revealed *Entamoeba histolytica*, *Trichomonas intestinalis*, *Paramoecia*, and others.

Diagnosis: amebic dysentery.

CASE 2.—Name, Dr. —; age, 53 years; race, white; occupation, physician; family history, negative; previous health, good, until 23 years of age since which time he has never been well. Symptoms: At the age of 23 suffered a very severe attack of dysentery, and for a long time, hope of recovery was despaired of. Later a change of climate seemed to contribute to his slow but apparent recovery. After returning home suffered a relapse. Since that time has suffered abatement and acceleration of symptoms; alternating attacks of diarrhea and constipation; suffering now from profound melancholia and insomnia with suicidal inclinations. Temperature, subnormal; pulse, 65; tongue, dry and coated heavily, round and thick; skin, inactive and muddy; liver, enlarged, extending three inches below costal border and tender, probably the seat of a large abscess. Pain on pressure over entire course of colon, especially over cecum and sigmoid flexures. Furunculosis (staphylococic) over entire body; atonia gastrica with dilatation; kidneys, normal.

Proctoscopy: rectal walls very much thickened, scarred, and stenosed, this last condition observed at rectosigmoidal juncture also; red granular hypertrophic rectosigmoiditis. The characteristic ulcers, previously referred to, were found beneath a coating of offensive blood-tinged mucus, which was mixed with pus. Microscopic examination revealed large active phagocytic *Amoeba histolytica*, *colon bacilli*, *Trichomonas intestinalis*, *Cercomonas intestinalis*, and other symbiotic bodies in great numbers. The blood examination, made by Dr. Krauss in this case, shows the following: 3,940,000 red cells, 75 per cent hemoglobin, 13,700 white cells, of which 74 per cent were polynuclears and 3.3 per cent eosinophils. The opsonic index failed. The bacteria isolated from the pustules were *Staphylococcus albus* and a single colony of *aureus*. I regard the blood condition to be one of secondary anemia with mild coccus infection, and the moderate eosinophilia is probably due to the intestinal condition.

The furuncles were healing nicely when I last saw the patient, and he expressed himself as feeling greatly improved.

Diagnosis: amebic dysentery.

The author looks with suspicion upon any case of dysentery or diarrhea recurring or relapsing, which has failed to respond promptly to treatment.

Dysentery and diarrhea are not essential symptoms of the existence of amebiasis, though this is contrary to the generally accepted theory. In many cases the patient will complain of recurrent diarrhea which has existed for months or years. These attacks are accompanied by passages of mucus, usually considerable in quantity, and occasionally stained with blood. The patient complains of almost constant pain or discomfort in the left iliac fossa, and when the lower rectum is the seat of considerable ulceration, pain at the end of the spine and in the rectum is felt. This symptom is momentarily relieved by evacuations.

A case from the Mississippi Delta, reported by me to the American Proctologic Society, had most violent symptoms from the onset. On the fifth day a large slough of mucous membrane (Fig. 176) was passed *en masse*. Thirty-six hours later the patient died.

Most of the chronic cases will give a history of having lost much weight, perhaps twenty to fifty pounds. Many have symptoms of interest to the stomach specialist, and to the neurologist.

**Complications and Sequelæ.**—These are very numerous indeed.

Of 1537 cases of diarrhea in Egypt, only 406 were uncomplicated.

Hepatic abscesses were found in six out of eight autopsies by Councilman. In four of these they were multiple.

Strong and Musgrave found hepatic abscesses in 14 out of 97 cases. The author, as previously stated, found liver infections in four out of twenty-five cases.

The vermiform appendix has been found to be involved in fully ten per cent of chronic cases by the author.

Among the other complications most frequently occurring are: perforations, extensive sloughs, hemorrhages, fibrosis of the valves of Houston, rectal stenosis, adenomata recti, cholecystitis and jaundice, perirectal abscess, hemorrhoids, fistula, pneumonia, pulmonary abscess, pleurisy, bronchitis, nephritis, portal thrombosis, cerebral and meningeal emboli, gastritis, atonia gastrica, melancholia, which is often profound, and in many of my cases more

or less extensive skin lesions and nervous symptoms have been observed. More especially have these complications been seen in chronic cases, but these are considered of sufficient importance to deserve the following special mention:

Dr. John L. Jelks' report:

*Skin and nervous manifestations and complications referable to blood contami-*



Fig. 179.—Photograph of case, Mr. A. R. C.

*nation and poisoning of the central nervous system, to which special allusion seems apropos.*

For the past 13 years the author has interested himself in the unmistakable relationship between amebiasis and various skin and nervous manifestations of varying character and severity, and was the first writer to allude to these symptoms and complications in several monographs written during these several years.

Many of these manifestations are so vague as to escape other than the scrutinizing eye, and varying thus from this mild coccus infection or toxic manifestation above referred to, he has observed the most distressing urticarial, erythematous, and desquamative dermatitis, and in the first part of April, 1910, the author presented before the Tennessee State Society a patient who was a well-defined pellagra and who had suffered amebic infection for three years.

The object, in referring to these manifestations, is to show the grave complications of this character, which may associate themselves with amebic ulceration and collateral infections.

Case Report: Mr. A. R. C., age 40, American; occupation, lumberman. Father living; health, good; age 71. Mother died of tuberculosis at the age of 36.

About twenty years ago, the patient became overheated and began having indigestion, diarrhea, and dysentery. Fifteen years ago, suffered a very severe dysenteric attack. Again five years ago, patient began passing large quantities of mucus, which at times was mixed with blood and pus.

His symptoms grew progressively worse, and on December 8, 1911, he was brought to me for examination. His emaciation was extreme and general condition bad. His blood picture denoted anemia and toxemia.

Proctoscopy: The rectum and sigmoid were eroded and contained offensive mucus, blood, and pus. The typical amebic ulcers were everted, and the material revealed large numbers of *Amoeba histolytica* and symbiotic bodies.

The amebæ contained blood-corpuscles and blunt, rod-shaped, nonmotile bacilli, distributed without order in great numbers. Colonic irrigations were begun and patient's diet restricted to albumin and buttermilk, but the patient's condition grew steadily worse.

On December 21, 1911, appendico-cecostomy was performed, and irrigations were begun the following day. Improvement was noticeable, and a more liberal diet permitted, which was followed by a relapse and profound toxemia. In two days marked improvement again was noted, the result of persistent irrigations with large quantities of salt solution and restrictions of diet. The appended illustration was taken at this time (Fig. 179).

He no longer passes mucus or blood; he is up from four to six hours each day.

The case is one of amebiasis associated with the series of symptoms-complex, known as pellagra.

The prognosis must appear grave indeed; yet, great improvement has resulted from the treatment.

Dr. Marcus Haase's report February 22, 1912:

In regard to the patient I saw with you, Mr. A. R. C., at the City Hospital on December 10, 1911, I find that I made the following record: There was an erythematous-squamous condition on the backs of the hands, elbows, nose, the left side of the neck, and about the ankles. All of these lesions were sharply defined, in no instance gradually extending into the normal skin, and were all of a distinctly pellagrous character, and I was at that time quite satisfied that the disease from which he was suffering was unquestionably pellagra.

I saw this patient again on February 18, 1912, and at that time the lesions had entirely disappeared. The skin, while atrophic, was not as markedly so as I



should have expected in a case of this severity. While we might expect all acute lesions to disappear in this length of time, I should expect to find an atrophic condition more marked than I found in this case.

Dr. W. C. Sommerville's report:

Mr. A. R. C., male, age 40 years. Five or six years ago began with weakness, especially in legs, and indigestion, a sensation of heaviness in gastric region. Has been unable to do a whole day's work during this period. Two years ago weakness of legs was more decided and has progressively increased since. Vertigo for past two or three years. Diplopia for past eighteen months. In September, 1911, had an eruption on backs of both hands, which had the appearance of sunburn. Says he has been sunburned several times. Does not know how long his limbs have been atrophied.

Mental condition: Dull, memory bad, and rather irritable and depressed, answers slowly, and is unable to recall his symptoms with any degree of accuracy. Patient presents a condition of a very decided general emaciation, but in addition, there is more or less general muscular atrophy, especially marked in the small muscles of both hands, but involving to some extent almost the entire musculature. Pupils dilated but equal, and react to light and by accommodation. External ocular muscles negative.

Diplopia and nystagmus present. Sensory branch of fifth nerve negative; some weakness and atrophy of muscles, supplied by motor branch. Slight weakness of facial muscles, hearing fairly good, and air conduction greater than bone conduction. No difficulty in swallowing. Movements of tongue weak, and tongue slightly atrophied.

There is decided loss of power in all movements of the four extremities, especially marked in small muscles of both hands, which are decidedly atrophic. There is no paresthesia, and no sensory disturbances of any kind, except tingling and numbness over anterior surfaces of both thighs, which show a hyperesthesia, and hypalgesia; slight tingling and numbness of hands and feet. Has poor control over sphincter of bladder. Slight incoordination manifested in making nose-finger test.

No wrist-jerk was obtained, either right or left. Both elbow-jerks were brisk and equal. Both knee-jerks were brisk and equal. The ankle-jerks present and equal. The plantar reflexes were extensor, both right and left. External malleolar reflex not obtained. Abdominal reflexes present.

The symptoms, which this patient presents, indicate extensive degenerative changes in the cells of anterior horns and the motor nuclei; of some of the cranial nerves; and degeneration of the crossed pyramidal tracts; and beginning degeneration of the posterior columns of the cord.

Statistics from all sources show that perhaps twenty per cent of all cases are complicated by hepatic infection. The right lobe is most often involved. The author believes this complication will appear less frequently in the future, owing to better diagnostic facilities, care, and treatment by the internist.

Perforations may occur along the course of the colon at any point

between the rectum and appendix. Perforative appendicitis has been noted.

Perforations occurred in 85 out of 580 cases selected by Beranger and Feraud.

Stenoses have been observed in a large per cent of chronic cases usually in the rectum and sigmoid. When fibrosis of the rectal valves is observed, it is a grave obstacle to the complete cure, owing to interference with drainage and local treatment.

Hemorrhoids, though frequently noted, are not serious complications as a rule.

The other complications mentioned above should be borne in mind and treated when they occur.

**Diagnosis.**—This is rendered easy by means of the microscope, all doubt being removed by finding the *Entamoeba histolytica* in the stools, or in the material curetted from the ulcers in the rectum and sigmoid.

**Prognosis.**—The prognosis in amebic dysentery is likewise much graver than in the acute catarrhal form. It may be said to depend upon several things:

1. The previous state of health of the patient.
2. The hygienic condition of the patient's surroundings.
3. The efficiency of the treatment employed.

In the United States the total number of deaths from all forms of dysentery in 1850 was 20,556, a per cent of 6.32 of the total mortality.

In 1880, out of 756,893 deaths, 10,825 were from dysentery.

**Treatment.**—The treatment of dysentery will be discussed under the heads: (a) Prophylactic, (b) Dietetic, (c) Remedial and Operative.

**PROPHYLACTIC.**—Strict attention should at all times be given to the hygienic condition of surroundings. Remove and avoid as far as possible the causes of dysentery. Cases should be isolated when it is possible to do so. All excreta should be carefully disinfected and deposited where the water supply will not be contaminated. The country practitioner, living where there is no sewerage system, should never neglect to caution those attending the patient to deposit the excreta in a hole dug for the purpose as far removed from

the water source and garden as possible, after first disinfecting thoroughly [www.libtool.com.cn](http://www.libtool.com.cn)

If a person, knowing the danger, were to deposit the excreta of a dysenteric patient in a garden, it would be inexcusable. The author has, however, seen this done by some who had never suspected danger in so doing. In the country, and in small towns, without sewerage, small closets are usually found in or near the gardens, and are often made sources of fertilizing material for the growth of vegetables. It is the duty of the physician to educate his patients in regard to all dangers resulting from such gross unsanitary practices. Wells and cisterns are contaminated much more often than the average layman suspects. When the source of the drinking supply is at all questionable, the water should be boiled before drinking.

Overcrowding and poor ventilation should be prevented. The care of the room occupied by the patient is important. Unnecessary furniture, such as curtains, rugs, carpets, etc., should be removed. Disinfectants should be used at regular intervals. Linen should be changed daily. Bedpans, commodes, drinking cups, etc., should be disinfected thoroughly.

**DIET.**—Diet is as important as any other matter in the treatment of dysentery. During this period of acute intestinal symptoms it should consist of buttermilk, whey, egg whites, barley water, and perhaps one of the standard malted milk foods for infants.

In all cases select a diet which is digested as far as possible in the stomach, and which has little waste. Food is best given at intervals of one to two hours in acute cases. Plain sweet milk may be diluted with barley or rice water, lime water or Vichy, if imperfectly digested.

In the bacillary form of dysentery and in those cases in which this form of infection is suspected of much part in the inflammatory process, milk in any form should be eliminated for a safe period of time, and the diet restricted to albumin, whey, barley water, and abundant sterile water. In these cases animal broths are very liable to produce a rich media for the bacillary growth.

While fruits in general are interdicted, the juices of oranges, lemons, and pineapples have not given particular disturbance in

most cases in which they have been used, especially as palatable vehicles for albumins.

During convalescence in all forms of dysentery and for chronic cases, the author prefers buttermilk, whey, and eggs. In some cases tender portions of turnip tops, mustard, spinach, and asparagus tips have been given, and were relished by the patient. It is however, questionable as to the advisability of giving the patient much vegetable diet.

In cases of amebic dysentery the author is especially partial to a diet of milk and egg whites. The eggs may at times be prescribed in large quantities, from eight to fifteen per day. They can be ordered raw, mixed with milk, or in the form of fruit-albumin. The last is made by stirring the white of one egg into a glass half full of crushed ice, then flavor with orange or other fruit juice. Diffusible stimulants, such as champagne, sherry wine, or whiskey, may also be added to the egg mixture when cardiac weakness and adynamia are present.

The albumin may also be mixed with sweet milk, or sweet milk with lime water in the form of a milk-shake, to which may be added the alcoholic stimulants, if no contraindications exist.

Buttermilk is an especially favorite diet. Its acid properties make it desirable.

The articles of diet which are contraindicated are all dishes highly seasoned with pepper, cinnamon, nutmeg, etc. Vegetables, especially the raw varieties, pork, salt meats, veal and fish, saccharine foods, fried foods, nuts, oatmeal, and fruits, other than those mentioned, should also be interdicted.

REMEDIAL.—The medicinal treatment of dysentery is a most interesting subject. A great number of so-called specifics, and much-praised remedies, have been handed down to us, but most of them have proved so unsatisfactory that it is no surprise that most of the present-day suggestions are greeted with a certain amount of skepticism or personal prejudice. The systemic treatment as a cure for dysentery is erroneous. It is a local disease and therefore requires local treatment. This is certainly true with reference to immediate pathology, but other remote pathological conditions may require constitutional treatment.

The ameba is a very low form of organic life and is very easily

killed or rendered inert. The fact remains, however, that the parasites are embedded in the tissues in such vast numbers as to make their destruction difficult. Certainly any chemical which is given by mouth, after passing through the stomach and small intestines, can possess little parasitic effect when it reaches the lower colon, sigmoid flexure, and rectum. Therefore, our chief reliance must be placed in local applications, which are used for the following purposes: namely, that of washing away the pus, mucus, and débris, and at the same time the amebæ and other pathogenic organisms, also that of antisepticizing the bowel contents and walls, that the further growth and development of the pathogenic organisms will be inhibited.

It is also important to remember that the remedies selected should be those which will destroy the greatest number of organisms beneath the lining membrane of the bowel without destruction to the tissues themselves.

In the earlier stages of acute dysentery the patient should be put in bed, and absolute quiet enjoined. Chilling draughts of air are to be cautiously avoided, since they are apt to increase the congestion of blood toward the internal viscera. Bathing the patient with warm water, vinegar, or alcohol will often give great comfort by relieving the burning sensation in the skin. The perianal region should be sponged frequently with an antiseptic wash, such as a mild boric acid and formalin solution, and dusted with some mild antiseptic powder, as equal parts of boracic acid and aristol. An ointment of similar composition may be used instead. Applications of heat or cold to the anal region will often relieve the burning and tenesmus in the lower rectum. The hot hip-baths also have been very helpful in relieving this condition.

In the more severe cases the constant application of ice bags over the left iliac region gives comfort. Hot fomentations are sometimes to be preferred, but in the majority of cases, the ice bag is better.

The severe griping and tormina are relieved quite readily by hot turpentine stupes or by large flaxseed-meal poultices. These may be used just as frequently and for as long a period as needed.

*Laxatives.*—Occasionally absolute rest and strict diet are all that are needed to relieve the patient, but it is in most cases best to ad-

minister some mild laxative to remove the contents of the bowel, which acts as both a mechanical and chemical irritant.

Castor-oil and magnesium sulphate, to the latter of which may be added dilute sulphuric acid, are the most popular remedies for this purpose. The salines, by their hydragogic action, deplete the inflamed mucosa and wash away many of the infecting micro-organisms. It must be remembered, however, that all purgatives act as irritants to the intestinal mucous membrane in a greater or less degree, and their use must be guarded with judgment. In some cases they would be harmful. If there has been much diarrhea and the stools are copious and thin, purgatives are contraindicated.

When to repeat a purgative is another question that should be considered with care. Often much harm is done in this way.

Calomel, or calomel with ipecac, is often ordered in small doses for a dry, furred tongue, and inactive liver with foamy acrid discharges. Our aim in giving calomel is not only that of producing the antiseptic action of bile, but also, by depleting the liver, of relieving the portal congestion; and this, in turn, the congestion of the veins about the rectum. The severe griping pains and tenesmus, the diarrhea, and restless condition of the patient, when present, must be relieved, or the outcome will be rapidly adverse. Opium is the remedy, either in the form of Dover's powders, paregoric, laudanum, or morphin. This last is no doubt the most popular form of the drug and is best used hypodermatically. The dose should be just large enough to keep the patient quiet and to relieve the suffering, but *never* sufficient to produce narcotism.

It must not be forgotten that opium may do *great* harm in some instances. If nature is attempting to throw off the putrid contents of the bowel in large, liquid stools, we should not give opium, for in doing so we are interfering with her efforts to relieve the condition.

A large number of intestinal antiseptics have been given internally for dysentery, the principal ones being calomel, lead acetate, zinc sulphocarbolate (in one-half to three-grain doses), salol, guaiaccol carbonate, bichlorid of mercury (dose, grains  $\frac{1}{120}$  to  $\frac{1}{150}$ ), and acetozone. These are all, however, given by the author with a feeling of uncertainty.

Those cases which begin with symptoms of cholera morbus, with

nausea and vomiting, and subnormal temperature, call for hypodermic injections of morphin sulphate, gr.  $\frac{1}{8}$ , and atropin sulphate, gr.  $\frac{1}{300}$ . To control nausea, may be given carbolic acid and tincture of iodine, each one minim, well diluted, by mouth. This is followed by calomel, gr.  $\frac{1}{8}$ - $\frac{1}{4}$ , and salol, grs. 2 to 5, with just a sufficient amount of hot water to administer same. In many cases of nausea the ideal treatment is that of stomach lavage, using very hot water, to which is added oil of cloves one-half to one dram per quart and briskly agitated.

In other cases cocain hydrochlorate (gr.  $\frac{1}{8}$ - $\frac{1}{2}$ ), or chloretone (grs. 5-15) may be given. Where there is much depression, warm enemata of normal salt solution may be given, or this may be given by hypodermoclysis. The effect is a dilution of the toxins and a reaction. A mustard plaster or hot turpentine stupe over the epigastrium is beneficial in these cases. If the temperature and pulse are not subnormal, the tormina, tenesmus, and burning can be allayed by enemata of cold water, the temperature of which should be regulated to suit the case.

When there is marked irritability of the rectum, the following suppository should be inserted before injections are made:

℞ Cocainæ hydrochloridi  
 Extracti stramonii  
 Extracti belladonnæ āā gr. ss  
 Olei theobromatis q. s.  
 Misce et fiat suppositoria, No. 1.

Sig.: Hold the suppository in the anal canal about one minute then press into the rectum with the index finger.

Kartulis claims that he found ipecacuanha to have an almost specific influence upon dysentery.

His method of administering this drug was to give a one-half grain injection of morphin hypodermatically and place a mustard plaster or turpentine stupe over the epigastrium. After half an hour twenty grains of pulv. ipecac were given, and this dose was repeated every half hour to one hour, until an ounce had been given.

Another method of giving this drug: Put 2 to 8 grams ( $\frac{1}{2}$  to 2 drams) in 500 grams (1 pint) of water and let stand two hours. This solution is filtered off and constitutes the first dose, or this is at times divided into two or more doses. According to Kartulis, this always produces emesis and diarrhea, but after a second or

third infusion, which is made from the remaining portion of the powder with the same quantity of water, has been taken, the vomiting and purging become less frequent.

If, after the third day's treatment with these infusions, the patient has not improved, another series of infusions with a fresh supply of ipecac should be given.

The author has mentioned this treatment *only to condemn it*. It has been known to produce death, and does not cure the disease. According to some authors, there is no reason for dysentery existing in the same world with ipecac and that this drug will even abolish an established abscess of the liver. Such is one of the curiosities of the statistics found in a recent article by McDill. I have administered large doses of ipecac daily for a week, then found the living amebæ in the bowel scrapings as if undisturbed by the drug. In all cases it is a cardiac depressant and lowers the physical resistance of the patient. It is a violent intestinal irritant. The powdered drug has also been found impacted in fatal perforating ulcers of the bowels. To my mind, therefore, its administration in this disease, by this method, is dangerous, adding insult to injury.

Its alkaloid Emetine Hydrochloride has been given by the author in  $\frac{1}{2}$  to 1 grain doses in perhaps two hundred cases, and with very certain and uniformly good results in so far as concerns the relief of symptoms and healing of the ulcers, yet, he has never cured a case of amebic infection by this treatment. They will and do have relapses, and recurrences of symptoms; therefore, the author concludes the remedy is deceptive, and the cases are carriers of the infection.

For the acute catarrhal type the elimination of irritating substances and free exosmosis, obtainable by the administration of Epsom salts, and enjoined rest in bed, with abstinence from all but the blandest forms of diet, will often suffice. In these cases, however, the injection of tepid water, containing to each quart, minims x to xx of formalin, and one tablespoonful of boric acid, may be necessary. This is often followed by the same quantity of cold water, or by the injection of 1 or 2 ounces of olive oil and one scruple of bismuth subnitrate. These injections can do no harm and are



surely destructive to the life and propagation and pathogenic properties of the [infecting agents](http://www.infectedagents.cn).

If the symptoms do not abate, and the patient does not obtain marked relief within the first few days from the use of the above-described treatments, pathologic conditions may be present which may require other forms of local treatment in the nature of topical applications.

A subacute catarrhal condition may supervene in which an astringent and antiseptic treatment will be required to complete the cure. For this purpose may be used the injection of a tannic acid solution, one dram to a pint of water, followed by the introduction of a suppository containing:

℞ Extracti belladonnae .....gr. ss  
 Extracti stramonii .....gr. ss  
 Thymolis iodidi .....gr. v.  
 Olei theobromatis q. s.  
 Miscet et fiat suppositoria No. 1.

Or the following ointment:

℞ Extracti belladonnae .....gr. ss  
 Extracti stramonii .....gr. ss  
 Thymolis iodidi .....gr. v.  
 Petrolati liquidi q. s.  
 Miscet et fiat unguentum.

If the disease assumes one of the more virulent types, and if the ulceration is extensive, still more radical measures should be sought in the high irrigation with the formalin-boric solutions. These, if possible, should be given through a recurrent tube (Fig. 180), since by this means only can a large quantity of the solution be used without distending the inflamed and ulcerated bowel to a painful or perhaps dangerous degree.

Four to eight quarts of this solution are usually required for one irrigation.

Some authorities are partial to the use of quinin solutions (1:5000 to 1:500) in cases of amebic infections. Among the advocates of this drug are Musgrave and Strong, and Osler. II. F. Harris, of Atlanta, says: "I used this treatment with great persistence in some of my earliest cases, but not in a single instance was there the slightest perceptible result. Injections of 1:100 to 1:300 watery

solution of bisulphate of quinin were somewhat beneficial in one or two instances.”

My own experience with these injections is in accord with that of Dr. Harris.

Hanes, of Louisville, treats these amebic infections of the colon with kerosene oil; the oil is poured into the colon while the patient is inverted.

The use of formalin solutions in the strength of 1:500 to 1:1000 has in the author's hands afforded the best results.




Fig. 180.—The Jelks soft-rubber recurrent recto-colonic irrigating tube. Courtesy of Dutro and Hewitt, Memphis, Tenn.

My study of the effects of this chemical has extended over a period of 12 years. I have relied not only upon clinical results obtained, but also upon the microscopical observations in demonstrating the efficiency of formalin. After only one or two injections with these solutions, I have been unable to find any living organisms in the bowels for hours afterward. This, it was observed, was not the case when other solutions were used.

Rapid healing of the ulcers was always noted while continuing the irrigations of the formalin in the above-mentioned strengths.

To be certain of the effect of this drug, its use was discontinued

for the time being, and such irrigations as plain water (warm or iced), normal salt, and quinin solutions were substituted. In every instance the ulcers re-formed, and both amebæ and bacteria of symbiosis were found again in the microscopical examinations. Upon returning, however, to the formalin irrigations, these micro-organisms disappeared, and the ulcers began the process of repair. Thus the author has concluded that this chemical, judiciously used, is really the most effective in the destruction of the amebæ and associated organisms, and most valuable in the treatment of dysentery.

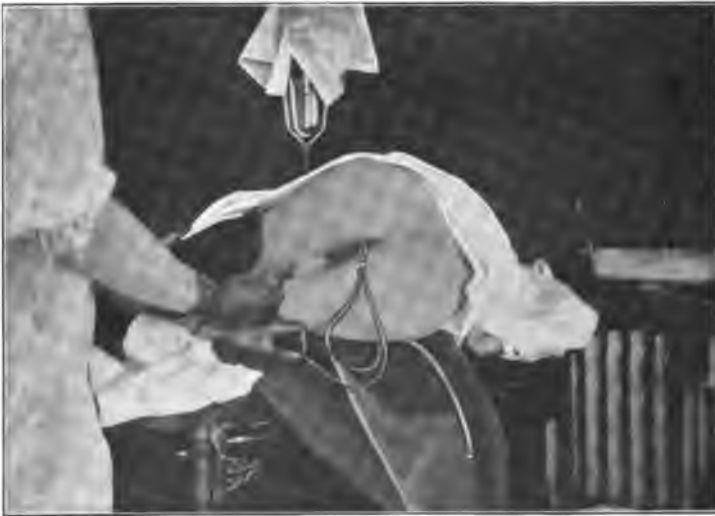

Fig. 181.—Exaggerated Sims' position, showing method of high irrigation of colon through Jelks' recurrent tube.

During the past two years I have been giving iodine and thymol, internally, with gratifying results. The latter is especially valuable in that it destroys not only the amebæ but other intestinal parasites. I find solutions of iodine and of thymol of especial value when used as colonic irrigations. This method appeals to me most when the solutions can be applied through the cecum.

Seven grains of thymol dissolved in a pint of water, and filtered, give a solution whose strength is approximately 1:1000. A solution of this strength may safely be used in irrigating the colon through the cecostomy opening. This solution should be followed by a solu-

tion of magnesium sulphate or sterile water. Thymol solutions thus used are analgesic and may relieve the distressing neuralgic pains and tormina in the colon. Relief of these unpleasant symptoms may also be given by the use of chloretone solutions. The injection of olive oil and bismuth almost instantly relieves the painful effects of these solutions.

The dangers of overdistention of an inflamed and ulcerated colon are difficult to overestimate. To avoid this, the author has devised a double or recurrent colon tube, made of soft rubber, and constructed in such manner as to facilitate its introduction through the rectum and into the sigmoid. The tube having been properly inserted, it is an easy matter to change the position of the patient, and by so doing irrigate the entire colon (Fig. 181).

In some instances the tube is obstructed by the rectal or recto-sigmoidal valves, which may necessitate its introduction through the sigmoidoscope or proctoscope. In chronic cases especially has this difficulty been encountered, since in these a fibrinous infiltration of these structures often exists, rendering almost impossible the use of an ordinary rectal tube. To ascertain whether or not the tube had coiled in the rectum, the operator can introduce the index finger, well anointed with the lubricant given below. After several unsuccessful attempts have been made, the proctoscope should be introduced and the tube inserted through it as shown in Fig. 182.

A lubricant of the following formula is preferred by the author:

℞ Pulveris tragacanthæ.....	gr. cclxxxiv
Phenolis .....	℥ cexl
Glycerini .....	ʒij
Aquæ destillatæ q. s. ad.....	Oij
Misce.	

Shake up gum with enough alcohol to make thick paste. Add acid and glycerin. Shake well and add water all at once. Agitate vigorously.

Dr. Louis LeRoy, of Memphis, has suggested the use of phenol-sulphonate of copper solutions for the colon irrigations.

The author has used this chemical in the treatment of a number of cases, but is unable to state its exact degree of efficiency. It is a very powerful parasiticide, and its use is advised alternately with the formalin-boric solution. The strength of the copper solutions is 8 to 10 grains to each quart of sterile water.

Ichthyol (10 per cent solution) applied locally to the mucous

membrane, or gauze, saturated with the same solution, packed in the rectum, ~~has seemed to exert a~~ beneficial effect.

It is well to mention here that an antidysenteric serum has been

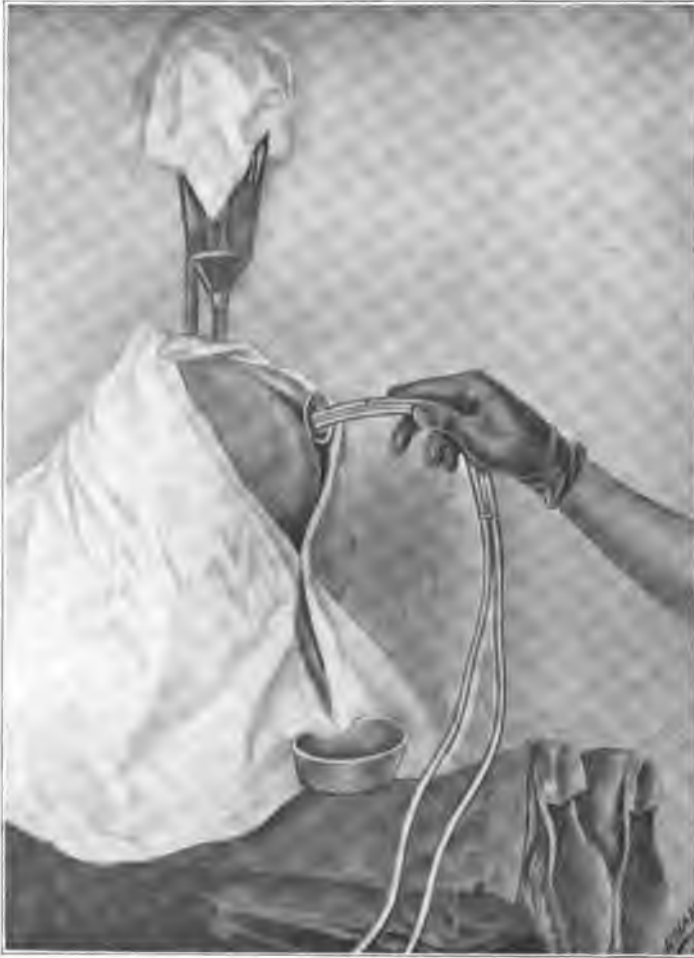

Fig. 182.—Position of patient for proctoscopy. Proctoscope introduced to facilitate the introduction of the colon tube.

very highly recommended in the treatment of the malignant bacillary type of dysentery.

My recent experience justifies the mention of mixed vaccines

(Van Cott) in some of the chronic cases, with skin infections and associated furunculosis and pruritus, or of the autogenous bacterins, as advised by Murray, of Syracuse, who has made an exhaustive study of the bacteriology in some such cases.

### **CHRONIC OR SECONDARY AMEBIC DYSENTERY**

All subacute or chronic cases of dysentery depend for their symptoms upon an ulcerated and inflamed condition which will not yield to treatment.

These cases have exacerbations and amelioration of symptoms. They often complain of constipation, which may extend through a period of weeks or even months. It is in these subacute and chronic cases that the proctologist is most often consulted.

Such remedies as nitrate of silver, grains 30 to 60 to an ounce of sterile water, or a 20 per cent solution of argyrol, are applied, after first cleansing and antisepticizing the rectum and sigmoid with pledgets of cotton wrung out of hot formalin-boric solution (Fig. 183).

A 30 per cent solution of lactic acid has also been used to cauterize the ulcerative areas.

After these applications have been made, the bowel is sprayed with some neutral or alkaline solution to neutralize the excess of the silver or other solution used (Fig. 184).

The bowel surfaces are then dried. Now, the insufflation of some non-toxic antiseptic powder, such as equal parts of boric acid and aristol, is advised.

The symptom of iodism is an unpleasant one and may be readily produced by the instillation of drugs containing iodin into the rectum. Because of this, these remedies, such as aristol, bismuth-formic-iodid, and iodoform, have appeared most effectual when used just to the point of tolerance.

When the amebic infection has become very chronic, or has extended into all parts of the colon beyond the use of the local measures just described, appendico-cccostomy should be performed, and the same fluids previously suggested should be used in irrigating, through the appendico-cccostomy opening. The fluid is allowed to pass out through the rectum into the catch basin, or a drainage tube may be inserted into the rectum.

This plan of treatment was first advised by Dr. E. A. Corsons, of Savannah, [www.libtool.com.cn](http://www.libtool.com.cn)

In 1898, Dr. H. F. Harris stated that some years before Dr. Cor-

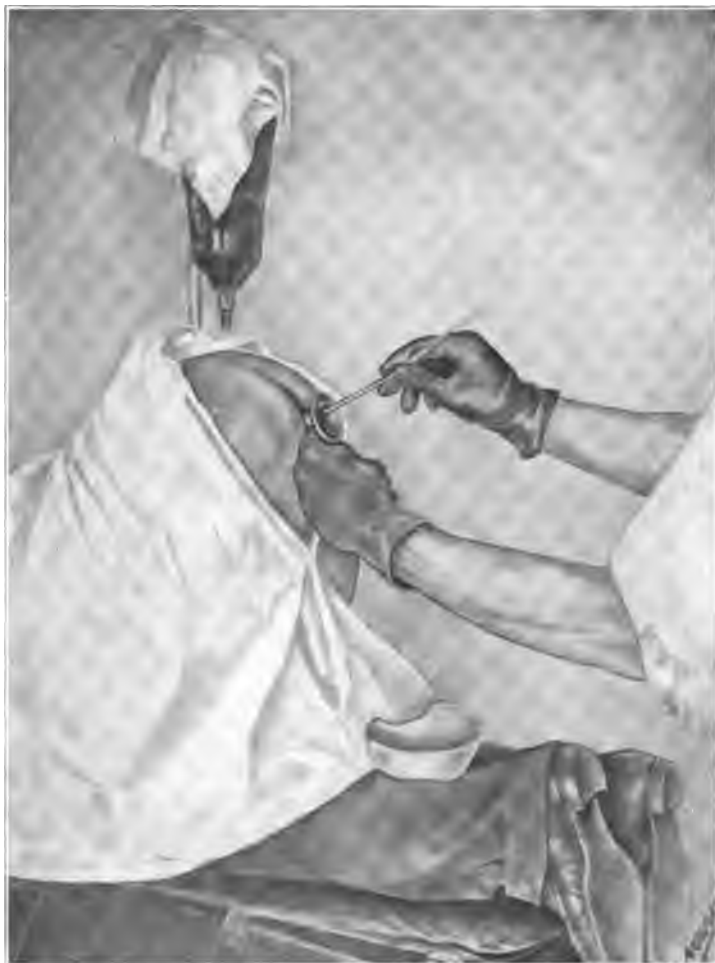

Fig. 183. -Method of application of silver and other solutions to the ulcerated surfaces of the rectum and sigmoid.

sons made this suggestion to him. Irrigations of the bowel with hydrogen peroxid through the artificial opening, thus established, were also advised.

About the year 1901, Dr. Robert Weir, of New York, while performing a colostomy for amebic dysentery anchored the appendix and irrigated through the stump with a saline solution.

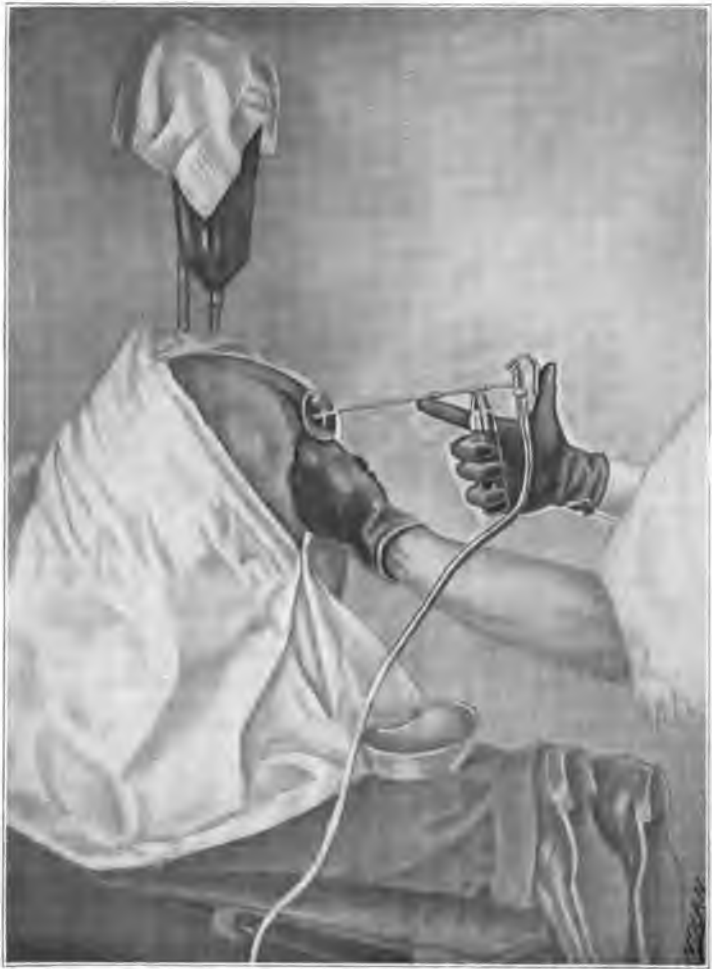

Fig. 184.—Method of spraying rectum and sigmoid with solutions, and also of insufflating mucous surfaces with antiseptic powders.

Shortly afterward, Dr. Meyer, also of New York, performed a similar operation.

Dr. Tuttle, of New York, conceived the plan of allowing the ap-



pendix to remain undisturbed after anchorage for a sufficient time (three or four days) to establish adhesions about the proximal end before cutting away the distal portion, and using the appendiceal stump lumen through which to irrigate with the desired solutions.

The author has practiced this last method and irrigated the colon with formalin-boric, copper phenolsulphonate, quinin, and iodine and thymol solutions with most gratifying results. It was observed, however, that the irrigations alone did not effect a cure. Topical applications (through sigmoidoscope or proctoscope) were in all cases used in conjunction.

The technic developed by the author combines the appendicostomy and cecostomy, and virtually makes an appendico-cecostomy.

The mesoappendix is ligated below the distal branch of the appendiceal artery; then the appendix is brought through a small stab wound about one inch above the anterior superior spine of the ileum, as advocated by Doctor J. A. Crisler, of Memphis, in 1906.

The exact location of the stab wound is determined by the position of the head of the cecum, and the possible tension when the patient is in the erect posture. The author's technic involves the anchorage of the cecum, not the appendix, but leaves the stump of the latter through which the irrigations are practiced, avoiding pressure upon the same. The appendix may be immediately cut off, but to minimize the danger of infection I think it is advisable to leave the same undisturbed for the first twenty-four or thirty-six hours, provided, of course, that no contraindications exist.

When this operation is completed, I insert a small sterile catheter to insure continued patency and at the same time act as a dilator. The appendicostomy-tube, devised by Dr. Hirschman, later replaces the catheter for permanent use in irrigating.

In a few cases the author was forced to perform rectal valvotomies on account of obstruction to drainage, and to the insertion of the proctoscope or even the tube beyond the valves which were tightly stretched across the lumen of the rectum. This operation will rarely be found necessary.

## CHAPTER XIV

### PROLAPSE OF THE RECTUM IN CHILDREN

Prolapse of the rectum is the descent, with or without protrusion, of one or all of the coats of the rectum, uncomplicated by any other diseased condition. Prolapse of the anus is usually understood to mean the descent and protrusion of either the mucous membrane alone or all of the coats of the anus and lower end of the rectum outside the anal aperture.

Prolapse may be either partial or complete. Partial prolapse is the condition in which the mucous membrane alone protrudes, complete prolapse describing the descent of all of the coats of the rectum. The complete variety is divided into three varieties, according to the degree or extent of the prolapse.

Prolapse of the first degree is the condition in which the prolapsed portion begins at the anal margin, and the mucous membrane covering it can be seen to be continuous with the surrounding skin, there being no sulcus surrounding it. In complete prolapse of the second degree, it will be found that the descent begins at some point in the rectum above the sphincter and is extruded through the anal orifice, being telescoped, as it were, through the non-affected portion below. In this variety a distinct sulcus can be made out between the prolapse and the margin of the anus.

Prolapse of the third degree may begin in the upper portion of the rectum, or even the lower portion of the sigmoid, may descend into the lower rectal cavity, but as a rule does not protrude from the anus. This variety is also known as *concealed prolapse* (Fig. 185).

Inasmuch as the limitations of this work do not include those conditions whose relief requires surgical operations under general anesthesia, none of the conditions mentioned above will be treated, save the condition most commonly seen by the general practitioner—prolapse of the anus and rectum in children. The most frequent variety seen in children is that known as the partial or incomplete, and it consists of an eversion of the anal canal, carrying with it the

mucous membrane covering the lower end of the rectum. It is a condition amenable in the vast majority of cases to non-surgical measures, when seen early and treated with patience and persistence.

### ETIOLOGY

It is brought about most frequently by severe prolonged or undue straining efforts on the part of the child. Such diseased conditions

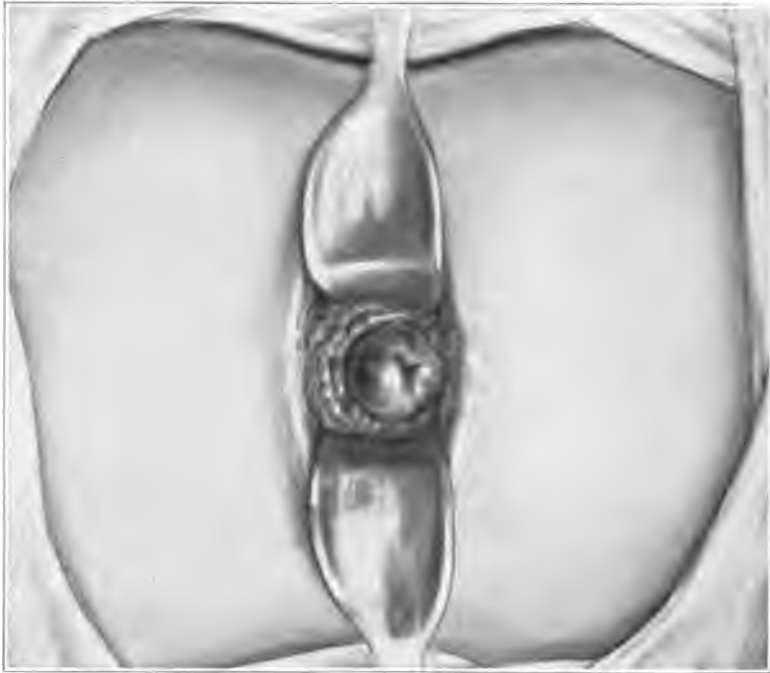

Fig. 185.--Prolapse of the rectum, third degree. This shows the prolapsing rectum descending to the anus but not protruding.

as the presence of a rectal polypus, hemorrhoids, foreign body in the rectum, hard constipated stools, pinworms, stone in the bladder, phimosis, diarrhea, excessive coughing or sneezing, accompanied by weakness of the sphincter muscle, are responsible at times; but most common of all are the prolonged straining efforts at defecation.

The practice so commonly in vogue among mothers in their efforts to train their children to regular habits of defecation has been

responsible in the majority of cases for the production of prolapse of the rectum. The little patient is placed upon the toilet, vessel or chair, and is soon made to realize what is expected of him. Sitting in the semi-squatting position, which is most conducive to the emptying of the rectum, even of its own mucous membrane, for half an hour, or even all the morning (as has happened in some cases which have come under the author's notice), the little one using all his efforts in order to accomplish his daily duty, gradually brings about a separation of the mucous membrane of the rectum, with accompanying protrusion from the anus.

In other cases, through extraordinary efforts of the abdominal muscles, the mesentery of the sigmoid becomes elongated, and an intussusception of the upper rectum and lower sigmoid takes place. Protrusion of the prolapsed bowel is very rare in this instance, and a condition known as *concealed prolapse* is produced and often goes undiagnosed for a considerable period of time. From an anatomical point of view, the straightness of the sacrum in children offers less support to the rectum than in adults, and in children who have been suffering from wasting diseases, the parts become so relaxed that practically all support is taken away from the rectum.

### SYMPTOMS

When the rectum prolapses in children, it appears rather unexpectedly. After a more or less long period of time, in which the "training" of the child has been going on, the mother is surprised, some fine day, by the appearance of a ring of red or purple-hued membrane surrounding the anus, the size depending upon the amount of rectum prolapsed. The longer the prolapse remains outside the rectum, the more purple-hued it becomes from the interference with the return circulation on account of the contraction of the sphincter.

### DIAGNOSIS

The diagnosis is very simple, in fact, self-evident. The appearance of a ring of soft, velvety mucous membrane protruding from the anus is indicative of only one condition, that of prolapse. A polypus would be differentiated by its rounded form, harder con-

sistency, and the presence of a pedicle extending inside the anus. Hemorrhoids, which are rare in children, would be gradual in onset, of firmer consistency, forming separate masses, and would not exhibit the peculiar red or purplish appearance of prolapsed mucous membrane. On each successive occasion, when the bowel is protruded, more of the mucous membrane comes down, and in aggravated cases the entire rectum may be extruded.

### TREATMENT

When the protrusion first makes its appearance it may be reduced in the following manner: The child is placed on its mother's

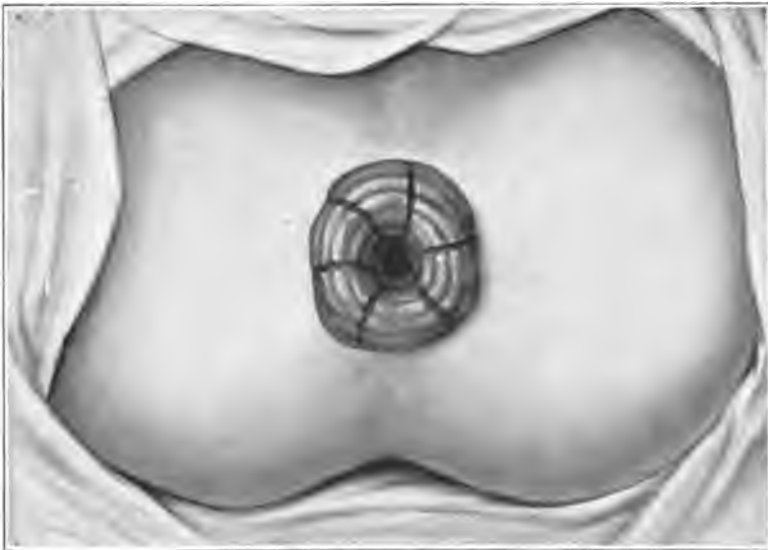

Fig. 186.--Prolapse of the rectum, first degree, showing radiating lines of cauterization.

lap with the buttocks raised considerably higher than the head. A compress soaked in ice water placed against the prolapse will often be all that is necessary. Gentle pressure will in a few minutes, in most cases, cause a return of the prolapsed portion. Oftentimes simple digital pressure on one side of the prolapse while the buttocks are separated with one hand, and steady pressure made with the finger of the other, will suffice. The other half is then treated in like manner,

Where the prolapse has remained outside long enough to become swollen, edematous, or congested, and the sphincter has contracted upon it, it will often be very difficult to return the prolapse unless the sphincter has been relaxed by the injection of a local anesthetic. In order to relieve the congestion and shrink the blood-vessels, the employment of compresses, soaked with one to one thousand solution of adrenalin chlorid and applied with firm pressure to the protrusion, has, in the author's hands, been found extremely satisfactory. The blood-vessels become constricted and the mass much reduced in size, and reduction is comparatively easy.

Whenever pressure is used in this region, it should be firm but gentle, as it would be very easy to do serious damage if the manipulations were rough or violent. Wrapping dry absorbent cotton around the index finger, and pressing firmly against the prolapse and in the direction of the rectal canal will often return a prolapse with ease. The finger is withdrawn in a twisting manner so as to allow the cotton to remain in the rectum, from whence it is expelled with the next stool.

If the child's habits are corrected, the bowel, in many cases, will not protrude again. In cases, however, where the protrusion recurs, a definite line of treatment must be undertaken in order to relieve the tendency to chronicity of the condition. Any existing cause, such as stone in the bladder, phimosis, pinworms, polypus, foreign body in the rectum, etc., must be relieved by proper surgical measures. If the case is due to constipation, the child's dietary should be looked into and corrected.

Where the case is one, however, where the prolapse has been brought about by the prolonged sitting at stool, with its coincident severe straining efforts, this method of training must be dispensed with. The child must be made to move its bowels in the recumbent position, either lying on its back or side, preferably the latter. It must not be allowed to have movements in the sitting posture while under treatment. The administration of white petroleum oil suitably flavored, in doses varying from ten minims four times a day in an infant, to a teaspoonful for the child of five or six years of age, should be resorted to in order to keep the stools soft and the intestinal canal well lubricated. It is important after the bowel movements to strap the buttocks together with strips of adhesive plaster,

and in some cases it may be advisable to keep a pad made of absorbent cotton, wrapped with gauze, firmly against the anus.

This treatment will be very successful if persisted in long enough. The author would advise two months as the average length of treatment in the average case. Any tendency toward diarrhea should be immediately looked after, and the dietetic cause for it discovered and corrected, for the violent peristalsis which accompanies diarrhea is often productive of as bad, if not worse, results as the straining efforts of constipation.

**Concealed Prolapse.**—In some cases of constipation, so called, in infants, all efforts for successful treatment will fail, and the author would advise in these cases the examination of the infant's rectum by means of a small-sized proctoscope or a large cystoscope. Occasionally, this method of examination will be rewarded by the discovery of a prolapse of the third degree (Fig. 185), which extends down to the rectum but does not protrude. In these cases the infant will be very fussy and will strain until red in the face, but all that rewards his efforts will be a small quantity of mucus stained with fecal matter; and the only way in which the child's bowels can be emptied is by means of enemata. The same treatment as outlined for the incomplete prolapse is indicated in this condition.

The principal point in the prevention and the treatment of prolapse of the rectum in children is the education of mothers along the line of the so-called training of infants. While it is not the province of this work to go into the subject of infant feeding, nevertheless, the author feels that if more attention is paid to the presence of sufficient hydrocarbon elements in the child's dietary, and the child is made to drink sufficient water, much good would result. Instead of forcing the little one to sit upon the toilet seat from half an hour to an hour and a half, or even longer, the child's bowels would then move with regularity and ease, and prolapse would become a very rare condition. The squatting posture as assumed by the aborigines is the best for the children. If after ten or fifteen minutes at the stool the child does not have a movement, it is far better to insert a soap suppository or administer a small enema to tide it over occasionally than to indulge in the pernicious custom, seemingly so prevalent, of keeping the child on the seat for a prolonged period.

When, in spite of strapping and the proper control of the bowel movements, the prolapse still persists, it becomes necessary to do something more radical. The method which has been most satisfactory in the hands of the author, and which is particularly adaptable to prolapse of the rectum in children, is what is known as *linear cauterization*. This may be accomplished in two ways—either by application of strong nitric acid or the use of the actual cautery. Neither method is applicable with entire satisfaction unless a general anesthetic is employed. Nitrous oxid, with or without oxygen, however, can be used in these cases with perfect safety and makes a very dependable and satisfactory anesthetic.

**Cauterization by Nitric Acid.**—The child is placed in the lithotomy position with the prolapse unreduced, and is placed under the influence of the nitrous oxid gas. The protruding mucous membrane is wiped dry, and a wooden applicator, one end of which has been wrapped with a very small quantity of absorbent cotton moistened with fuming nitric acid, is all that is necessary. The acid is applied in 4 to 6 radiating lines (Fig. 186), beginning at the uppermost portion of the center of the prolapsed mucous membrane at the lumen of the bowel, and with considerable pressure a line is drawn or painted to, but not touching, the mucocutaneous juncture. Four to six equidistant cauterizations are made in this manner, and an ointment composed of a dram of bicarbonate of soda to an ounce of petrolatum freely applied. A piece of rubber drainage tube, the size of a lead pencil, wrapped with gauze until it forms a plug or packing about  $\frac{3}{4}$  of an inch in diameter in its center and tapering at its extremities, is used to force the prolapse back into the rectum, and is left there for three or four days if possible. The little patient's suffering after the operation is not very acute, but if there should be much pain, it should be controlled by suitable doses of codein hypodermically;  $\frac{1}{8}$  to  $\frac{1}{4}$  grains of codein will answer very nicely in children from  $\frac{1}{2}$  to 3 years old.

The after-treatment consists in the same methods and procedures as those advocated above in regard to diet, defecation in the recumbent position, the strapping of the buttocks, etc. After three weeks the child may be allowed to resume defecations in the *squatting position*. In the first dressing immediately after the operation,



it is wise to exert some pressure against the anus, by means of a suitable pad ~~kept in place by adhesive-plaster straps.~~

**Linear Cauterization with the Actual Cautery.**—The patient is prepared as described in the preceding paragraph, and when the prolapse is protruding to its fullest extent, a Paquelin cautery, armed with a blunt point, and heated to a white heat, is used for making the cauterization in the same manner as the nitric acid is used (Fig. 186). One should be careful to carry the cauterization through the mucous membrane and into the muscular layer, but should be extremely cautious about burning through the muscular tissue. The amount of destruction of tissue is more apparent than real; one must remember the object of the cauterization is to accomplish the contraction of redundant tissues, and it is the contracting scar which invariably follows the use of the cautery, upon which we depend to accomplish the results. *In this condition we take advantage of the great contraindication to the use of the actual cautery in the surgery of the rectum, for we well know that the scar produced by a burn on mucous membrane invariably contracts to such an extent as to lessen the caliber of the rectum.* The after-treatment, dressing, and packing are the same as described where the nitric acid is used as a cauterizing agent.

Where these methods fail, there is nothing left to do but one of the cutting operations under surgical anesthesia, and preferably in hospital surroundings. When such is the case, the operation had best be done by one who is specially trained in this line of work, and not by the general practitioner, as the operative and after-care often taxes the patience, skill, and ingenuity of even the trained specialist to accomplish the desired results.

## CHAPTER XV

### TECHNIC OF THE USE OF LOCAL ANESTHESIA IN THE TREATMENT OF ANORECTAL DISEASES

If any excuse or apology were necessary for the presentation of this work to the profession at this time, the subject matter contained in this chapter will be ample justification. The dangers, inconveniences, necessary confinement in bed, and detention from business, which must attend the use of general anesthesia in many so-called minor operations, have created a demand and constantly enlarging field for the use, in many departments of surgery, of local anesthetics. In the surgical treatment of diseases of the rectum and anus this is especially true; and while there are many diseased conditions of this region requiring surgical interference, the extent of which makes their operative treatment impossible without general anesthesia, there are, nevertheless, many of the more common diseases of this part of the body which are entirely amenable to surgical treatment under regional anesthesia.

The development of the use of local anesthesia in the treatment of anal and rectal diseases has progressed to such a stage, that it is safe to say that at a conservative estimate fully 75 per cent of all cases of rectal and anal diseases are amenable to treatment without the use of general anesthetics.

#### **ANESTHETIC AGENTS**

Various anesthetic agents have been employed for the production of local anesthesia in this region, among which may be named the ethyl chlorid spray, and the injection of solutions containing quinin and urea hydrochlorid, cocain hydrochlorid, apothestin, betauecain hydrochlorate and lactate, alypin, stovain, novocain chloretone, as well as plain sterilized water.

Formerly, cocain, in solutions varying in strength from 4 to 10 per cent, was used. Symptoms of an alarming nature frequently developed after the injection of but a few drops of even

a 4 per cent solution, which clearly demonstrated the toxic properties of ~~the drug and the da~~ngers of its indiscriminate use in strong solutions. Today we know that the extent of anesthesia produced depends, not so much on the strength of the solution, as upon the pressure anesthesia produced on the nerve-endings, by the *amount* of solution injected, rather than its *strength*.

Today, therefore, practitioners who are still partial to cocain are using solutions for injection, varying in strength from  $\frac{1}{10}$  per cent up to  $\frac{1}{2}$  per cent, and find the latter strength equal to the severest test. The author, after a trial of all of the anesthetics mentioned above, places his main reliance on apothecin for skin anesthesia, and  $\frac{1}{2}$  per cent solution of quinin and urea hydrochlorid for infiltration of the tissues to be incised or removed.

Solutions containing more than  $\frac{1}{2}$  per cent of quinin and urea hydrochlorid should never be used in or directly underneath the skin. Cases of skin necrosis and slough have been reported from the subcutaneous use of stronger solutions. As a matter of fact, better or more complete postoperative anesthesia can not be secured from stronger solutions.

The strength of the apothecin solution varies according to the part to be anesthetized as well as on the amount of work to be done. For injection into the skin and for the anesthetization of the sphincterian nerves,  $\frac{1}{4}$  per cent solution is strong enough.

For the distention of the tissues, for instance, in operating for fissure or internal hemorrhoids, a  $\frac{1}{10}$  per cent solution will suffice. Another important reason for my preference for apothecin is the fact that apothecin is less than one-sixth as toxic as cocain, and is fully as powerful in its anesthetic properties.

My reasons for the use of quinin and urea hydrochlorid are that, in addition to its equality to cocain, apothecin, and eucain as an anesthetic, it is non-toxic, can be sterilized, and its anesthesia is prolonged for from two hours to several days after operation.

Quinin and urea hydrochlorid is a double salt of quinin and urea, made by dissolving quinin hydrochlorid in hydrochloric acid, adding pure urea, filtering the mixture through glass wool, and allowing it to crystallize. It is soluble in its own weight of water and in alcohol. It has the action of quinin, is non-irritating when injected hypodermatically, and produces local anesthesia, lasting in

some instances several days, depending on the strength of the solution.[www.libtool.com.cn](http://www.libtool.com.cn)

Dr. V. M. Griswold, of Fredonia, N. Y., first called attention to the hypodermic use of quinin as an efficient local anesthetic, and as being much safer than cocain, in July, 1896, before the Chautauqua County (New York) Medical Society.<sup>1</sup> Dr. Griswold claims that his use of quinin as a local anesthetic is the result of experiments with various substances in the endeavor to find one equally efficient but less dangerous than cocain.

In the *Journal of the Arkansas Medical Society*, for September, 1907, Dr. Henry Thibault, of Scotts, Ark., in an article entitled, "A New Local Anesthetic," first called attention to the local anesthetic effects of quinin and urea hydrochlorid. He recommended the use of a 1 per cent solution for local injection, and from 10 to 20 per cent for local application to any mucous surface.

The hydrochlorid of quinin and urea, being a water-soluble salt, is used in the South quite extensively for the hypodermic treatment of malaria. It was discovered that the site of injection of the quinin solution remained anesthetic for a considerable period of time following the injection. This fact has been taken advantage of, and the value of the discovery of a non-toxic substitute for cocain is being demonstrated by several workers at the present time.

In an article in the *Journal of the A. M. A.*, for October 23, 1909, Hertzler, Brewster, and Rogers, of Kansas City, Mo., published a report of their work with this anesthetic during the preceding six months, from which I will quote somewhat:

They started with the 1 per cent solution recommended by Thibault. They found, as stated by him, that a perfect anesthesia is obtained, which lasts from four to six hours. The anesthesia is more complete than with cocain. They soon discovered, however, that disturbances in skin union sometimes occur. Hertzler noted particularly that in hernia operations there is some disturbance in healing of the skin wound which had not been noted after the use of cocain. The disturbance was not great, but the patient had to be kept in bed longer than after the cocain operation. The edges of the wound were indurated and thickened, but there was no pus

<sup>1</sup>Buffalo Medical Journal, August, 1896, p. 32.

formation. The thickening appeared to be due to cellular infiltration. [www.libtool.com.cn](http://www.libtool.com.cn)

Hertzler thereupon undertook to determine experimentally the cause of the induration. Experiments performed on rabbits showed that the thickening is not due to cellular infiltration at all, as was supposed on clinical grounds, but is due to the pure fibrinous exudate free from cells. This exudate was proved to be fibrin by Mallory and Weigert's stain. The reaction appears, therefore, to be purely chemical in nature. The exudation of the fibrin begins to appear within a few minutes. In a general way it was determined that the amount of exudation depends on the strength of the solution used; the attempt was made, therefore, to determine a strength of solution which would not cause this exudation of fibrin. With  $\frac{1}{2}$  per cent solution the exudate is less than with the 1 per cent, and with the  $\frac{1}{4}$  per cent solution only traces can be discovered. To what extent this fibrinous exudate is subsequently converted into fibrous tissue has not yet been definitely determined, but apparently nearly all is absorbed.

In order to determine the subjective sensations of the injection and to determine the question of a possible zone of hyperesthesia about the anesthetized zone, Hertzler studied the effect by injection in the skin of his own leg. Injections of 1 per cent,  $\frac{1}{2}$  per cent,  $\frac{1}{4}$  per cent, and  $\frac{1}{6}$  per cent solutions, and an injection of plain water for control, were used in each series. The 1 per cent and  $\frac{1}{2}$  per cent solutions gave immediate and complete anesthesia without a particle of pain during its introduction. Within a few minutes there was a distinct induration. With the  $\frac{1}{2}$  per cent solution anesthesia was not complete for a few minutes, but was then as complete as after the use of the stronger solution. The  $\frac{1}{6}$  per cent solution gave delayed anesthesia, but after a few minutes was complete. In neither of these weaker solutions was induration noted on palpation. The water control caused intense pain on injection, and the anesthesia, at no time perfect, lasted only a few minutes. There was a zone of hyperesthesia one or two inches in width about the area injected. Curiously enough, the hyperesthesia seemed to be for touch and not for pain.

The duration of the anesthesia in the 1 per cent and  $\frac{1}{2}$  per cent solutions was perfect for four or five days, and sensation

in the  $\frac{1}{2}$  per cent strength was not restored to any great extent for ten days, and in the 1 per cent solution was not completely restored after two weeks. At no time was there the least pain, though the induration of the 1 per cent and  $\frac{1}{2}$  per cent solutions was yet marked at one and two weeks respectively. Quinin anesthesia, it will be seen, can be used for any operation where the use of local anesthesia is indicated. It has three very decided advantages over any other local anesthetic:

1. It is non-toxic, and can be given in unlimited dosage. Brewster has used 100 grains intravenously within six hours in a patient suffering from pernicious malaria.

2. The prolonged anesthetic effect. In many cases postoperative anesthesia has lasted from four to five hours to as many days and longer.

3. Where the solution containing 1 per cent or over is used, the hemostatic effect produced by the deposition of fibrinous exudate is of extreme value in preventing postoperative oozing.

The exudate being fibrin in the strict chemical sense, the usual natural processes of hemostasis are anticipated. The coagulum occurs, it is true, about and not in the vessels, and their occlusion therefore results from pressure from without. The important point, however, is that the effect lasts from seven to fourteen days, a time abundantly sufficient to allow healing by granulation to become well advanced. This is in marked contrast to the ephemeral influence of cocain and adrenalin, which act only by causing a contraction of the muscular walls of the bloodvessels.

The association of quinin and urea hydrochlorid with cocain, apothecin, eucain or any of the other anesthetic salts hitherto employed, will be found eminently satisfactory in all cases of rectal surgery where suturing of the integument is not required. My experience with this drug leads me to recommend it, on account of its several distinct advantages over any of the other anesthetic drugs upon which we have previously depended.

It is soluble in water and can be sterilized. It is equal to cocain in anesthetic power and is absolutely non-toxic. It has a pronounced hemostatic action, and postoperative anesthesia lasts from four hours to several days. It is inexpensive and almost always available.

The use of sterile water as an anesthetic in the treatment of

rectal and anal diseases was exploited prominently a few years ago, and while the author's experience with it has proved to him that satisfactory anesthesia in certain cases can be produced by its use alone, he limits its use in his work at present to the occasional distention of internal hemorrhoids for demonstration in teaching only. The one objection which he has found to its indiscriminate use is the larger degree of discomfort to the patient at the initial injection and the large quantities of solution required in some operations in the sphincterian region, causing such distortion of the tissues as not only to impede the work of the operator but to displace the parts so that accurate work could not be done.



Fig. 187.—Aseptic all-glass hypodermic syringe.




Fig. 188.—Aseptic all-metal syringe, provided with extension for infiltrating through the proctoscope.

It is well for the reader to realize that in "a pinch" sterile water can be used in lieu of any chemical anesthetic, and there are occasions, when he may be called upon to do work in an emergency, where the various chemical anesthetics may not be available, when with an ordinary hypodermic syringe and boiled water satisfactory anesthesia can be produced.

## INSTRUMENTS

The principal instrument required for the production of local anesthesia is a hypodermic syringe with a capacity of two to four drams, which may be constructed entirely of either metal or glass (Figs. 187 and 188), so that it can be readily sterilized by boiling.

The needles used should be the finest that can be procured, and the points should always be kept sharp. *A quick puncture with a sharp-pointed fine needle is almost painless*, while the use of a larger-calibered needle with a short beveled point will cause considerable unnecessary discomfort to the patient. The piston-syringe package, constructed of glass and rubber, which many of the manufacturers of antitoxin supply, when sterilized by boiling, makes a fairly good substitute for the regular aseptic hypodermic syringe, and in the absence of the proper apparatus it may be used. The objection to it is the fact that the needles supplied with it are usually of larger caliber and not so sharp as they should be for this work.

The solution used should be accurately prepared as to the percentage of chemical anesthetic used. Where beta-eucain lactate is employed, the solution is made up and placed in an ordinary test-tube. It is sterilized by boiling over the flame of a Bunsen burner or spirit lamp, and then stoppered with absorbent cotton and allowed to cool. The solution is prepared freshly for each operation. The quinin-urea solution is prepared in like manner when the tablets are used.

### GENERAL TECHNIC

The patient is prepared for the operation as follows:

Twenty-four hours before the operation, he is given a brisk cathartic and is instructed to partake of nothing but liquid food thereafter. On the morning of the operation the bowels are washed out by means of a large soap enema, and he is directed to report at the office about one-half hour before the time for the operation. He is then given a quarter of a grain of morphin or two grains of codein by mouth.

When ready to operate, the patient is placed upon the table in the left lateral position, the left leg extended and the right well flexed. The lower clothing is removed or placed well out of the way, and the patient covered with clean sheets. The anus and perineum are shaved and scrubbed with liquid antiseptic soap, then washed with a 1:1000 solution of iodid of mercury, which is washed off with sterile water, and a compress of alcohol applied. If one



prefers the iodine-alcohol method of skin sterilization, it is equally applicable. A point one-half inch below and posterior to the posterior commissure of the anus is selected. A swab moistened with pure carbolic acid (Fig. 189) is applied to lessen the pain which accompanies the introduction of the needle. Wherever it is possible,



Fig. 189.-- First step in all operations under local anesthesia—application of carbolic acid to point of puncture.

the index finger of one hand, protected by a finger cot or gloved, and well lubricated, is inserted in the anus, and the sphincter is pulled downward and backward. The syringe, containing about one dram of  $\frac{1}{8}$  to  $\frac{1}{2}$  per cent solution of apothosin, with a fine sharp-

pointed needle about two inches in length attached, is held in the other hand. The needle is inserted quickly, just underneath the skin, and 6 to 10 drops of the solution slowly injected. *One should be extremely careful about injecting the solution too quickly, as this part of the procedure is the most painful and often needlessly causes suffering, particularly to the timid and neurotic patient.* The point of the needle is then passed inward and laterally, going down toward and into the external sphincter muscle, which, guided by the finger in the rectum, is brought down toward the needle. The point of the needle should be kept about one-half inch from the anal aperture and the injection is carried up along the right postero-

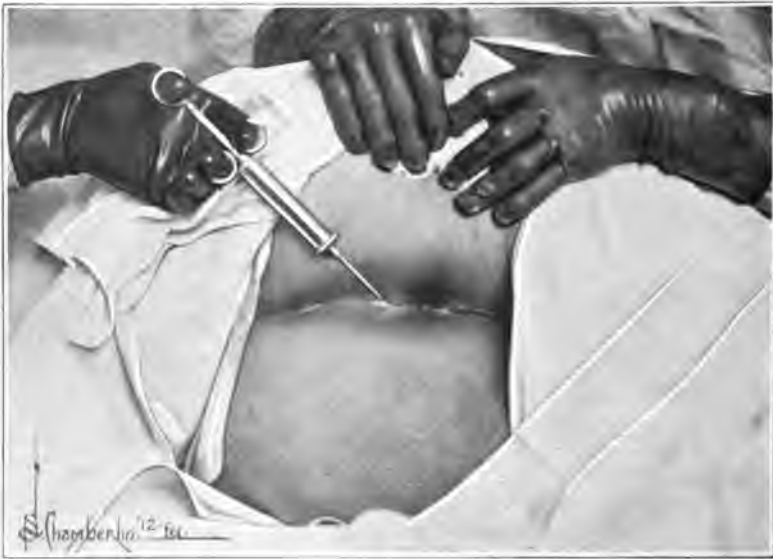

Fig. 190.—Exact point of puncture for the injection of local anesthetics for dilating the external sphincter. With the patient in the lateral position, a point from  $\frac{1}{4}$  to  $\frac{1}{2}$  inch posterior to the posterior commissure of the anus is chosen for the first injection.

lateral quadrant (Fig. 191) of the anus for about three-fourths to an inch. The needle is then *retracted to the point of puncture but not withdrawn*. It is then pushed up on the left side in the same manner, injecting the opposite side so that when the injection is completed the wheal of infiltration is U-shaped, the apex being at the point of puncture (Fig. 192).

This technic allows of the anesthetization of the sphincterian

nerves of both sides from but a single puncture. Care should be taken lest the rectal wall be punctured, but with the index finger of one hand in the anus during this procedure, such an accident should not occur. The anesthetization of the anterior sphincterian nerves is accomplished in a similar manner, but is only required where a pathological condition on the anterior anal wall is to be operated (Fig. 193).

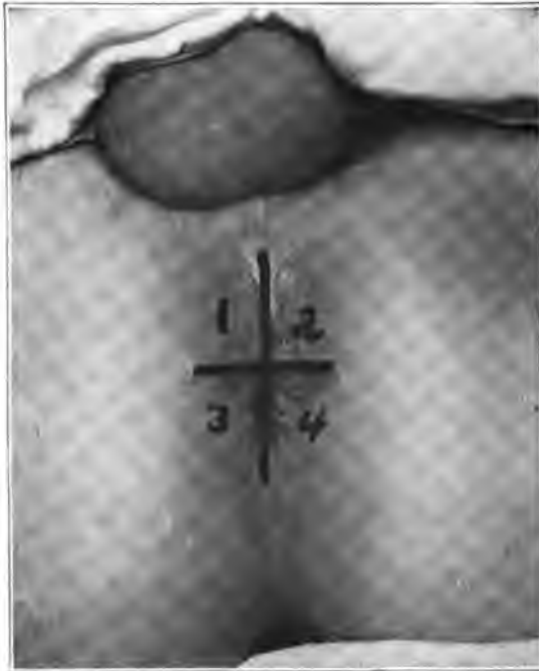

Fig. 191.—Quadrants of the anus.

1. Right antero-lateral quadrant.
2. Left antero-lateral quadrant.
3. Right postero-lateral quadrant.
4. Left postero-lateral quadrant.

In operations for multiple internal hemorrhoids, or other procedures, where the complete exposure of the field obtained by the use of the four triangular forceps is desired (Fig. 196), the entire circumanal circumference must be infiltrated.

Sufficient relaxation of the anesthetized sphincters (Figs. 195-

196) can be thus secured to perform any operation described in this volume. [www.libtool.com.cn](http://www.libtool.com.cn)

Complete divulsion of the sphincter can very rarely be accomplished by this means, and is not ever necessary, but the dilatation will be amply sufficient for our purposes.

The vibrator (Fig. 194), is a very convenient, but not at all necessary, apparatus to have at hand, as the dilatation can be

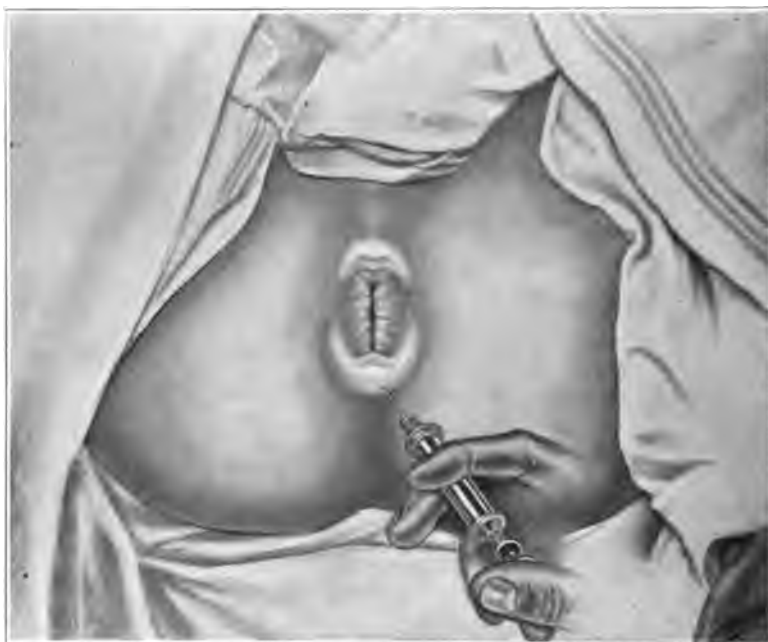

Fig. 192.—Showing the amount of distention necessary in anesthetizing the sphincters.

more quickly and evenly accomplished by its use. In its absence, however, one may use the index fingers of both hands, protected by finger cots or rubber gloves, and by a gentle to-and-fro massaging movement, gradually assist relaxation and dilatation in a very satisfactory manner. One should never use any of the dilating rectal speculums in the dilatation of the sphincter. The fingers are far better dilators, and can do no damage with intelligence and care behind them to guide.

**TECHNIC IN SPECIAL CASES**

[www.libtool.com.cn](http://www.libtool.com.cn)

The technic for operating for the various conditions amenable to operative treatment under local anesthesia will be found described more in detail in their respective chapters, while the differences in technic of anesthetization will be taken up below. Suffice it to say, however, at this point, *that no operation upon the anus or rectum should be undertaken under local anesthesia, which will require extensive dissection or over twenty minutes of time for its completion.*

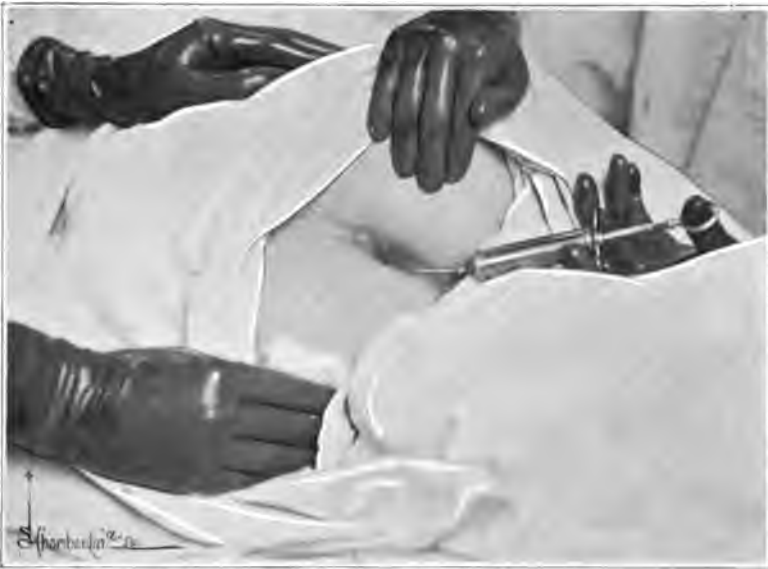

Fig. 193.—Exact point of puncture for anesthetizing anterior sphincterian nerves for dilatation of the external sphincter.

**External Hemorrhoids.**—If the hemorrhoid is entirely external and is not complicated by any other anal condition, it will not be necessary to anesthetize the sphincter. After the usual preparation for the operation, the most dependent hemorrhoid is injected from its base with  $\frac{1}{4}$  per cent solution of apothestin, about 20 to 30 minims being used directly under the skin. If further distention is required in order to produce complete anesthesia,  $\frac{1}{2}$  per cent quinin-urea solution may be used for the deeper injection. After

five minutes the skin may be incised painlessly, and the operation performed. Where more than one hemorrhoid is to be operated, they should all be anesthetized at once, and operated in turn if the operator is rapid in his work.

**Acute Thrombotic Hemorrhoids.**—The acute thrombotic hemorrhoid is usually single, occurring just at the anal margin. After being prepared for operation, eight or ten drops of  $\frac{1}{2}$  per cent solution of apothecin or  $\frac{1}{2}$  per cent quinin and urea solution is

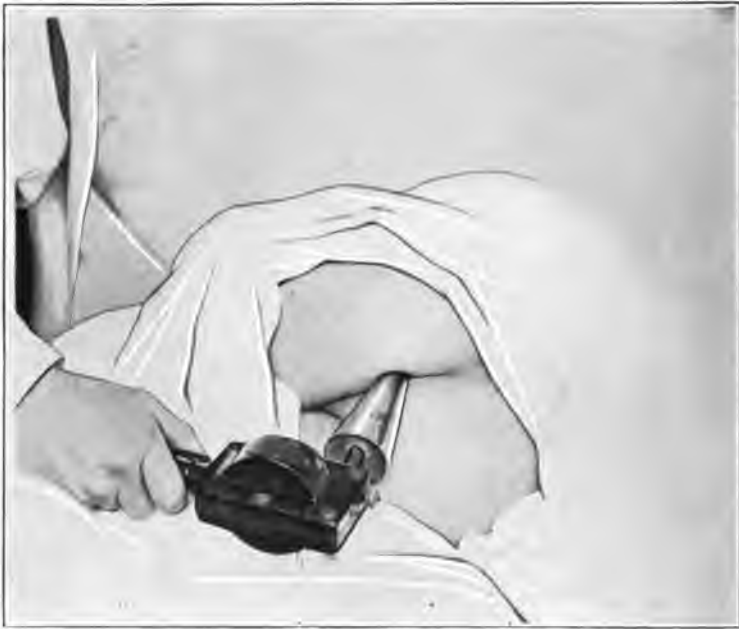

Fig. 194.—Posture and method of producing dilatation of the sphincter ani by the use of a portable vibrator, armed with a cone-shaped vibratorode.

injected just beneath its outer covering, whether skin or mucous membrane, care being taken not to inject deeply and into the clot. Sufficient solution should be used to distend the tissues over the clot and blanch them to whiteness. It may then be incised painlessly, and the clot turned out. It is well after the turning-out of the clot to inject the tissues beneath it, and examine carefully, as usually more clots will be found beneath the first, which must be removed in like manner.

**Perianal Abscess.**—In those cases of perianal abscess not extensive enough to require general anesthesia for their operative treatment, the use of a local anesthetic is well adapted. The technic in injection is the same as that outlined above for thrombotic hemorrhoids. The reader is cautioned to make his injection very carefully, so as not to perforate the abscess cavity with the needle. The solution must be injected into the skin itself and directly under it. After waiting at least five minutes for anesthesia to take place, the abscess may be opened with absolutely no pain.

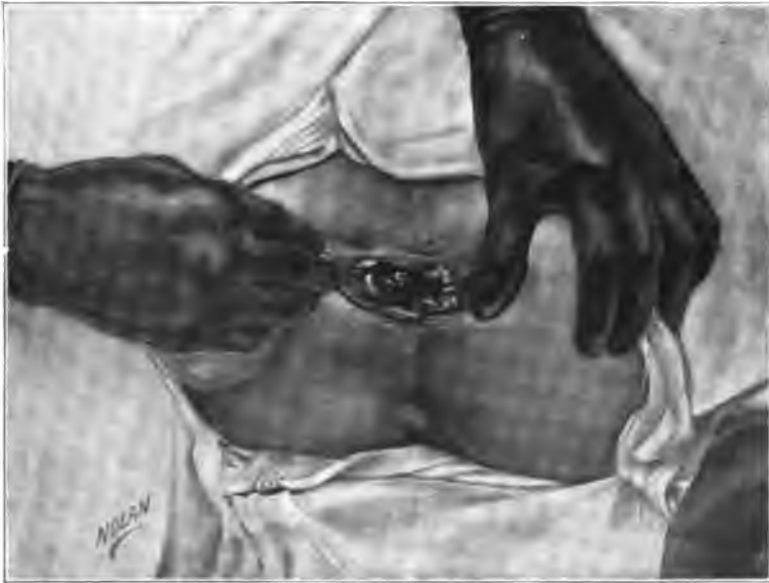

Fig. 195.—Amount of dilatation of the sphincter under local anesthesia. This drawing, made from a photograph of one of the author's cases of internal hemorrhoids, well illustrates the amount of dilatation of the sphincter that may be produced by local anesthesia. While complete divulsion is rarely possible or necessary, sufficient relaxation is here secured to remove successfully the internal hemorrhoids shown in the drawing.

**Anal Fissure.**—In all cases of fissure, the sphincter should be anesthetized thoroughly. In many cases where the fissure is situated low down, the anesthetic solution injected for the anesthetization of the sphincter will also be sufficient for the incision or excision of the fissure as well. Where the fissure is more extensive and with an indurated base, or is located at some other portion of the anus than its usual site, the posterior commissure, it must be

injected separately. A  $\frac{1}{2}$  per cent solution of apothecin, or  $\frac{1}{2}$  per cent solution of quinin and urea hydrochlorid, may be used. The syringe should be filled. The needle should be inserted about one quarter of an inch below the outermost extremity of the fissure or beyond the sentinel pile when one is also present.

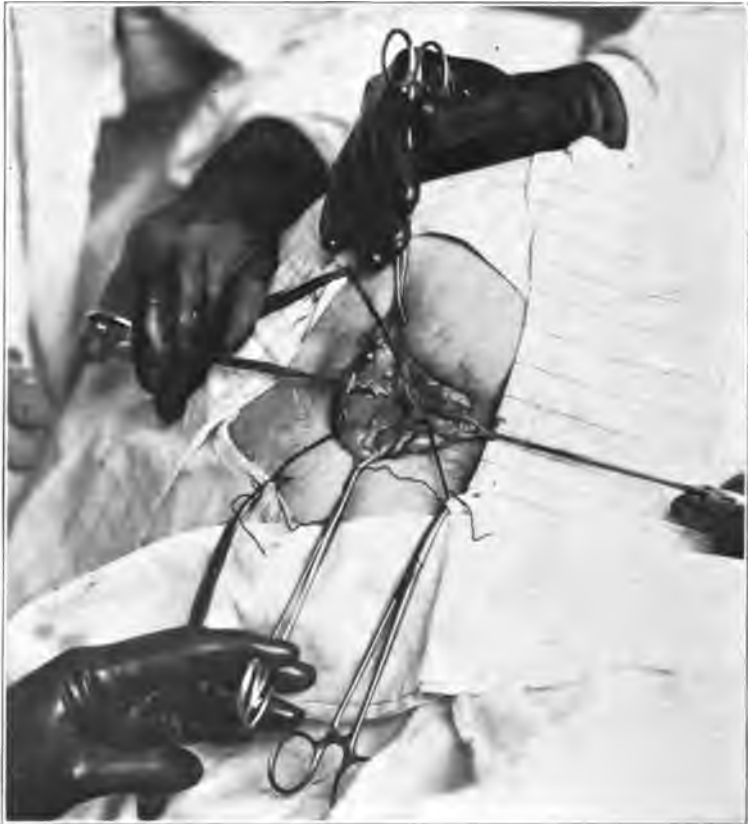

Fig. 196.—A good idea of the anesthesia and relaxation produced by the technic outlined.

The skin and mucous membrane surrounding the fissure or induration, as the case may be should be infiltrated to such an extent that the fissure is raised on a white waxy-looking mound and lies, as it were, on a water-bed. It may require as much as three drams of solution, but distention of the tissues is essential before



thorough work can be done. Anesthesia should be carried below the base of the fissure for at least a quarter of an inch.

**Fistula and Sinus.**—The only variety of fistula in which it is advisable to use local anesthesia as a routine measure is that of a simple, shallow, complete fistula whose course is direct and not branching. An external or internal sinus whose opening is not over one inch from the anus, and whose extent can be accurately gauged, may be opened under local anesthesia. As a general proposition, with the exception of the three varieties mentioned, general anesthesia (nitrous oxid and oxygen whenever possible) should be used in operations for anal fistula and sinus. The sphincter should be anesthetized in all cases. The skin and mucous membrane above the fistula should be infiltrated with the  $\frac{1}{2}$  per cent apothecin solution, and then by successive injections the entire fistulous tract surrounding, with the injected anesthetic fluid. The infiltration should be carried to the point of blanching. The operation then may be proceeded with as outlined in the chapter on fistula.

**Hypertrophied Anal Papillæ.**—In cases where hypertrophy of the anal papillæ is not accompanied by a tightly contracted sphincter, it is possible to remove the papillæ under local anesthesia without relaxation of the sphincter. It is advisable, however, in order to overcome the tenesmus and painful spasmodic contractions of the sphincter following any operation in the anal canal, to anesthetize the sphincter as a general rule in removing these papillæ. Where this is done the anus is held open by means of a retractor, and each papilla is injected from base to apex with the  $\frac{1}{2}$  per cent apothecin or quinin-urea solution. It may then be removed painlessly, and each successive one injected in turn before removal.

Where the sphincter is not anesthetized, the use of a short anoscope with an oblique opening, such as has been described by the author, will be required. The papilla, as it hangs down or projects into the opening of the anoscope, is injected by means of a long needle attached to the hypodermic syringe, and injected as described above. Where it is desired to open the crypts of Morgagni as well, the needle should be carried up for half an inch or so, when after the removal of the papilla, the crypt can be split open at will.

**Hypertrophied Rectal Valves.**—In operating for the section of

hypertrophied Houston's valve, the dilatation or relaxation of the sphincter, as outlined above, is often the only part of the operation, where a local anesthetic is required. The valves themselves are very poorly supplied with sensory nerves, and as a result, incision is painless. In some cases, however, there is some sensitiveness to pain; so it is wise in all cases to be on the safe side, and apply by means of an applicator bent at a right angle a 2 per cent solution of apothecin or beta-eucain to both upper and lower surfaces of the valve. After waiting two minutes, operation may be begun.

**Removal of Foreign Bodies.**—Oftentimes small splinters of shell, bone, pins, or other swallowed foreign bodies will traverse the entire gastrointestinal tract without doing any injury or becoming lodged, until they reach the lower end of the rectum, when they impinge against the rectal aspect of the mucous membrane covering the sphincter muscle, or lodge in one of the crypts. By their constant irritation, they cause spasm of the muscle and intense suffering. On account of the tonic contraction of the sphincter, which is caused by this irritation, any attempt at the insertion of a proctoscope or even the finger is usually futile. The dilatation of the sphincter by means of the technic outlined above is nowhere more applicable than in this class of cases, and not only such foreign bodies as have been mentioned, but fecal concretions and impactions of considerable size as well, can be removed without the employment of a general anesthetic.

**Removal of Benign Perianal Growths.**—Small benign growths situated at or near the anal orifice, such as dermoids, sebaceous cysts, lipomata, or condylomata, are very satisfactorily removed under local anesthesia, with the following technic:

After the parts are cleansed, shaved, and sterilized, condylomata are removed by infiltration of the underlying skin with  $\frac{1}{2}$  per cent solution of apothecin. When anesthesia is complete, the affected skin is cut away and the wound either sutured with interrupted silkworm or allowed to remain open to heal by granulation. Boro-chloretone powder is then applied, and the parts covered with a gauze dressing. In the case of a dermoid, sebaceous cyst, or fatty tumor, the technic is the same for the removal of any of the three varieties. The skin covering the tumor is first injected

with  $\frac{1}{2}$  per cent solution of apothestin, a wheal or welt being formed over the proposed line of incision. The incision is made, and the tissues above and surrounding the tumor infiltrated with the apothestin solution or  $\frac{1}{2}$  per cent solution of quinin and urea hydrochlorid, when the dissection and removal of the growth can be accomplished easily, with forceps and scissors. Care should be taken in the case of a cystic tumor not to puncture the cyst wall with the injecting needle, and in the excision of the growth to be sure to remove all of the sac. If this is not done, recurrence is likely.



Fig. 197.—Wales rectal bougie. This is made of flexible rubber and provided with a canal, through which the irrigation may be given, and which allows the entrance of atmospheric air and escape of gas during its introduction. There are twelve different sizes.

**Posterior Internal Proctotomy for Annular Stricture Situated in the Anal Canal or Not Over an Inch Above the Anorectal Junction.—**

With the patient in the left lateral position, and prepared for operation, the region posterior to the anus, anal canal, and stricture is infiltrated with  $\frac{1}{2}$  per cent solution of apothestin or quinin and urea hydrochlorid. After waiting five minutes for anesthesia to take full effect, the stricture is divided in the posterior median line down to the rectal wall with a sharp scalpel, a piece of gauze inserted, and the operation is complete. The author's technic for rectal valvotomy by the use of the rubber ligature may be substituted for the incision, if the caliber of the stricture is sufficiently large to admit the ligature carrier. After operation, the recurrence of the stricture is prevented by the introduction of Wales'

bougies (Fig. 197) up to size No. 12, twice a week at first, and at increasing intervals until complete healing has taken place.

After carefully perusing what has been said regarding the employment of local anesthesia, and bearing in mind the contraindications and objections, as outlined in the following chapter on Limitations of Local Anesthesia, other diseased conditions of not only the rectum and anus, but in other parts of the body, will present themselves, in which the employment of local anesthesia will be found very advantageous; and the results obtained therefrom fully as successful as where, heretofore, the employment of general anesthesia has been thought absolutely necessary and indispensable.

In the last three or four years, the author has employed the American-made local anesthetic apothecin in preference to those made "by the enemy." He is happy to state it is equal in every way to the best of the foreign-made drugs, and in many ways superior to all. Any of the standard anesthetic salts may be employed in practically the same strengths as apothecin, and the individual preference of the operator must govern his choice of local anesthetics.

## CHAPTER XVI

### LIMITATIONS OF LOCAL ANESTHESIA AND OFFICE TREATMENT AND INDICATIONS FOR OTHER MEASURES

While the primary object of this work has been to bring before the profession the advantages to be gained from the treatment of various rectal diseases in office practice, and to demonstrate the advantages of the use of local anesthesia in the treatment of many of the more common conditions met in connection with the treatment of diseases of the anus and rectum, it has been thought wise to utter a warning note, lest the reader be led away by over-enthusiasm.

While the author believes that the field for the employment of local anesthesia in rectal surgery, as well as in other branches of practice, is rapidly widening, he wishes to impress upon the reader that *this field has definite limitations and that there is and always will be, a large class of cases whose successful treatment requires more radical measures, which only can be employed by the aid of full general surgical anesthesia.*

If the reader has carefully read what has been written upon means and methods of diagnosis, and has noted in the various chapters following the class of cases in which the author advocates the use of non-surgical measures and the employment of local anesthesia, he will have noted that the methods of treatment advocated are confined to a very definite class of cases. All of the conditions treated of have been located either at, or in the immediate vicinity of, the anal canal, or were those affections of the mucous membrane of the rectum or lower sigmoid which are accessible to treatment through the proctoscope or sigmoidoscope.

The first thing one should remember, before commencing the treatment of any pathological condition found in the region of the anus, is that, until a careful exploration of the entire rectal cavity has been made, and every portion of it examined with the

eye, he has not made a diagnosis, and has no right to treat the patient until he has. It would be a sad and unfortunate discovery for the physician who has been treating an anal ulcer, polypus, or pruritus, or hemorrhoids to find after several weeks, that the condition under treatment was merely secondary to a multiple colonic polyposis, an extensive ulceration higher up in the rectum, a stricture, or malignant disease (Frontispiece).

### GENERAL CONTRAINDICATIONS TO LOCAL ANESTHESIA

In women, suffering from pelvic troubles which may require laparotomy for their relief, the removal of any minor rectal condition present under local anesthesia had better be postponed, and the rectal or anal condition treated at the time of laparotomy.

In patients suffering from irregularity or interruption of their normal bowel movements, it is wiser to exclude by careful abdominal examination, and the use of fluoroscopic examination and stereoscopic radiographs taken in both the upright and prone positions, any possibility of chronic intestinal obstruction due to some abdominal growth, ptosis, displacement, or adhesions, than to attempt to relieve the patient by means of rectal dilatation and massage.

Every patient presenting himself with a fissure or ulcerative condition of the anal canal should be carefully questioned as to the possible history of previous syphilitic infection. The presence of gonorrhoeal discharge is a contraindication to operative measures until the discharge is remedied. In women, a purulent vaginal discharge as well as the menstrual flow is, of course, a contraindication.

Patients suffering from profound anemia are always bad subjects for operation at one's office under local anesthesia, and a history of hemophilia should always be excluded before office operations. Patients of a highly neurotic temperament and hysterical females are best operated at home or in the hospital, and often under general anesthesia. *In other words, the suitable cases for office treatment are those suffering from diseased conditions, whose pathological source is located on either the mucous surface of the*

*rectum and lower sigmoid, and are definitely circumscribed in area and not of a malignant, syphilitic, or tubercular type; or lesions occurring at or around the anal orifice, whose outlines can be definitely marked out by the diagnostic means outlined in the fore part of the book.*

### CANCER OF THE RECTUM

A great satisfaction to the practitioner, who as a routine measure makes a proper rectal examination of his patients whose symptoms would seem to indicate it, is the discovery of commencing malignant disease early enough to allow of the removal of the primary focus, and to save the patient's life. As has been said before, a history

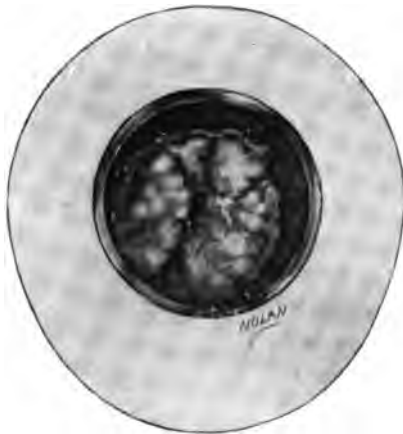


Fig. 198.—Proctoscopic view of carcinoma, situated just below the juncture of rectum and sigmoid.

of rectal hemorrhage, however slight, is an imperative demand for complete exploration of the rectal cavity, and the most important condition for which to be on the lookout, which makes itself manifest early by rectal hemorrhage, is cancer. It is in this condition, above all others, where an early complete proctologic and sigmoidoscopic examination will achieve brilliant results, if the findings therefrom will result in an early operation for the removal of the growth. It is the same with malignant diseases in this part of the body as in all others—if the surgeon can only get at them *early enough* to thoroughly eradicate, he can relieve them with a pretty definite hope of permanent cure.

Inasmuch as rectal cancer most frequently occurs in the lower part of the organ, the early operation and complete removal are productive of much good. *Some of the early symptoms of commencing cancer of the rectum or sigmoid are flatulence with colicky pains, diarrhea, alternating with constipation, tenesmus, increased mucous discharge, which is usually offensive in odor, and hemorrhage.* This hemorrhage is very slight at first, often showing a few blood streaks with the mucus, or small passages of blood either

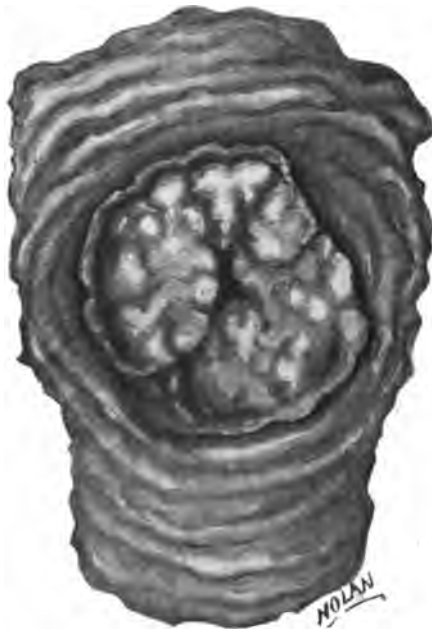

Fig. 199.—Carcinoma shown in the preceding illustration, drawn from specimen removed by operation.

with the stool or occasionally between bowel movements. *The nearer to the anus the cancer is located, the earlier in the disease the hemorrhage, on account of the traumatism to the growth caused by the passage of the feces.* Cachexia, loss of weight, and impairment of general health are *not* early signs of rectal cancer. The indican reaction is usually present in urine in cancer, while it is absent in ordinary diarrhea.

Diarrhea which persists for some time, which is accompanied



by the presence of blood, however slight, should be regarded as suspicious, and the patient carefully watched. When one considers that 50 per cent of all cancers occur in the gastrointestinal tract, and that 16 per cent of all cancers of the digestive tract occur primarily in either the rectum or sigmoid flexure, one commences to realize the importance of examining every case which

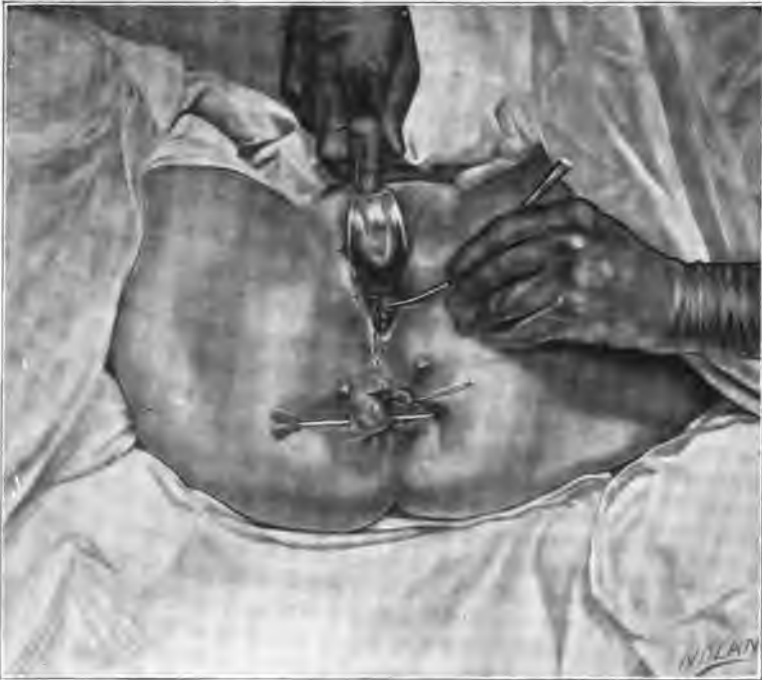

Fig. 200.—Cancer of the rectum, with multiple fistulae. This drawing, made from a photograph of a case referred to the author, tells a pathetic story. The patient, a woman aged 52, suffering from various digestive disturbances and the appearance of blood with the stool, made her own diagnosis of "bleeding piles;" after six months of self-treatment, she consulted an irregular advertising quack, who confirmed her diagnosis of "hemorrhoids," and proceeded to "absorb the growth by electricity." When her money ran out she was sent home cured. Her condition one month later, when seen by the author, is illustrated above. The area of infiltration involved the entire anus, posterior wall of the vagina, and all of the perineal wall between. Her perineum was riddled with abscesses and fistulae. The rectum and vagina communicated through a large rectovaginal fistula, and the posterior wall of the bladder was infiltrated. The case was hopeless, and she died shortly afterward.

presents a history of rectal hemorrhage, however slight, no matter what the age or general appearance of the patient.

Well-authenticated cases of cancer of the rectum have been found in cases as young as fifteen years of age. To show how

much more frequently cancer is prone to locate in this part of the body than is generally supposed, it may be stated that Boas found in 500 cases of cancer of the digestive tract, 83 cases of cancer of the rectum. In the personal practice of the author, very frequently patients are brought in by practitioners, many of

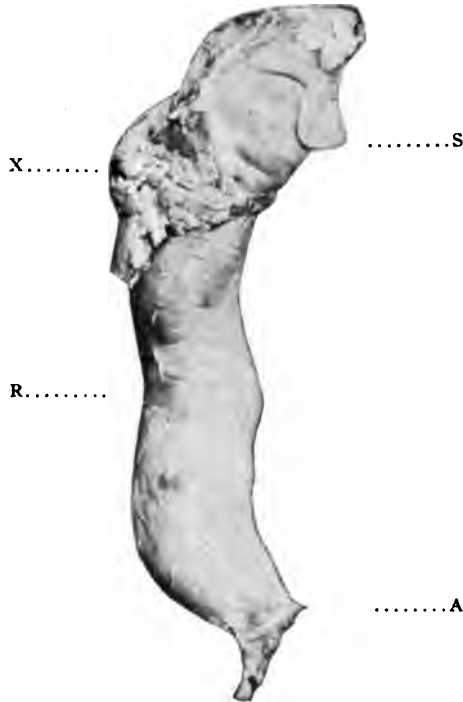


Fig. 201.—Cancer of the rectum. This specimen, which includes the entire rectum and lower portion of the sigmoid, being twelve inches in length, was removed by the author by the perineal method, the sphincters being preserved. This case will illustrate the value of early diagnosis and prompt operative interference in cancer of the rectum. The patient, aged 50, suffered from gradually increasing disturbances of the digestive functions for about six months. The symptoms gradually grew worse, and she noticed that her stools were becoming smaller in caliber, and accompanied by a small quantity of blood. She consulted her physician, thinking that she had hemorrhoids. He immediately made a proctoscopic examination, and discovered just below and extending to the rectosigmoidal juncture a crater-like ulceration with raised edges projecting into the lumen of the bowel. A diagnosis of rectal cancer was made and the case referred to the author for operation. There was no extrarectal involvement, and the complete extirpation of the diseased rectum and lower sigmoid was followed by a rapid recovery of the patient. Four years after the operation she reported herself in perfect health, with no signs of recurrence.

whom really try to do conscientious work, with unsuspected cancer of the rectum. Many of these patients are in the forties, present robust appearance, and come with a history of some bleed-

ing from the rectum from which they make their own diagnosis of "bleeding piles." They also complain of some disturbance of bowel movements, either constipation or diarrhea, and disturbed gastric and intestinal digestion, and occasionally a not very well-defined aching in the sacral region.

In many of these cases proctoscopic (Figs. 198, 199) and sig-



Fig. 202.—Cancer of the rectum. Same as the preceding. Interior view of the specimen. (The lettering on the preceding specimen corresponds to that below.)

- A. Point of amputation from the anus.
- R. Rectum.
- X. Cancer.
- S. Sigmoid flexure.

moidoscopic examinations have demonstrated the presence of cancer of the rectum, so far advanced as to cause almost complete occlusion of the lumen of the bowel, and too far advanced to extirpate with any hope of cure. It is the unfortunate experience of many proctologists to be called upon to inform many of these patients of their hopelessness, and it is with the hope of

bringing the profession in general to realize the importance of examination of the rectal cavity in all cases presenting the symptoms just mentioned above, that so much stress is being laid on the importance of early examination of the rectum by the general practitioner (Figs. 200-202 and Frontispiece).

### ULCERATION OF THE BOWEL

Cases of ulceration of the bowel involving more than one circumscribed area which have become chronic, as well as the very extensive ulcerations due to the specific infections like tuberculosis and syphilis, are not suitable cases for office or local treatment. It has been found in the experience of most proctologists that the only satisfactory way by which such cases may be cured is by "sidetracking" the fecal current by means of a temporary colostomy. This removes the mechanical as well as the bacterial irritation from the ulcerated surfaces and puts the parts at physiologic rest; after which irrigations and other suitable therapeutic measures can be applied from above, as well as below. These cases, however, require more or less confinement in bed or in the house, and are best treated only in the surroundings which the modern hospital can best supply.

While it is true that *colostomy* can be performed under local anesthesia, as the author has demonstrated in several cases, it is hardly to be advised to be performed by the general practitioner or included in the same class as the operative measures or diseases mentioned in the foregoing chapters.

### STRICTURE OF THE RECTUM

No case of stricture of the rectum should be treated, whether by dilatation, incision, or ligature in office practice, unless it is situated within the first two inches of the anorectal canal, and is not smaller in caliber than the circumference of a No. 10 Wales bougie. Even then, its situation, consistency, structure, and relation to the rectal walls and impinging organs should be definitely ascertained by radiographic, digital, and instrumental, as well as ocular, examinations. Great caution must be observed in using forcible dilatation in any case of stricture of the rectum,

no matter how elastic the stricture may seem. Accidents have been reported where the rectum has been torn through, and the peritoneal cavity entered with fatal results, from the simple dilatation of large-calibered strictures by means of the Wales bougie. Cases of "stricture," due to unusual infiltration of one of Houston's valves, or strictures of the umbrella type, can be easily divided by means of the author's rubber-ligature operation, as applied to hypertrophied rectal valves.

Where the administration of nitrous oxid with oxygen is so easy, and attended with practically no danger, its use is to be advocated in those cases where operation of a short duration is all that is required, for which general anesthesia is absolutely necessary.

### RECTAL ABSCESSSES

While, as has been pointed out in a preceding chapter, some circumanal and perirectal abscesses are amenable to treatment, within certain limitations, under local anesthesia, abscess formation may go on to such a point, where it is absolutely necessary to do a more extensive operation than is possible under local anesthesia. Certainly no abscess which extends above the levator ani muscle should ever be opened under local anesthesia; nor any abscess in the ischiorectal region, in which there is any doubt as to the operator's ability to obtain a large and free drainage opening by means of incision without curetting. Owing to the ease with which it enlarges in the ischiorectal region, it is a safe plan not to attempt to open any abscess under local anesthesia, if it has become larger than a hen's egg in size, unless a definite point of fluctuation and softening can be detected at a point well outside the sphincters.

### ANAL FISTULA

No case of anal fistula which has more than one channel, or whose limits can not be definitely made out by digital examination, should be opened under local anesthesia. In fact, the only safe way is to obtain a stereoscopic radiograph after the injection of bismuth paste. Only the simple, direct, complete, or external and internal sinuses or submucous fistulæ, are amenable to

operation under local anesthesia, and in case of doubt, nitrous oxid or ether should be employed. One never can tell how high, or how extensive, a dissection may be required for the complete removal of a fistulous tract, or which is the ideal operation, unless he is guided by a good set of stereoscopic radiographs.

### HEMORRHOIDS

In operating for hemorrhoids under local anesthesia, one must be extremely careful in the selection of cases. Hemorrhoids, complicated with fistula, extensive ulceration, complete rectal prolapse, or abscess, are best treated only under general anesthesia. External hemorrhoids and acute thrombotic hemorrhoids can almost invariably be removed under local anesthesia, fully as satisfactorily as by the use of a general anesthetic. In the treatment of internal hemorrhoids and externo-internal hemorrhoids, however, there is a limit beyond which it is *possible* to go, but *not wise*.

The author has yet to see a case of internal prolapsing hemorrhoids which he has not been able to remove under local anesthesia. For the occasional operator, however, he would lay down the following rules: In all cases of internal hemorrhoids where not more than five or six separate hemorrhoidal tumors are present, whether prolapsing or not (Fig. 133), operation under local anesthesia is the method of choice. Where more than six distinct hemorrhoidal tumors are present, or where there is a great deal of rectal prolapse complicating, their removal under nitrous oxid and oxygen anesthesia is advised. Where, however, it is deemed unsafe or inexpedient, or where the patient absolutely refuses to take a general anesthetic, the more severe cases can be operated on under local anesthesia by operating at several different sittings, removing two or three hemorrhoids at a time, and then in a month or so removing more, eventually accomplishing the complete removal of all the hemorrhoids in three or four months and by as many operations. In some patients suffering from cardiac, pulmonary, or renal disease, such a method may have to be followed where the administration of a general anesthetic would be absolutely prohibited.

In cases suffering from *interno-external hemorrhoids*, where there are more than five or six separate tumors, their removal should be easily performed by an expert, but where one is in doubt as to his

ability to do so, the same result may be accomplished in two sittings, by removing the external portions at one operation, when, with these out of the way, the internal ones can be removed with ease at the next sitting.

### PROLAPSE OF THE RECTUM

In prolapse of the rectum of the second degree, where the prolapse only involves one half of the circumference of the bowel, local anesthesia may be employed, and the prolapsed portion ligated off in sections. As a general proposition, however, the author does not advise its use. Operations for prolapse have been done by some proctologists under local anesthesia; but the technic is rather crude, and the same satisfactory results cannot be obtained in this hurried method, as are possible under general anesthesia. In prolapse of the third degree (Fig. 185), local anesthesia is obviously contraindicated, as the most successful operation for the reduction of complete prolapse is best accomplished by means of an abdominal operation.

### REMOVAL OF CONCRETIONS

The removal of concretions from the rectum or sigmoid, which are larger than one inch and a half in circumference, should not be attempted under local anesthesia, but can be done very nicely under the anesthesia produced by the administration of nitrous oxid and oxygen. While almost any case of fecal impaction can be relieved under local anesthesia, as has been pointed out in Chapter V, there are some cases in which the procedure fatigues the patient so much that the administration of a general anesthetic may be necessary in order to successfully complete the operation.

### FISTULÆ COMMUNICATING WITH OTHER ORGANS

Operations for fistulæ communicating between the rectum and other adjacent organs should never be attempted under local anesthesia, neither should the *extensive use of the thermocautery* be attempted unless the patient is under profound anesthesia, *if used at all*. Before attempting any operation for relief of any pathological condition discovered in the anus or rectum, the absence of any other dis-

eased condition higher up in the rectum should first be demonstrated by careful proctoscopic and sigmoidoscopic examinations.

Many procedures cautioned against in this chapter are performed by the author in his hospital service under local anesthesia with signal success. There is no limit to the extent of the field of local anesthesia in proctology but the skill of the individual. Until, however, one has by long experience become an adept in its use, caution and conservation should be the watchwords of everyone employing local anesthesia, no matter how simple the case may seem to be.



## CHAPTER XVII

### THE FECES AND THEIR CLINICAL EXAMINATION

It is surprising that in the study of intestinal diseases so little attention has been given to the careful study of the stool. The study of the feces bears the same relation to the study of intestinal derangements as the examination of the urine to the diagnosis of renal diseases.

In order to make this chapter of value to the general practitioner the author has, as far as possible, included only the practical part of *coprology*, omitting those procedures that are of no particular benefit to clinical medicine and those requiring special laboratory training.

Under the term *feces* are comprised all those substances which, being formed from the food in the process of digestion, and mixed with the residue of the secretions of the alimentary canal, are finally expelled by the rectum.

#### GENERAL CHARACTERISTICS OF FECES

**Number of Stools.**—The number of stools in 24 hours varies greatly in different persons, who are apparently in good health. One may have two or three bowel movements in 24 hours, while another may have one in 48 hours; so it is important to ascertain the habitual number of stools, in every individual. There are rare instances in which one stool occurs only in two weeks to four months. It is better, however, to take the general condition of the patient as a guide to the sufficiency of defecation. Some individuals will tolerate infrequent defecations, while others would suffer from copremia under the same conditions.

**Duration of Passage.**—The question of the length of time required for the passage of food through the gastrointestinal canal is a matter of much clinical importance; yet little attention has been paid to the subject. It is quite as important to know the period of passage as to know how often the patient has a stool. A patient may have one stool

a day and yet have latent constipation, which gives rise to toxic symptoms. Whether latent constipation is present can only be determined by estimating the period of passage. In diarrhea, by estimating the period of passage, it is possible to come to an approximate idea of the seat of the disturbance producing the diarrhea. If the period of passage is nearly normal, the trouble lies in the lower or middle portion of the large intestine, and peristalsis is probably not increased in the small intestine. Chronic colitis, with several watery movements a day, may be accompanied by a normal passage. The period is decidedly shortened if the inflammation is in the ascending colon or small bowel. Strauss used a test-diet of 100 grams of lean meat and found the normal period to be 10 to 20 hours. This was increased in cases of constipation to as high as 60 hours. Maurel, using a pure milk diet, gives the normal period 36 to 48 hours. In disease the shortest period was 4 hours, and in such cases the bilirubin is found unaltered. The period of passage is very easily marked by giving a capsule of carmine or charcoal with the meal and watching for the first red or black stool.

**Amount.**—The amount varies in different individuals, depending upon the character of the diet and the condition of the digestive organs. The quantity is increased by a diet rich in vegetables and starchy foods, and diminished by one rich in animal food.

The stool consists of the indigestible portion of the diet, the part of the diet undigested, bacteria, and the secretions of the intestines and their associate glands. Cetti, who fasted 10 days, passed about 22 grams of stool on the average a day. The normal amount varies between 100 and 200 grams in 24 hours.

**Consistency and Form.**—The consistency of the stool depends chiefly upon the amount of water it contains, though there may be soft, thin stools due to abnormal amounts of fat or mucus. Increase of the fluid in the stools may be due to deficient absorption, or to exudate or transudate from the mucous membrane. Increased peristalsis may cause watery stools through failure of absorption, while prolonged retention in the colon or rectum may result in hard, scybulous masses due to excessive absorption of water.

**Odor.**—The odor of the feces is, to a large extent, due to the presence of indol, skatol, sulphuretted hydrogen, and methane.

**Color of Stools.**—The color of the feces varies according to the

nature of the food ingested. The normal color is dark brown. A diet consisting largely of meat gives an intensely brown stool, while a vegetable diet gives a more yellowish shade to the feces. A stool that has been exposed to the air is darker on the outside than on the interior, owing to the process of oxidation. The presence of undigested fats gives a yellowish shade to the stool. If much blood is present the stool may be black or have a tarry appearance. Huckleberries and red wine produce a dark stool; chocolate and cocoa, gray; iron, manganese, and bismuth preparations, a dark or black stool, owing to the formation of the oxids of these metals (Fig. 203). Calomel causes a greenish stool (biliverdin); santonin, rhubarb, and senna produce a yellow color.



Fig. 203.—Sulphid of bismuth crystals from the stools. (Eyepiece III, objective 8A, Reichert.)—Von Jaksch and Cagney: Clinical Diagnosis.

**Macroscopic Elements.**—These are derived either from the food or from the intestinal apparatus itself. It is possible to find stones, cherry pits, grape seeds, skins of various berries or apples, pears, etc., pieces of connective tissue, grains of corn—in fact, almost any part of the food if insufficiently masticated. The presence of casein in the stools of infants appears as small whitish lumps and can, as a rule, be easily recognized. Foreign bodies of almost every description, which are not too large to swallow, may be found in the stools, especially in the stools of children and of the hysterical or of the insane; one may find buttons, coins, pins, false teeth, hair balls, etc.

**Microscopic Elements.**—Microscopically, may be seen indigestible

and undigested portions of the food, as well as substances thrown off by the mucous membrane of the intestines. Thus, starch granules and remnants of chlorophyll, muscle-fibers, elastic-tissue fibers, connective-tissue fibers, flakes of casein, white blood-corpuscles, triple phosphate crystals, micro-organisms, etc., may be seen (Fig. 204).

### CLINICAL EXAMINATION OF THE STOOLS

In order to make the clinical examination of the stools of benefit and satisfactory, we must have a standard for comparison. Schmidt, of Dresden, has formulated a diet to meet this requirement, and it,

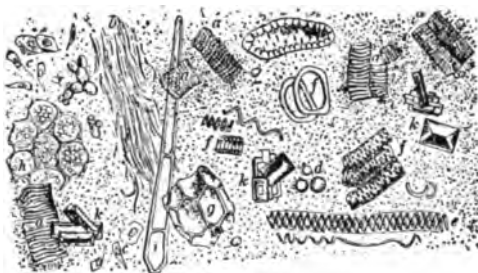


Fig 204.—Collective view of the feces. (Eyepiece III, objective 8A, Reichert.) a, muscle-fibers; b, connective tissue; c, epithelium; d, white blood-corpuscles; e, spiral cells; f-i, various vegetable cells; k, triple phosphate crystals in a mass of various micro-organisms; l, diatoms.—Von Jaksch and Cagney: Clinical Diagnosis.

or some modification, is now in general use by those following this line of work. There are two conditions for the satisfactory clinical examination of the feces:

1. A knowledge of what a normal stool should be under a certain diet.

2. The methods of examination must be as simple as possible.

*The test-diet.*—The requirements are:

- (a) That it must be nutritious enough to furnish calories sufficient for the body's need.

- (b) It must consist of such articles of food as can be obtained in any household.

- (c) It must contain a constant amount of certain articles, so that variation in digestion and absorption can be detected in the stool.

Schmidt's diet is as follows: 1.5 liters of milk, 100 grams of zwieback, 2 eggs, 50 grams butter, 125 grams very rare or raw beef, 190

grams potato, and gruel from 60 grams oatmeal and 20 grams sugar.

This may be divided as follows:

Breakfast.—Two eggs, half liter or two glasses of milk, one third the amount of zwieback and butter, or two slices of well-toasted bread, with butter, and the oatmeal and sugar.

Dinner.—The steak and potatoes, one-third zwieback and butter, and two glasses of milk.

Supper.—Two glasses of milk, and the remainder of toast, or zwieback and butter.

The amounts of each article should be measured or weighed accurately, and the beginning of the test-diet marked by giving a capsule containing carmine or charcoal, preferably the latter, because carmine would interfere with the color reaction in case an examination is made for blood in the stool. This diet should be given for several days. The first black stool will denote the length of time required for the passage of food through the gastrointestinal tract. The examination of the stool consists of the following steps: The consistency, color, and smell must be observed. Then a piece of formed stool the size of a walnut, or an equivalent amount of liquid feces, is rubbed up in a mortar with distilled water until it is quite smooth and liquid. Part of this is poured upon a glass plate or a Petri dish, put over a dark background, and examined in a good light.

In *normal* digestion, very little should be seen by the naked eye except small brown points (oatmeal), and occasionally sago-like grains that look like mucus, but which the microscope shows to be grains of potato.

*Pathologically*, there may be:

1. Mucus in large or small flakes which is not affected by rubbing up in the mortar. The smaller the flakes, the harder they are to recognize. They appear as glassy translucent flakes often stained yellow by bile pigment. If at all doubtful, the microscopic examination will clear it up.

2. Pus, blood if considerable, can be easily detected, as can also parasites, stones, and foreign bodies.

3. Remnants of muscle-fiber appear as small, reddish-brown threads, or small irregular lumps. When they can be easily seen by the naked eye and are quite numerous, it shows impairment of intestinal digestion.

4. Remnants of connective tissue and sinew from the beef-steak can be detected from the mucus by their toughness and whitish-yellow color. If in doubt, a piece may be put on a slide with a drop of acetic acid and examined with the microscope. The connective tissue loses its fibrous structure, while the mucus becomes more thread-like. Small pieces of connective tissue can be found in normal stools, but when they are numerous and large their presence indicates the impairment of gastric digestion.

5. Remnants of potato look like grains of boiled tapioca and may be confused with mucus. Any doubt of the nature of the particles can be cleared up by the microscope.

6. Large crystals of acid phosphate of ammonium and magnesium occur in foul stools, and can be easily recognized by their shape and chemical reaction (solubility in all acids).

### MICROSCOPIC EXAMINATION

For microscopic examination, prepare three slides from the liquid feces.

The first slide—a drop of the material to be examined under high and low power.

The second slide—mix a drop of the material with a drop of acetic acid (U. S. P.), heating it to the boiling point, then put on the cover-glass.

The third slide—a drop of the material with a drop of weak Lugol solution (iodin 1, KI 2, water 50).

*Normal stool.*—Slide one:

(a) Single, small muscle-fibers, colored yellow, usually with a cross striation (Fig. 205).

(b) Small and large yellow crystals of salts of fatty acids.

(c) Colorless particles of soap (gray).

(d) Single potato cells.

(e) Particles of oatmeal.

In the second slide a general idea of the fat content of the stool can be obtained. Upon cooling, small flakes of fat acids can be seen. The large crystals of salts of fatty acids and the soap are broken up by the acetic acid, and fat acids are liberated. If the slide is heated again and examined while hot, the fat acids will be seen to run together in drops, which, as the slide cools, break suddenly apart.

In the third slide, there should be violet-blue grains in some of the potato cells, and small, single blue points, probably fungi spores.

*Pathologically there may be.*—Slide 1:

- (a) Muscle-fiber in excess, perhaps with yellow nuclei.
- (b) Neutral fat drops or fatty acids in crystals.
- (c) An excess of potato cells with more or less well-preserved contents.

(d) Parasite eggs, mucus, connective tissue, pus, etc.

Slide 2: Fat acid flakes in excess.

Slide 3: Blue starch grains in potato cells or free oatmeal cells, fungus spores or mycelia.



Fig. 205.—Muscle remnants in feces. (Leitz objective VII.) a, large; b, medium; and c, small fragments.—From Schmidt and Strassburger.

## CHEMICAL EXAMINATION

**Reaction.**—The reaction of the stool is hard to get with litmus paper, but can be easily obtained by dropping a little softened fecal matter into 5 or 10 cubic centimeters of a weak, watery solution of litmus, shaking it and noticing the change. It is well to use another test-tube with the litmus solution only, as a control. The test should always be made with freshly passed feces, inasmuch as the reaction of the feces may change upon standing.

**Sublimite Test.**—Consists of taking a few cubic centimeters of the liquid feces and mixing it with an equal amount of 25 per cent watery solution of mercuric chlorid. A normal stool will turn a pinkish-red, indicating the presence of hydro-bilirubin, which will be more intense the fresher the material. A green color, even if it is detected microscopically, is pathologic and indicates unchanged bile pigment.

**Fermentation Test.**—About 5 grams of freshly formed feces are taken, or ~~an equivalent amount~~ of thinner material. Steele's fermentation apparatus, a modification of Strassburger's, is used. It is constructed of perforated rubber corks, bent glass-tubing, and two test-tubes of 30 cubic centimeters capacity (Fig. 206). A small glass tube runs up to the top of the test-tube (C) to allow for the escape of air.




Fig. 206.—Steele's modification of Strassburger's fermentation apparatus. It is constructed of perforated rubber corks, bent-glass tubing, and two test-tubes, each of 30 cubic centimeters capacity. The small glass tube D runs up to the top of the test tube C, to allow for the escape of air, instead of the test-tube being perforated, as in Strassburger's apparatus.—*Progressive Medicine*, December, 1905.

The stool is rubbed up with sterile water and poured into the main bottle (A).

This is filled with sterile water; tube B is filled with water and fitted in place, and tube C is then fitted on empty. The reaction is



carefully noted before the test is started. The apparatus is then stood in a warm place for 24 hours, best in an incubator at 37° C. If gas forms by fermentation in A, it will rise into B, and the amount will be indicated by the water displaced into C. Normally, the fermentation test should show practically no gas, and the original reaction should be unchanged for 24 hours. If more than one-third of the

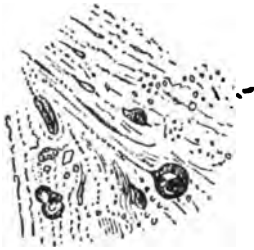


Fig. 207.—Mucus shreds.—From Schmidt and Strassburger.

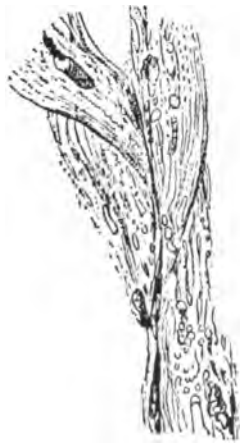

Fig. 208.—Mucus shreds after the addition of acetic acid.—Hensel, Weil, and Jelliffe: *Urine and Feces in Diagnosis*.

tube C is filled, it is pathologic. If, then, the reaction is decidedly more acid, it is a carbohydrate fermentation; if alkaline and with a foul smell, it is a fermentation of albumins.

**Estimation of Lost Albumin Residue.**—A qualitative test may be made as follows:

A softened portion of the stool is filtered; the filtrate shaken with silicon and refiltered; then it is saturated with acetic acid to bring down the nucleo-proteids; after filtration a drop of ferrocyanid solution is added. A decided precipitate indicates albumin.

It was formerly thought that a positive test shows a diminution of albumin digestion, but the work of recent investigators would indicate that this is not the case. Under pathologic conditions, the nucleo-proteids may be decidedly increased, although their presence is not characteristic of any particular disease. Other forms of albumin are rarely found in the feces, even after the ingestion of excessive amounts. The occurrence of albumin in the feces of adults is almost always associated with diarrhea, and usually with an excessive formation of mucus. It usually is serum-albumin, much less frequently albumoses. Such "lost albumin" in the stools indicates severe anatomical changes in the bowel, but usually not disturbance of absorption. The albumin under these circumstances comes from the intestinal wall, and sometimes a part of it may be digested by the intestinal ferments into albumoses.

### CLINICAL SIGNIFICANCE OF TEST

**Mucus.**—There are two conditions in which the presence of mucus in the stools has no significance: when hard, dry masses of feces are covered with thin mucus, without evidence of rectal inflammation; and when it is discharged in casts, the so-called mucous colic. Otherwise it indicates inflammation of the intestinal mucous membrane. If it is densely impregnated with bacteria, food remnants, and detritus, the origin of the inflammation is probably high up in the intestine (Figs. 207, 208).

**Bilirubin.**—Bilirubin discoloration affords no certain evidence of inflammation of the small intestine, but the presence of bilirubin granules and crystals in a cellular arrangement is suggestive.

**Semidigested Cells.**—The presence of semidigested cells or of their nuclei indicates an origin high up in the bowel.

**Hyaline Cells.**—The presence of hyaline cells favors the assumption that an inflammation of the colon exists.

**Bile Pigment.**—A green color of part or all of a stool, by the sublimate test, is pathologic, except in children. It means a too short period of passage through the intestine, and that time for a normal

reduction process of the bilirubin into hydro-bilirubin was lacking. A normal fresh stool will give a pink color with mercuric chlorid. If a color reaction of any kind is absent, it indicates a very fat stool, or an absence of bile in the intestine (Figs. 209, 210).

The assumption of the temporary stoppage of the bile does not account for all of the cases of colorless feces which do not darken on exposure. The pathologic conditions in which colorless feces



Fig. 209.—Hematoidin crystals from acholic stools. (Eyepiece III, objective 8A, Reichert.)  
—Von Jaksch and Cagney.




Fig. 210.—Acholic stools. (Eyepiece III, objective 1-15, oil immersion, Reichert, Abbe's mirror, narrow diaphragm.)—Von Jaksch and Cagney.

without jaundice may occur comprise defective supply of bile to the duodenum, intestinal catarrh, tuberculous abdominal disease, malignant disease of the intestine, septic diseases (especially those which affect the abdomen), chlorosis, and leucemia.

**Fat.**—It will need a little practice to tell, by the use of the diet, whether there is an increase of fat in the stool. As the normal amount of fat in the feces varies between wide limits, only a considerable excess of fat can be detected.

**Remnants of Meat.**—Normally there should be only microscopic particles of connective tissue and muscle-fiber. An excess of either is often visible to the naked eye, but need not be macroscopic to be pathologic.

**Excess of Connective Tissue.**—This indicates insufficient gastric digestion, because such fibrous tissue is only digested by the gastric juice. The meat should be rare, to give this test its full value. If motility is increased, there may be an excess of this in hyperacidity.

**Excess of Undigested Muscle-Fiber.**—This indicates intestinal indigestion and probably means trouble in the upper part of the small intestine; but whether the trouble is in the trypsin of the pancreatic secretion, or the activating principle (enterokinase) of the intestinal juice, or in increased peristalsis, we can only judge from other symptoms. When the gastric juice fails to digest away the framework of the muscle-fiber, giving the intestinal juices no chance to do their work, connective tissue and muscle-fiber are often found. This occurs often in acute gastric catarrh.

**Pathologic Carbohydrate Fermentation.**—This means poor starch digestion and indicates, as a rule, disturbance in the small intestine, and usually is due to insufficiency of the succus entericus.

**Pathologic Albumin Fermentation.**—This means a large residue of albumin in the feces and indicates usually some anatomical change in the mucous membrane of the small intestine.

**Pus.**—This can be rarely recognized in the stool unless it comes from the lower part of the large bowel; if it comes from high up in the intestine, it is rapidly changed.

**Blood in the Stools.**—The presence of blood in such quantities as to be visible is considered in Chapter II, so I will only consider the so-called occult blood in the stools. The presence of occult bleeding from the gastrointestinal tract is a symptom of much importance, provided various sources of error can be eliminated. It has the same clinical significance as visible hemorrhage, and its presence is of decided diagnostic value, chiefly in the detection of gastric or duodenal ulcer, or gastrointestinal cancer, because it occurs with considerably more regularity and frequency in these affections than in any other condition of the gastrointestinal tract.

The value of this sign depends entirely upon the care with which the various sources of error are eliminated, and if the reaction is positive, will be of value in the diagnosis of cancer or ulcer of the gastrointestinal tract only when sources of bleeding that have no significance are excluded. On the other hand, after repeated examinations, if occult blood is not found, then cancer or ulcer can be excluded. Since the test is very sensitive (very small amounts can be detected), the chance for error in determining the origin of the hemorrhage is greater than in large and visible hemorrhages. Observations have shown a positive reaction in the feces on the ingestion of 0.5 grams of blood. It is possible to exclude the source of the blood when in the lower bowel by the use of the proctoscope, etc. Tuberculous ulcer, typhoid fever, hemorrhoids, fissure, and purpura can be easily excluded; other conditions, however—e. g., cirrhosis of the liver with slight symptoms—may be the cause of error. Red beets, carmine, swallowed blood from any cause, hemoptysis, epistaxis, menstruation, cirrhosis of the liver, purpura, benign stenosis with stagnation, tuberculous enteritis, cancer of the gastrointestinal tract, gastric or duodenal ulcer, typhoid ulcer, hemophilia, hemorrhoids, ulcer, fissure, and fistula of the anus and rectum are a partial list of conditions which may give a positive reaction with the various tests.

When testing for occult blood it is best to have the patient on a diet free from meats and meat juices and to give a good-sized capsule of charcoal; the first black stool will mark the feces following the meat-free diet.

A number of different tests are used for the detection of occult blood; probably the Weber test, with its various modifications, is the one most employed. It is well, however, to use a control test, preferably Klunge's aloin test. If both tests give a positive reaction, there is no doubt but that there is blood in the stools. The latter is not liable to be obscured by bile pigments or chlorophyll, in the ethereal extract, and is extremely delicate.

**WEBER'S TEST.**—Take 2 or 3 grams of feces, mix thoroughly with 20 cubic centimeters of water; extract with 20 cubic centimeters of ether to remove fats. Then use one-third the volume of acetic acid and shake well; add 10 cubic centimeters of ether and shake well. If ether does not come to the top soon, add a few drops of absolute alcohol. To 2 cubic centimeters of the ethereal extract, add 10 drops freshly prepared tincture of guaiac and 10 to 20 drops of ozonized tur-

pentine. Care must be taken that all utensils are absolutely clean and free from water. If blood is present, an intense blue color appears, gradually assuming a reddish-violet tint.

**KLUNGE'S ALOIN TEST.**—Take a small quantity of aloin, mix with 3 to 5 cubic centimeters of 70 per cent alcohol. Four to five cubic centimeters of acetic acid ethereal extract is tried with 20 to 30 drops of ozonized turpentine and 10 to 15 drops of the aloin solution. If blood is present, a bright-red color appears, which turns to a cherry-red on standing. If blood is not present, a yellow color remains for an hour or two, then becomes pink. It may take 15 or 20 minutes to get a positive reaction.

**HOLLAND'S MODIFICATION OF WEBER'S TEST.**—Instead of using ozonized turpentine, Holland uses sodium perborate (Shering) in tablet form; a few drops of the acetic acid-ether mixture is placed upon a small piece of tablet of perborate of sodium, and a drop or two of the tincture of guaiac is cautiously brought into contact with it, preferably on a white plate. If blood is present, the perborate turns blue in a few minutes and remains blue until the drying of the tincture of




Fig. 211.—Gallstones.

guaiac leaves a yellow residue which changes the blue to green. If the proportion of blood is small, the perborate turns a pale blue, which turns green as the guaiac dries.

**BENZIDIN TEST.**—A little benzidin and about 2 cubic centimeters glacial acetic acid are shaken up together and set aside for the benzidin to dissolve. A piece of feces the size of a bean is stirred into a test-tube about one-fifth full of water; the tube is plugged with cotton, and the suspension of fecal matter is heated to a boiling point over a flame. About 10 or 12 drops of the concentrated benzidin solution are poured into another test-tube, from 2 to 2.5 cubic centimeters of a 3 per cent solution of peroxid of hydrogen added. One or two drops of the boiled suspension of feces are then added to this mixture. If blood is present in the feces, this brownish fluid turns green or blue; the more blood the more the test inclines to blue. The color reaction occurs within two minutes in the presence of blood and turns to a dirty-purple in five to fifteen minutes. If there is no blood present, the dirty-brown color remains unaltered.

**Gallstones.**—In cases of colicky abdominal pain, the feces should always be examined for biliary concretions. The best way to search for gallstones is to put the feces in a fine sieve and wash the stool

with running water from a faucet, if possible. The concretions vary in size from as small as the head of a pin to the size of a pigeon's egg. They may be seen as small crumbling masses, as hard stones presenting an irregular contour, or as smooth facets (Fig. 211). The larger stones are not passed by the bowel unless perforation has occurred into the intestine. The composition of the calculi varies. Some are composed of cholesterin; some of inspissated bile; and others of calcareous salts. Those composed of cholesterin are the most common and are somewhat soft, and white, grayish, bluish, or greenish in color. I think that the consensus of opinion inclines to the belief that the nucleus of the majority of gallstones is clumps of bacteria, either colon or typhoid bacilli, although it may be composed of earthy sulphates or phosphates. Calculi which consist largely of biliary pigments are brown in color, hard, and heavier than water; those composed of calcareous salts are generally irregular and rough.

*Intestinal concretions*, or enteroliths, are rare. At times their nucleus consists of some foreign body like a fruit seed, upon which calcium and magnesium salts have become deposited.

*Intestinal sand* is hard, gritty, pale brown to black in color, readily sinks in water, and is usually composed of the salts of calcium magnesium and ammonium. Sometimes silica is present.

### ANIMAL PARASITES

**Protozoa.**—Of the protozoa, the amebæ (Chapter XIII) are the most important in the etiology of intestinal disease. It is possible to find amebæ in the stools of perfectly normal individuals, and they increase in number as the stools become more alkaline in reaction.

**AMÆBA COLI.**—In certain forms of dysentery the *Amæba coli* occur in the stool in enormous numbers, chiefly embedded in the mucus. They are also found on pathologic examination in the ulcers in the intestines. In examining, the stool must be fresh, as the amebæ very rapidly die off in a stool that has been preserved but a few hours. A particle of mucus, preferably blood streaked, is taken from a fresh stool and placed on a chemically clean slide, better, a warm stage. In adjusting the cover-glass, a horsehair or some similar object should be placed between it

and the slide, in order not to crush the organisms or interfere with their locomotion. Examine with a low-power microscope. They are from 10 to 50 micromillimeters in size. When at rest, their outline is, as a rule, circular or ovoid; when in motion, they present one or more arm-like prolongations, "the pseudopodia." The protoplasm can be differentiated into a translucent, homogenous ectosarc or mobile portion and a granular endosarc

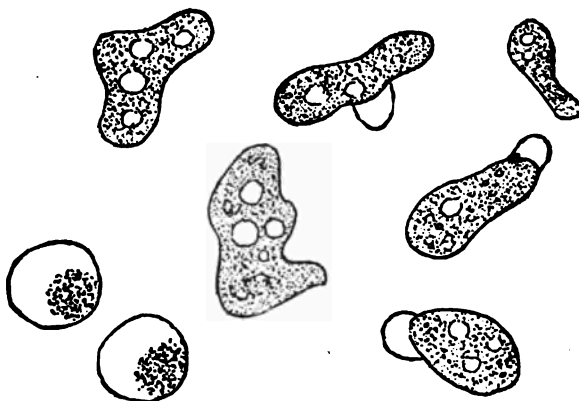


Fig. 212.—Amœba coli.—Simon: Clinical Diagnosis.

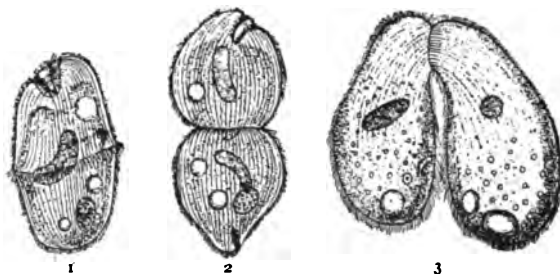


Fig. 213.—Balantidium coli.—1 and 2, stages of division; 3, conjugation.—After Leuckart, Progressive Medicine, December, 1905.

containing the nucleus, vacuoles, and granules (Fig. 212). As a rule, one or two vacuoles are present, the edges of which are not infrequently surrounded by fine, dark granules.

**BALANTIDIUM COLI.**—Another form of protozoön, that is an etiologic factor in certain forms of dysentery, is the *Balantidium coli*. This organism is a harmless inhabitant of the colon of the



pig, and it is supposed, is transferred to human beings through sausages (Fig. 213). The parasite is of oval shape, 60 to 100 microns long and 50 to 70 broad, and is covered with cilia that are in rapid motion when the organism is alive. Ectosarc and endosarc are sharply differentiated. The endosarc is granular and contains a kidney-shaped nucleus, generally two contractile vacuoles, and granular detritus. Motion is so rapid that it cannot be followed under the microscope. The protozoön dies very quickly and undergoes fragmentation.

There are other forms of protozoa, but their rôle in the etiology of intestinal diseases is not definitely settled.

**Worms.**—The diagnosis of helminthiasis from the stools may be very easy, or it may require considerable painstaking research. If segments of the tenia pass in the stools, the diagnosis is quite evident. In other cases, a diagnosis can only be made by finding the ova in the feces. To examine for the ova, take a small amount of feces from different parts of the stool, dilute it very much with sterile water, and centrifuge repeatedly. After each centrifugation, the supernatant dirty water is thrown away, and fresh water is added, the whole shaken up and again placed in the centrifuge, this to be repeated five or six times. In this way all bacteria, free coloring matter, light vegetable matter, etc., are removed, and only heavier particles, including any ova that may be present, will remain and can be easily and satisfactorily examined under a low power of the microscope. There is left no obscuring cloud of bacteria or fine granular débris, but instead, each ovum, or muscle-fiber, or crystal stands out sharply and clearly.

**NEMATODES.**—Nematodes are round worms. Those found in the human being are:

1. *Ascaris lumbricoides* is the most common parasite of the human intestinal canal. They are found chiefly in the small intestines but may find their way into the stomach, the bile passages, or out at the anus. Clumps of them have been known to cause intestinal obstruction.

The worm is cylindrical, the male being from 10 to 25 centimeters in length, the female from 25 to 40 centimeters. The head consists of three projections or lips, which are provided with suckers and fine teeth. The tail end of the male is rolled

up on its central surface like a hook and is provided with papillæ. The genital aperture of the female is situated directly behind the anterior third of the body. The eggs are yellowish-brown in color, almost round, and measure 0.06 millimeters by 0.07 millimeters in size. They are surrounded by an irregular albuminous envelope, which is covered by a tough shell; the contents are coarsely granular (Fig. 214).

2. *Oxyuris vermicularis* (common threadworm, seatworm, pinworm, etc.) is a very frequent parasite, especially in young chil-

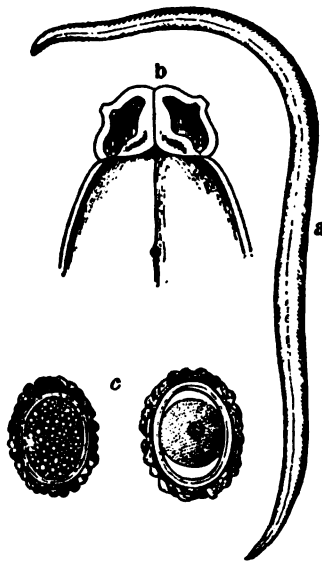


Fig. 214.—*Ascaris lumbricoides*. a, the worm; b, the head; c, egg; a, half natural size; b, slightly magnified; c, eyepiece 1, objective 8A Reichert.—Von Jaksch and Cagney: Clinical Diagnosis.

dren, often passing from the anus into the vulva in female children and setting up considerable irritation in the vagina. The male is 4 millimeters, the female 10 millimeters, long. At the head three lip-like projections with lateral cuticular thickenings may be seen. The tail of the male is provided with six pairs of papillæ, and the female with two uteri. The eggs are 0.05 by 0.02 to 0.03 millimeters in size, and covered with a membrane showing a double or triple contour. In the interior, which is coarsely granular, the embryo is contained. The ova do not occur in the feces (Figs. 215, 216).

*Ankylostoma duodenale*, or *Dochmius duodenalis*, or *Strongylus duodenalis* is generally described in America as *Uncinaria*. It was formerly supposed that this parasite was found only in the Old World and only brought into this country, but it has been demonstrated that there are many endemic cases in our Southern states.

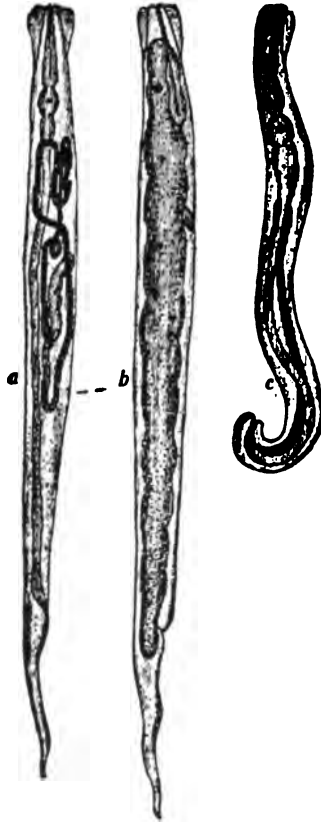


Fig. 215.—*Oxyuris vermicularis*. a, sexually mature female; b, female filled with eggs; c, male. Magnification, X10.—After Heller, from Zeigler.

There are certain differences between the American and Old World parasite.

Stiles<sup>1</sup> gives the following description:

*Uncinaria duodenalis*.—The Old World hookworm. Body cylindrical, somewhat attenuated anteriorly; buccal cavity with two pairs of ventral teeth curved

<sup>1</sup>Bulletin No. 10 Hygienic Laboratory, U. S. Public Health and Marine Hospital Service.

like hooks, and one pair of dorsal teeth directed backward; dorsal rib not projecting into cavity. Male 8 to 11 millimeters long, caudal bursæ with dorso-medial lobe and prominent lateral lobes united by a ventral and slender. Female, 10 to 11 millimeters long; vulva at or near posterior third of body. Eggs ellipsoid, 52 to 60 micromillimeters by 32 micromillimeters, laid in segmentation. Development direct without intervening host (Fig. 217).

*Uncinaria americana*.—The New World hookworm of man: Body cylindrical, somewhat attenuated anteriorly; buccal capsule with a dorsal pair of prominent semilunar plates or lips and a ventral pair of slightly developed lips of same nature; dorsal conical median tooth projects prominently into buccal cavity. Male 7 millimeters long, caudal bursæ with short dorso-medial lobe, which often appears as if it were divided into two lobes, and with prominent lateral lobes united ventrally by an indistinct ventral lobe; common base of the dorsal and dorso-lateral rays very short; dorsal ray divided to its base, its two branches being




Fig. 216.—*Oxyuris vermicularis*. 1a, male; 1b, female, natural size; 2, magnified.—Hensel, Weil, and Jelliffe: *Urine and Feces in Diagnosis*.

widely divergent, and their tips being bipartite; spicules long and slender. Female 9 to 11 millimeters long; vulva in anterior half of body but near equator. Eggs ellipsoid, 64 to 76 micromillimeters long by 36 to 40 micromillimeters broad, in some cases partially segmented *in utero*; in others containing a fully developed embryo oviposited.

The eggs of the American species are much larger than those of the Old World species. The eggs have a transparent shell with a linear contour and are often found in enormous quantities in the feces. A rather peculiar fact is that the ova of *uncinaria*, although sticking closely to the glass slide, do not seem to adhere to any of the other constituents of the stool. When a drop of washed sediment feces is allowed to remain on the

slide for a few minutes and then gently immersed in water and examined microscopically, the eggs are found adhering to the slide, and all else has been washed away. In suspected cases where the diagnosis is difficult, a full dose of thymol may make it clear, causing the appearance in the stool of the parasite, which appears as a thread-like body, a half to three quarters of an inch long, grayish-red in color. Its habitat is the jejunum and duodenum. Infection takes place through contaminated drinking water.

For persons who are not in a position to make a microscopic examination, the blotting-paper test will be found very useful.

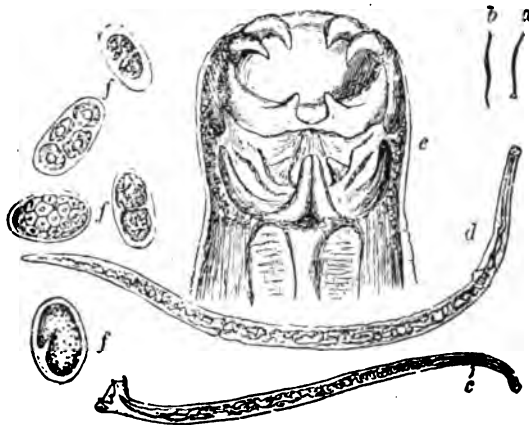


Fig. 217.—*Anklostomum duodenale*.—Von Jaksch and Cagney.

- a. Male (natural size).
- b. Female (natural size).
- c. Male (magnified).
- d. Female (magnified).
- e. Head (eyepiece II, objective C, Zeiss).
- f. Eggs.

To make the test use only fresh feces. Place an ounce or more of the stool on a piece of white blotting paper, allowing it to remain for 20 to 60 minutes; remove the feces, and examine the color of the stain. In about 75 per cent of the cases of medium or severe uncinariasis, the stain is a reddish-brown, resembling somewhat a blood stain. In making this test on anemic patients, hemorrhoids must be excluded.

*Trichocephalus dispar*, or "whip worm," frequent in most parts of the world, gets its name from being formed like a whip, the

lash end being the head end, while the tail end is very much thicker. The male measures 46 millimeters and the female 50 millimeters in length. The eggs are brownish in color, 0.05 by 0.06 millimeters in size, presenting a double-contoured shell with a depression at each end, closed by a lid. The contents are coarsely granular. Its habitat is in the cecum; the living worm is rarely found in the feces (Fig. 218).

*Trichina spiralis*.—The male is 1.5 millimeters in length, and the female 3 millimeters. The male has four prominent papillæ,

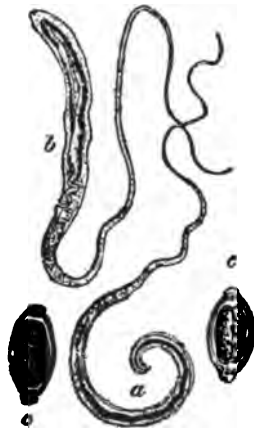


Fig. 218.—*Trichocephalus dispar*. a, male; b, female; c, eggs; a, b, slightly magnified; c, eyepiece II, objective 8A, Reichert.—Von Jaksch and Cagney.

situated between the conical protuberances at the extremity. The female's sexual organs consist of a tubular ovary which is placed at the hinder part of the body and a tubular uterus with which the ovary communicates in front. Impregnation takes place in the intestine. The eggs develop into embryos while still in the uterus, and the newly born parasite almost immediately perforates the intestine and becomes imbedded in the muscles of its host. The mode of infection is through imperfectly cooked pork. Rarely is the parasite found in the stools. In suspected cases an anthelmintic may cause the expulsion of the mature worm in the stool. Eosinophilia is a constant accompaniment of the presence of trichina (Fig. 219).

www.libtool.com.cn

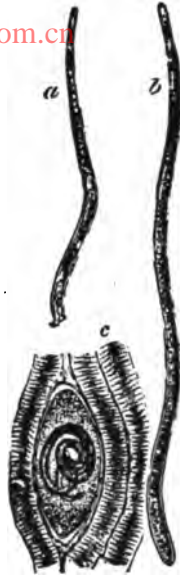

Fig. 219.—Trichinae.—Von Jaksch and Cagney.  
 a. Male intestinal trichina (slightly magnified).  
 b. Female intestinal trichina (slightly magnified).  
 c. Trichina of muscle (eyepiece III, objective IV, Reichert).

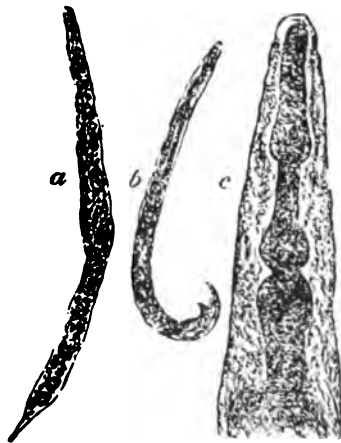


Fig. 220.—*Anguillula stercoralis*.—Von Jaksch and Cagney.  
 a. Female.  
 b. Male.  
 c. Head (eyepiece II, objective 8A, Reichert).

*Anguillula intestinalis* is 2.25 millimeters in length and 0.04 millimeters in thickness at its middle. It has a triangular mouth closed by three lips. Its vulva lies at the junction of the middle with the posterior third. Its habitat is the small intestines. The eggs resemble those of *Ankylostoma duodenale*, but are longer, more elliptical, and pointed at the poles. In recent stools the larvæ alone can be seen. When sexually mature, it is known as *Anguillula stercoralis*; the body is round; it shows faint traces of transverse striation. The head is of the form of a blunt cone and sessile on the body, and is furnished with two lateral jaws, each bearing a pair of teeth. The male is 0.88 millimeters and the female 1.2 millimeters long. Little is known concerning the manner of infection. Thayer reported the first case of infection by this worm in the U. S. (Fig. 220).

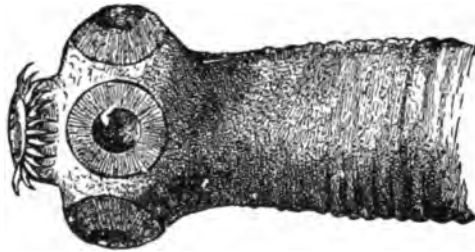


Fig. 221.—Head of *Tænia solium*.—X45 (Leuckart).

**CESTODE WORMS.**—Cestodes are popularly known as tapeworms. Externally they are long, flattened, segmented worms. The head is derived from the embryo contained in the flesh of the various domestic animals which are used as food. By budding it gives rise to all of the succeeding segments, which are morphologically the same, diminishing in size toward the head.

*Tænia solium*.—The tapeworm derived from pork may be two to three meters long. Head quadrilateral, about as large as a pinhead; it has four prominent suckorial discs, usually pigmented, and between them a rounded elevation which is surrounded with about 26 hooklets of different sizes, and is dark in color. This is succeeded by a delicate thread-like neck, about one inch in length and unjointed. The segments or proglottides are short and relatively broad near the neck; the average length of the mature segments is from 9 to 10 millimeters, and the breadth is 6 to 7 mil-



limeters. Each segment contains a uterus having five or seven branches. The ova are round, of a brownish color, and surrounded with a thick radially striated membrane; in their interior the hooklets of the embryos can usually be made out (Fig. 221).

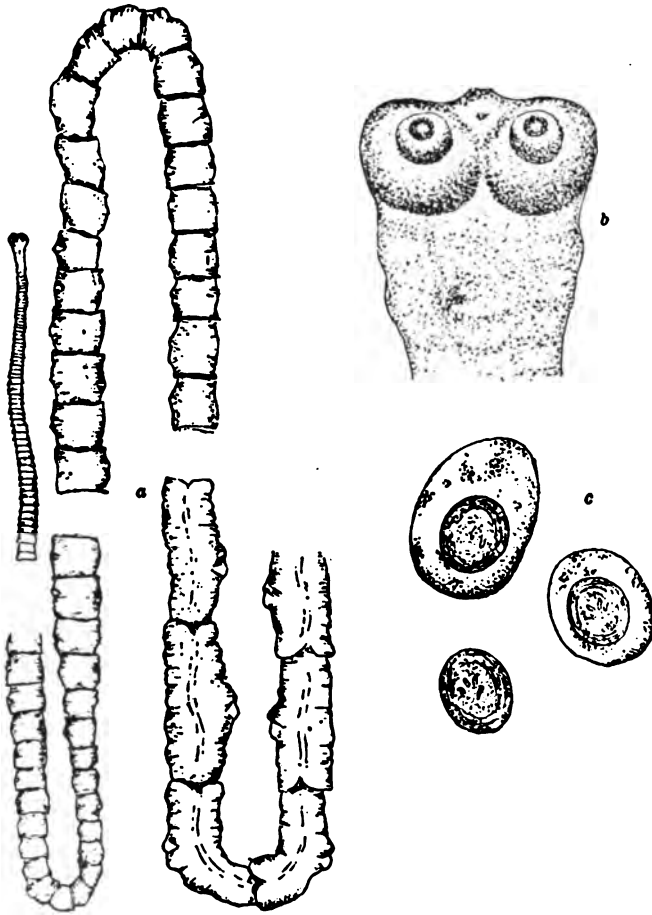


Fig. 222.—*Tænia saginata*.—Simon: Clinical Diagnosis.

- a. Natural size.
- b. Head much enlarged.
- c. Ova much enlarged.

*Tænia saginata* (*Medio cannulata*).—The most frequent tapeworm of Europe and America, infection taking place through measly beef. It is from 4 to 8 meters long. The head is surrounded with

four large and usually black-pigmented suckers, but is not provided with a rostellum, and is without a circle of hooklets. Segments are rather thick and opaque, and each is provided with a very much-branched uterus which opens laterally. The ova are elliptical in form, of a brown color, and usually inclosed in a distinct vitelline membrane. In the interior the embryos are seen embedded in a brown granular material (Fig. 222).

*Tania nana*.—Occurs rarely in America, mostly in Southern Italy. It is 7 to 15 millimeters long. It occurs in large numbers, and is usually located in the lower part of the ileum. It has four suckers and a crown of hooklets. The segments are of a yellowish color and about four times as broad as long. The uterus is oblong and contains numerous ova, having two distinct mem-




Fig. 223.—Head of *Bothriocephalus latus*. (Eyepiece III, objective IV, Reichert).—Von Jaksch and Cagney.

- a. Seen on edge.
- b. Seen on the flat.
- c. Proglottides.
- d. Eggs.

branes. In the interior of the egg may be seen the embryo already provided with five or six hooklets. Infection probably occurs from man to man. The parasites may be present in great numbers in the intestines, producing severe nervous symptoms, such as epileptic seizures, insensibility, mental derangements, etc.

*Bothriocephalus latus*.—The longest of the human tapeworms has been found in the United States in only a few imported cases. The larvæ have been found in various fishes. It is from five to eight meters long and tapers toward both extremities. The largest segments measure 35 millimeters in length, 10 to 12 millimeters in breadth. The head is ovoid, 25 millimeters long and 10 millimeters broad, somewhat flattened, and provided in each lateral aspect with a groove-like sucking apparatus. The uterus is a

slightly convoluted canal. The eggs are ovoid, 0.07 millimeters by 0.045 millimeters, and possess a thin brown capsule and open by a small lid at one end. This parasite may be the cause of severe anemia (Fig. 223).

### CHARACTER OF THE FECES IN CERTAIN INTESTINAL AFFECTIONS

**Acute Intestinal Catarrh.**—This follows the ingestion of excessive quantities of normal food or tainted food, beer and certain poisons, acids or alkalies, arsenic, corrosive sublimate, etc., when taken in proper quantities; also find it in cholera nostras, typhoid fever, severe malaria, and in diseases of heart, lungs, and liver due to disturbance in circulation. The frequency of the stools depends largely upon the seat of the lesion, involvement of the large intestine, especially the transverse and descending colon, causing the bowels to move more frequently than trouble higher up. There may be from 10 to 15 passages a day. On the other hand, isolated catarrh of the small intestine may exist without giving rise to diarrhea. The stools at first are semisolid, but rapidly become liquid, often foul-smelling, and associated with gas. The higher in the bowel the lesion, the more odor and gas. The color varies from a light to a dark brown. If the trouble exists in the small bowel only, the stools are firm, formed, and contain particles of hyaline mucus, visible only upon microscopic examination. They usually contain particles of undigested food. If the colon is affected, the stools are loose. Extensive involvement of the colon is usually accompanied by mucus in large quantities.

**Chronic Inflammation of the Intestine.**—May follow an acute attack, or may follow some of the infectious diseases. Diarrhea usually alternates with constipation. Rarer is continuous diarrhea or constipation. The feces present the same characteristics as the acute inflammations.

**Diphtheritic Enteritis.**—Always diarrhea, often with tenesmus. Stools fluid, with occasional passage of formed feces. They consist mostly of pus, blood, and mucus, and some necrotic tissue may be found.

**Mucomembranous Colitis.**—No frequency in number of stools; may have ~~new constipation.~~ Stools are composed largely of tough leathery mucus, which may present casts of the bowel. This may be transparent or gray and semiopaque, or may be brown (from fecal matter), or red (blood).

**Cholera Nostras.**—An infectious disease affecting both the stomach and bowels. The stools are first feculent, but soon become colorless and more and more watery, until they resemble the so-called "rice-water" stools of Asiatic cholera, and contain serum-albumin and mucin.

**Dysentery.**—Stools are large and frequently composed of pus, mucus, and blood, fluid or semifluid; may find necrotic masses of mucous membrane.

**Amebic Dysentery.**—Stools are frequent, fluid, and may contain large amounts of mucus, frequently stained with blood; reaction always alkaline. Microscopic examination of the fresh mucus shows epithelial and red blood-cells and the ameba.

**Carcinoma of the Small Intestine.**—The stools of which have no distinctive feature.

**Carcinoma of the Rectum and Sigmoid.**—This is taken up elsewhere in this volume (Chapter XVI).

## SYMPTOM INDEX

A patient consults his physician, not with a diagnosis, or a disease, but with symptoms. The history of these symptoms plus the results of the physician's examination gives the evidence on which the diagnosis is founded. On the diagnosis, the treatment and the cure depend.

In the clinical investigation of every case certain symptoms loom up more prominently than others. The most important, and vital, are, however, not always the most prominent in the patient's mind when he first consults his physician.

This index of symptoms is presented with a view to more readily assist the practitioner in following down the list of symptoms in a given case to a diagnosis.

For example: A patient gives the symptoms of pain of sudden onset, slight bright red hemorrhage with stool, acute constipation, and spasm of the sphincters. Look up the references under the headings of pain, hemorrhage, bright red; constipation, acute; and spasm, sphincteric. It will be found that fissure of the Anus, Acute, causes all of these symptoms, and examination will verify this diagnosis.

**Acne.** (See Skin Diseases.)

**Altered Stools.** (See Feces.)

**Anemia.** (See Hemorrhage). Cancer, ulcerative colitis, proctitis, internal hemorrhoids, dysentery, polyposis.

**Ataxia, Sphincteric.** Tabes dorsalis, spinal disease.

**Bad Breath.** Constipation, colitis, cancer, impacted feces, obstipation.

**Backache, Sacral,** hemorrhoids, intestinal cancer, colitis, proctitis, prolapse of rectum, constipation, obstipation, impacted feces, dysentery.

**Bleeding.** (See Hemorrhage.)

**Black Stools.** Cancer or Ulceration located in stomach or small intestine.

**Blood in Stools.** (See Hemorrhage.)

**Boils.** (See Skin Diseases.) Abscess, tegumentary.

**Casts.** Mucous, colitis, dysentery.

**Colicky Pains.** Colitis, proctitis, constipation, obstipation, intoxications, impacted feces, rectal stricture, cancer.

**Constipation.** (See Chapter IV.)

**Cramps.** (See colicky pains.)

**Defecation, Diminished.** (See Constipation.)

*increased.* Diarrhea colitis, proctitis, cancer, ulcer, polyposis, foreign body in rectum, intoxications, hypercatharsis.

**Diarrhea.** (See Defecation, increased.)

**Discharge.** (See Hemorrhage, mucus, pus.)

**Disturbance, Menstrual.** (See anemia—hemorrhage.) Rectal ulcer, obstipation, constipation, hemorrhoids internal.

*of sleep.* Pruritus ani, intestinal parasites, anal fissure.

*of urination.* Cancer, rectal ulcer and fissure, stricture, impacted feces.

**Elevations,** abscess, hemorrhoids external, condyloma, cancer.

**Feces, blood in** (Chapters II, XVI, XVII.)

*hard.* Impaction, constipation, obstipation.

*impacted.* (See Chapt. V.)

*liquid* (diarrhea). Enterocolitis, proctitis, dysentery, intoxication, indigestion, cancer, rectal ulcer, polyposis.

*mucous.* (See Feces, liquid.)

*parasites in.* (See Chapt. XVII.)

*pus in.* Abscess, fistula, sinus, cancer, ulceration.

*ribbon.* Stricture, hypertrophied rectal valves.

**Fever.** Abscess, constipation, colitis, proctitis, impacted feces, intoxication, dysentery.

**Flatulence.** Constipation, obstipation, colitis, dysentery, cancer, indigestion, intoxication.

**Gas.** (see Flatulence.)

**Headache.** Constipation, obstipation, impaction, intoxication.

**Hemorrhage.** (Chapts. II, XVI, XVII.)

*bright colored.* Cancer of anus, rectum or sigmoid, ulcer of same organs, polyposis, anal fissure stricture, internal hemorrhoids, traumatism, foreign body.

*dark colored.* Cancer or ulcer of small intestine or stomach, retained rectal or colonic hemorrhage.

**Inflammation.** (see Chapts. VII, VIII.)

**Involuntary Defecation.** (See Loss of sphincteric control.)

**Itching.** (See Chapt. VI.)

**Loss of Sphincteric Control.** (See ataxia.) Tabes dorsalis, spinal diseases, traumatism, previous operative injury, anal ulceration, lacerated perineum.

**Mucus in stools.** (Chapts. III, XII, XIII, XVII.) (See Feces Liquid) foreign body.

**Nose picking of, in children.** Intestinal parasites. (See Chapts. XVII.)

**Odor of Stools.** (See Chapt. XVII.)

**Pain,** (Chap. II.)

*acute cutting,* lancinating. Fissure, anal ulcer, foreign body, acute.

*burning.* Excoriations of circumanal skin. (See Chapts. VII, IX, XI, XII.)

*spasmodic.* Fissure, anal ulcer, hypertrophied anal papillæ.

*throbbing.* Abscess, perirectal infection. (Chap. VIII.)

- Pain, Absence of.** Other symptoms being present, suspect cancer.
- Painful Passage.** (See pain.) Any anal ulceration, fissure, internal hemorrhoids, foreign body, enlarged prostate, abscess, stricture, cancer (low) impingement of diseased pelvic organs.
- Protrusions.**—(Chapts. I, X, XI, XIV, XVI.)
- hard.* Fibrous polyp, cancer, thrombotic hemorrhoids.
  - nodular.* Fibrous polyp, cancer.
  - pedunculated.* Polypi (all varieties).
  - soft.* Internal hemorrhoids, enlarged papillæ, prolapse, myomatous polypi.
  - reducible.* All types of internal hemorrhoids, unless markedly thrombotic, polypi (with a snap) papillæ, prolapse of all degrees, unless strangulated.
  - non-reducible.* Cancer, prolapse with atonic sphincters, interno-external hemorrhoids (chronic), acute thrombotic hemorrhoids (external and marginal).
- Pus.** (See Discharge.) (Chapts. II, VII, VIII, IX.) Abscess, fistula, sinus, stricture, ulcer, fissure, cryptitis, foreign body, cancer.
- Restlessness at Night.** Intestinal parasites, pruritus ani.
- Skin Diseases.** (Chapt. VI.) Constipation, obstipation (acne, furunculosis). Pruritus ani (marginal eczema, intertrigo, ringworm, urticaria).
- Spasm of Sphincters.** (See Pain, spasmodic.)
- Swelling.** (See Elevations.)
- Stools.** (See Feces.)
- Tenderness.** (Chap. II.) Acute thrombotic hemorrhoids, fissure, anal ulcer, abscesses, acute internal hemorrhoids, anal cancer.
- Tumefaction.** Abscess, fistula, cancer.
- Vagina, Itching of.** (Chapt. VI.) Pruritus ani.
- Worms, in feces.** (See Chapt. XVII.)

[www.libtool.com.cn](http://www.libtool.com.cn)



INDEX OF AUTHORITIES QUOTED

A  
Adler, L. G., Jr., 118  
Albutt, 260-263  
Alexander of Tralles, 253  
Andrews, 235  
Aretæus, 253  
Ashton, 53  
Ayers, 254

B  
Ball, 22, 24, 28, 121, 124, 184  
Bassler, Arthur, 261  
Beck, Emil G., 57, 178  
Benivieni, Antonio, 253  
Beranger and Feraud, 278  
Boas, 326

C  
Casagrandi and Barbagalli, 264  
Celsus, 253  
Cetti, 334  
Corsons, E. A., 291  
Councilman, 267  
Councilman and Lafleur, 253, 263  
Craig, 272  
Cripps, 30, 117, 177  
Crisler, J. A., 293  
Crossen, 49  
Czernicki, 255

D  
Dixon, A. F., 22  
Dudley, 50

F  
Flexner, 253, 259  
Flexner and Strong, 259  
Franck, 209

G  
Galen, 253  
Gant, 30, 117, 118  
Griswold, V. M., 304

H  
Hanes, Granville S., 69, 286  
Harris, H. E., 253, 269, 285, 291  
Heller, 351  
Hensel, Weil and Jelliffe, 341, 352  
Hertzler, 304, 305  
Hertzler, Brewster and Rogers, 304  
Hippocrates, 253  
Hirsch, A., 254  
Hirst, 51  
Holl, 29

J  
Jelks, John L., 245, 249, 253, 275  
Jurgens, 263

K  
Kartulis, 253, 283  
Kelly, 68  
Kelsey, 206  
Krouse, Louis J., 125

L  
LeRoy, Louis, 288  
Leukart, 348, 356

M  
McDill, 253-284  
McGregor, 254  
MacMillan, 96  
Martin, Thomas Charles, 25, 62, 102  
Maurel, 334  
Meyer, 292  
Montgomery, 53  
Murray, D. H., 71, 113, 290

O  
Osler, 253, 254, 262, 285

P  
Pennington, J. R., 159

## S

Schmidt, 336  
 Schmidt and Strassburger, 339, 341  
 Shiga, 253, 259  
 Simon, 348, 357  
 Steele, 340  
 Sternberg, Surgeon General, 253  
 Stiles, 351  
 Strassburger, 340  
 Strauss, 334  
 Strong and Musgrave, 253, 267, 285

## T

Teachnor, Wells, 96  
 Terrell, E. H., 210  
 Thayer, 356  
 Thevenol, 257

Thibault, Henry, 304  
 Thomas, 253  
 Thompson, 29  
 Thompson and Ball, 27  
 Turek, 96  
 Tuttle, 33, 68, 117, 144, 245, 247, 249,  
 250, 253, 292

## V

Van Jaksch and Cagney, 335, 336, 341,  
 350, 353, 354, 355, 358

## W

Wallis, 119, 177, 238  
 Weir, Robert, 292  
 Woodward, 253, 255

## INDEX

### A

- Abscess, ischioanal, 54, 154  
  diagnosis of, 154  
  incision of, 153, 155  
  symptoms of, 154  
  treatment of, 155  
intermural, 150  
  diagnosis of, 152  
  proctoscopic view of, 151  
  treatment of, 152  
marginal, 147  
  examination of, 149  
  symptoms of, 148  
  treatment of, 149  
of the anorectal region, 144, 156  
  classification of, 144  
perianal, local anesthesia for, 315  
perineal, 145  
  diagnosis of, 147  
  treatment of, 147  
rectal, 329  
subtegumentary, 147  
  examination of, 149  
  symptoms of, 148  
  treatment of, 149  
tegumentary, 145  
  diagnosis of, 147  
  treatment of, 147  
*Acarus scabiei* as cause of pruritus ani, 111  
Adrenalin in treating hemorrhoids, 206  
Amebæ, examination of feces for, 265, 267  
Amebic dysentery, 262  
  character of feces in, 360  
  chronic, 290  
  secondary, 290  
*Amoeba coli mitis*, 264, 347  
  *dysentericæ*, 263  
  *histolytica*, 263  
Anal canal, anatomy of the, 21, 22, 23  
  fissure, 127, 141  
  cause of, 127  
  diagnosis of, 130  
  from tearing-down of crypt of Morgagni, 132  
Anal fissure—Cont'd.  
  local anesthesia for, 315  
  multiple, 131  
  treatment of, 133  
    author's operation in, 139  
    excision in, 139  
    ichthyol in, 133  
    incision in, 136  
    injection in, 135, 136  
    nitrate of silver in, 135  
    ointment in, 135  
    scarlet-red ointment in, 135  
    suppositories in, 135  
    surgical, 136  
  with sentinel pile, 129, 130, 132  
fistulæ, 157, 182, 329  
  blind external, (*see Sinus*)  
    treatment of, (*see Sinus*)  
  blind internal, (*see Sinus*)  
    diagnosis of, (*see Sinus*)  
    treatment of, (*see Sinus*)  
  direct complete, 159  
  excision of, 166  
  horseshoe, 158  
  in tuberculous patient, 181  
    diagnosis of, 182  
    symptoms of, 182  
    treatment of, 182  
  incision of, 163  
  injection of bismuth paste in, 178  
  ligature operations for, 170  
  local anesthesia for, 317  
  mucocutaneous, 177  
  multiple complete, 159  
  simple complete, 159  
    diagnosis of, 161  
    symptoms of, 159  
    treatment of, 163  
  submucous tract, 177  
  varieties of, 158  
papillæ, anatomy of, 23, 234  
  hypertrophy of, 228, 239  
  local anesthesia for, 317  
sinus, 159  
  external, 172  
  treatment, 172

- Anal sinus—Cont'd.  
 internal, 172  
   diagnosis, 174  
   treatment, 176  
 ulcer, 142  
   excision of, 142  
   after-treatment of, 143
- Anatomy, 21-33  
 of the anal canal, 21, 23  
   papillæ, 23  
 of the anus, 21  
 of the coccyx, 28, 30  
 of the columns of Morgagni, 26  
 of the crypts of Morgagni, 25  
 of the folds of Houston, 26  
 of the ischiorectal fossa, 30  
 of the ligaments, 29  
   anococcygeal, 29  
   lateral, 29  
 of the mesosigmoid, 31  
 of the muscles, bulbocavernosus, 22, 28  
   gluteus maximus, 28  
   iliococcygeus, 27  
   levator ani, 27, 28  
   pubococcygeus, 28  
   puborectalis, 22, 29  
   rectourethralis, 22, 27  
   sphincter recti, 29  
     external, 22, 23, 28  
     internal, 22, 26  
   transversus perinei, 28  
 of the rectal valves, 26, 100  
 of the rectum, 22, 24, 25  
   of the blood supply, 31  
   of the lymphatics, 32  
   of the nerve supply, 33  
   of the venous supply, 32  
 of the sacrum, 30  
 of the sigmoid colon, 31
- Anemia as symptom of rectal disease, 39
- Anesthesia, local, for operations on hemorrhoids, 211  
 technic of the use of, 302, 320
- Anesthetizing the sphincters, amount of distention necessary for, 312  
 point of puncture for, 310
- Anguillula intestinalis*, 356  
*stercoralis*, 356
- Animal parasites in feces, 347  
*Ankylostoma duodenale*, 351
- Anorectal region, abscess of the, 144-156
- Anoscope, fenestrated, author's 57  
 Kelly, 59  
 with oblique opening, author's, 57
- Anoscopy, 58  
 in diagnosis of hemorrhoids, 198  
 instruments for, 58  
 knee-shoulder position in, 54-56  
 posture and method in, 60
- Antiseptics in treatment of amebic dysentery, 282
- Anus, anatomy of the, 21  
 congenital defect or malformation of, examination for, 69  
 eversion of, 49, 50  
   vaginal, 69  
 imperforate, 66-69  
 quadrants of the, 311
- Apothecin for local anesthesia, 302
- Appendico-cecostomy for chronic amebic dysentery, 293
- Arteries of the rectum, 31  
*Ascaris lumbricoides*, 350
- Atresia ani vaginalis, complete, 67, 69  
 incomplete, 68, 69
- B**
- Bacillus coli communis*, 257  
*dysenteriae*, 259
- Backache, sacral, as symptom of rectal disease, 38
- Bacteria of symbiosis, 265  
*Balantidium coli*, 224, 348
- Ball's operation for pruritus ani, 121-125  
 Krouse's modification of, 125
- Beck's bismuth paste, injection of, 57, 178
- Benzidin test for occult blood in feces, 346
- Beta-eucain for local anesthesia, 302
- Bile in physiology of defecation, 78  
 pigment in feces, clinical significance of, 342
- Bilirubin in feces, clinical significance of, 343
- Bismuth meal, radiograph of, 80, 81  
 paste, injection of fistulous tracts with, 57, 178
- Bivalve rectal speculum, 196
- Blackwash for pruritus ani, 117
- Bleeding as symptom of hemorrhoids, 190  
 of rectal disease, 35, 344
- Blood in feces, clinical significance of, 35, 344  
 supply of the rectum, 31
- Bloodless operation for hemorrhoids, author's, 216
- Bothriocephalus latus*, 358

Bougie, Wales, 96, 319, 329  
 Bulbocavernosus muscle, anatomy of the, 22, 28

## C

Calomel for dysentery, 282  
 Cancer, differential diagnosis of hemorrhoids from, 230  
   of the rectum, 323  
   proctoscopic view of, 323  
   with multiple fistulæ, 325  
 Carboic acid for injection of hemorrhoids, 209  
   for pruritus ani, 117  
 Case reports of amebic dysentery, 273  
   with pellagra, 275, 276  
 Cauterization, linear, for prolapse of the rectum, 297  
   by actual cautery, 301  
   by nitric acid, 300  
 Cecum, ptosis of, 82, 83  
*Cercomonas intestinalis* in acute catarrhal dysentery, 257  
 Cestode worms, 356  
 Chemical examination of feces, 339  
 Chloretone for dysentery, 283  
 Cholera nostras, character of feces in, 360  
 Citrine ointment for pruritus ani, 117  
 Clamp and cautery operation for hemorrhoids, 224  
 Climate in etiology of dysentery, 254  
 Cocain for local anesthesia, 302  
   hydrochlorate in dysentery, 283  
 Coccyx, anatomy of the, 28, 30  
   examination of the, 51  
 Colitis, 253  
   mucocombranous, character of feces in, 360  
 Colon, atrophy of descending, 71  
   hypertrophy of, 74, 76  
   overdistention of, 72  
   sigmoid, anatomy of the, 31  
 Coloptosis, 77  
 Colostomy, 328  
 Columns of Morgagni, anatomy of, 26  
 Concretions, removal of, from rectum or sigmoid, 331  
 Congenital defects of anus or rectum, examination for, 69  
 Constipation, 70, 105  
   as symptom of rectal disease, 38  
   definition of, 71  
   diagnosis of, 85  
   proctoscopy in, 85, 86  
   radiography in, 86

Constipation—Cont'd.  
   etiologic factors in, 79  
     neglect as, 90  
     use of vegetables as, 90  
     use of water as, 90  
   treatment of, 90  
     author's method for, 96  
     diet in, 90  
     exercise in, 90  
     inflation of rectum in, 96  
     massage in, 94, 96  
     mechanical dilatation in, 96  
     nux vomica in, 99  
     ox gall in, 99  
     pancreatatin in, 99  
     petrolatum in, 99  
     pneumatic dilator for, 96  
     tamponing the rectum in, 96  
 Coprology, 333  
 Corrugator cutis ani muscle, 21  
 Cryptitis, 238  
   treatment of, 239  
 Crypts of Morgagni, anatomy of, 23  
   tearing-down of, cause of anal fissure, 132

D

Defecation, physiology of, 73  
 De Vilbiss rectal speculum, 152  
   spray tube, 241  
 Diagnosis of abscess, intermural, 152  
   marginal, 149  
   perineal, 145  
   rectal, 149  
   submucous, 151  
   subtegumentary, 149  
   tegumentary, 147  
 of anal fissure, 130  
   fistulæ, simple complete, 161  
   tuberculous, 182  
 of constipation, 85  
 of dysentery, acute catarrhal, 258  
   amebic, 278  
   diphtheritic, 258  
   sporadic bacillary, 257  
 of fecal impaction, 107  
 of hemorrhoids, 194  
   differential, 199  
 of hypertrophied anal papillæ, 235  
 of proctitis and sigmoiditis, acute, 241  
   chronic atrophic, 251  
   chronic hypertrophic, 245  
 of prolapse of the rectum, 296  
 of pruritus ani, 113  
 of rectal polypus, 228  
 of sinus, 174

- Diarrhea as symptom of rectal disease, 38  
 Diet in constipation, 90  
 in dysentery, 256  
 Digital examination, 45  
 finger cots for, 43, 45  
 in diagnosis of hemorrhoids, 197  
 lubricants for, 45  
 of coecyx, 51  
 position for, 46  
 correct, 47  
 incorrect, 46  
 lithotomy, 48-52  
 rectoabdominal, 52, 53  
 vaginorectal, 49  
 Dilatation, mechanical, for constipation, 96  
 Dilator, pneumatic, for constipation, 96  
 Diphtheritic dysentery, 258  
 enteritis, character of feces in, 359  
 Director, grooved, 167  
 Discharge as symptom of rectal disease, 37  
 Disturbances, general, as symptom of rectal disease, 39  
 urinary, as symptom of rectal disease, 39  
*Dochmius duodenalis*, 351  
 Douglas' pouch, 30  
 Dressing, rectal, 121  
 Dysenteric ulceration on valves of Houston, 270  
 Dysentery, 253, 293  
 acute catarrhal, 257  
 diagnosis of, 258  
 etiology of, 257  
 pathology of, 257  
 prognosis of, 258  
 symptoms of, 257  
 amebic, 262  
 case reports of, 273  
 character of feces in, 360  
 chronic, 290  
 appendico-cecostomy for, 290  
 complications of, 274  
 diagnosis of, 278  
 etiology of, 263  
 pathology of, 267  
 pellagra with, 276  
 prognosis of, 278  
 secondary, 290  
 sequelæ of, 274  
 symptoms of, 272  
 synonyms of, 262  
 treatment of, 278  
 antiseptics in, 282  
 dietetic, 279  
 Dysentery, amebic, treatment—Cont'd.  
 irrigation of colon in, 284  
 laxatives, in, 281  
 prophylactic, 278  
 remedial, 280  
 vaccines in, 289  
 character of feces in, 360  
 definition of, 253  
 diphtheritic, 258  
 complications of, 260  
 definition of, 258  
 diagnosis of, 259  
 etiology of, 259  
 pathology of, 259  
 secondary, 260  
 prognosis of, 260  
 symptoms of, 260  
 symptoms of, 259  
 etiology of, 254  
 climate in, 254  
 drinking water in, 256  
 foods in, 256  
 poor hygiene in, 254  
 race in, 254  
 season in, 254  
 sex in, 254  
 topography and condition of soil in, 255  
 flagellate, 260  
 etiology, 260  
 treatment, 261  
 transduodenal, 261  
 general considerations of, 253  
 geographical distribution of, 254  
 history of, 253  
 sporadic bacillary, 257  
 diagnosis of, 258  
 etiology of, 257  
 pathology of, 257  
 prognosis of, 258  
 symptoms of, 257  
 synonyms of, 253  
 E  
 Electric magnifying headlight, 43  
 Elevations as symptom of rectal disease, 37  
 Emetin in dysentery, 284  
 Enemata for pruritus ani, 118  
*Entamoeba histolytica*, 263, 266, 269  
 Enteritis, diphtheritic, character of feces in, 359  
 Erythema, treatment of, 116  
 Etiology of acute proctitis and sigmoiditis, 240  
 of constipation, 79

- Etiology—Cont'd.  
 of dysentery, 254  
   acute catarrhal, 257  
   amebic, 254  
   diphtheritic, 259  
   sporadic bacillary, 257  
 of prolapse of the rectum, 295  
 Eversion of anus, 48  
   vaginal, 49  
 Examination of feces, chemical, 339  
   clinical, 336  
   for amebæ, 267, 347  
   microscopic, 335  
 of hypertrophied anal papillæ, 235  
 of marginal abscess, 149  
 of patient, 40-69  
   anoscopy in, 58  
   digital, 45  
   electric headlight for, 43  
   eversion of anus in, 48  
   for congenital defects or malformation, 69  
   internal inspection in, 52  
   knee-shoulder position for, 54-56  
   lithotomy position for, 50  
   location of rooms for, 40  
   proctoscopy in, 60, 62  
   rectoabdominal, 52, 53  
   rooms and furniture in, 40  
   sigmoidoscopy in, 62-67  
   Sims' position for, 47  
   squatting position for, 52, 55  
   vaginorectal, 49  
 Exercise in constipation, 90  
 Excision of anal fissure, 139  
   fistula, 166  
   ulcer, 142  
   of hemorrhoids, 215  
   submucous, 224  
 External spineter muscle, anatomy of,  
   22, 23, 28

## F

- Fecal impaction, 106-109  
   cause of, 106  
   diagnosis of, 107  
   symptoms of, 106  
   treatment of, 108  
     author's massage bag in, 109  
     liquid petrolatum in, 108  
     peroxid of hydrogen in, 108  
 Feces, amount of, 334  
   and their clinical examination, 333-360  
   animal parasites in, 347  
   character of, in acute intestinal catarrh, 359  
 Feces, character of—Cont'd.  
   in amebic dysentery, 360  
   in chronic inflammation of intestines, 359  
   in cholera nostras, 360  
   in diphtheritic enteritis, 359  
   in dysentery, 360  
   in mucomembranous colitis, 360  
   color of, 334  
   consistency and form of, 334  
   duration of passage of, 333  
   examination of, chemical, 339  
     estimation of lost albumin residue in, 341  
     fermentation test in, 340  
     reaction in, 339  
     sublimate test in, 339  
   clinical, 336  
     test-diet in, 336  
   for amebæ, 267, 347  
   microscopic, 338  
   significance of tests in, 342  
     bile pigment, 342  
     bilirubin, 342  
     blood, 344  
     excess of connective tissue, 344  
     excess of undigested muscle-fiber, 344  
     fat, 343  
     gallstones, 346  
     hyaline cells, 342  
     mucus, 342  
     pathologic albumin fermentation, 342  
     pathologic carbohydrate fermentation, 342  
     pus, 342  
     remnants of meat, 344  
     semidigested cells, 342  
   general characteristics of, 333  
   macroscopic elements in, 335  
   microscopic elements in, 335  
   number of stools of, 333  
   odor of, 334  
 Fermentation apparatus, Steele's, 340  
   test for chemical examination of feces, 340  
 Finger cots for digital examination, 45, 146  
 Fissure, anal, 127-141  
   differential diagnosis of hemorrhoids from, 199  
   local anesthesia for, 315  
 Fistula, anal, 127-141, 331  
   blind external, (*see* Sinus)  
   internal, (*see* Sinus)  
   communicating with other organs, 331

- Fistula, anal—Cont'd.  
 complete, complicated, 164cn  
 direct, 159  
 multiple, 159  
 simple, 159  
 excision of, 166  
 in tuberculous patient, 181  
 incision of, 163  
 ligature operations for, 170  
 local anesthesia for, 317  
 mucocutaneous, 177  
 submucous tract, 177
- Folds of Houston, anatomy of, 26
- Foods in etiology of dysentery, 256
- Forceps, author's hemorrhoidal, 206  
 long aligator, 58  
 sharp-toothed or pronged, 140
- T-, 122
- Foreign body, history of swallowing,  
 calls for rectal examination, 39  
 local anesthesia in removal of, 318
- Formalin solutions for dysentery, 287
- Formalin-boric solutions for dysentery,  
 286
- Fossa, ischiorectal, anatomy of, 30
- Furniture for examination of patient,  
 40
- G
- Gallstones in feces, clinical significance  
 of, 346
- Gluteus maximus muscle, anatomy of  
 the, 28
- H
- Hanes position in sigmoidoscopy, 64, 65,  
 68
- Helminthiasis, 349
- Hemorrhage as symptom of hemor-  
 rhoids, 190  
 of rectal disease, 35  
 diseases causing, 35
- Hemorrhoidal forceps, author's, 206
- Hemorrhoids, 183-227, 313  
 acute thrombotic, local anesthesia  
 for, 314  
 removal of, 225  
 causes of, 187  
 diagnosis of, 194  
 anoscopy in, 198  
 differential, 199  
 from cancer, 200  
 from enlarged papillæ, 202  
 from fissure, 199  
 from polypli, 202  
 from prolapse, 203
- Hemorrhoids, diagnosis of, differential  
 —Cont'd.  
 from protrusions, 202  
 from ulcer, 200  
 from venereal warts, 203  
 digital examination, 197  
 proctoscopy in, 198  
 sigmoidoscopy in, 199
- external, 186  
 cutaneous, 189  
 distention of, with sterile water,  
 223  
 integumentary, 186  
 removal of, 226  
 local anesthesia for, 313  
 thrombotic, 186  
 varicose, 187
- internal, 187  
 anesthetized, 197, 202  
 capillary, 187  
 granular, 187  
 prolapsing, 193-195  
 varicose, 187
- interno-external, 184-186  
 injected for operation, 199, 201  
 prolapsing, distention necessary for  
 anesthesia in, 197
- symptoms of, 190  
 bleeding, 190  
 pain, 192  
 prolapse, 193
- treatment of, 205  
 adrenalin in, 206  
 injection, 207  
 carbolic acid for, 207  
 operative, 211  
 author's bloodless, 216-224  
 clamp and cauterly, 224  
 excision in, 215  
 other methods of, 225  
 submucous excision in, 224  
 Whitehead, 225  
 palliative, 174, 205  
 varieties of, 186  
 with pruritus ani, 114
- Hepatic abscess complicating amebic  
 dysentery, 274
- Herpes, treatment of, 116
- Hilton, white line of, 25
- Holland's modification of Weber's test  
 for occult blood in feces, 346
- Hookworms, 351, 352
- Hypertrophy of the anal papillæ, 228-  
 239  
 diagnosis of, 235  
 differentiated from polypus, 235  
 examination of, 235



Hypertrophy of anal papilla—Cont'd.  
 local anesthesia for, 317  
 proctoscopic view of, 236  
 symptoms of, 237  
 of the rectal valves, local anesthesia  
 for, 317

## I

Iehthiol for acute proctitis, 245  
 for anal fissure, 133  
 for chronic proctitis, 249  
 Idiopathic pruritus ani, 113  
 Iliococcygeus muscle, anatomy of, 27  
 Impaction, fecal, 106-109  
 Imperforate anus, 66-69  
 Incision of anal fissure, 136  
 fistula, 163  
 Inflammation of intestines, chronic,  
 character of feces in, 359  
 Inflation of rectum in constipation, 96  
 Injection of anal fissure, 135, 136  
 of bismuth paste, 57, 178  
 of local anesthetic, for operating on  
 hemorrhoids, 200, 203, 213  
 point of puncture for, 312, 313  
 treatment of hemorrhoids, 207  
 Instrument and dressing sterilizer, 41  
 sterilizer, 41  
 Intermural abscess, 150  
 Internal sphincter muscle, anatomy of,  
 22, 23, 26  
 Interno-external hemorrhoids, 184, 186  
 Intestinal catarrh, acute, character of  
 feces in, 359  
 ulcer, edge of, 269  
 Iodin for dysentery, 287  
 Ipecacuanha for dysentery, 283  
 Irrigations of colon for acute catarrhal  
 proctitis, 243  
 for amebic dysentery, 284  
 with Jelks' colon tube, 245  
 Ischiorectal abscess, 54, 154  
 fossa, anatomy of the, 30  
 Itching as symptom of rectal disease,  
 36  
 Itch-mite as cause of pruritus ani, 111

## J

Jelks' recurrent-flow soft-rubber colon  
 tube, 245, 286

## K

Kelly anoscope, 59  
 sigmoidoscope, 63, 68  
 Kerosene oil for dysentery, 286

Klunge's aloin test for occult blood in  
 feces, 346

Knee-elbow position, 56

Knee-shoulder position for diagnosis of  
 constipation, 86  
 for internal inspection, 54  
 for proctoscopic examination, 56,  
 59  
 for spraying rectum, 243, 245  
 in anoscopy, 56, 59

Krameria for chronic proctitis, 249  
 for spraying rectum, 245

Krouse's modification of Ball's opera-  
 tion for pruritus ani, 125

## L

Laxatives in treatment of amebic dys-  
 entery, 281

Levator ani muscle, anatomy of, 27-28

Ligaments, anatomy of the, 29  
 anococcygeal, 29  
 lateral, 29

Ligature carrier, author's blunt-  
 pointed, 209

author's rubber, 103, 104  
 operation for anal fistula, 170

Limitations of local anesthesia and  
 office treatment, 321-332

Linea dentata, 23, 25, 234

Lithotomy position for digital exami-  
 nation, 50, 51

for surgery of pruritus ani, 119

Liver in physiology of defecation, 78

Local anesthesia, amount of dilatation  
 of sphincter under, 312, 315

anesthetic agents for, 302

apothecin for, 302, 303

beta-eucain for, 302

cocain for, 302

contraindications to, 322

anal fistula, 329

cancer of the rectum, 323

hemorrhoids, 330

fistula communicating with other  
 organs, 331

prolapse of the rectum, 331

rectal abscesses, 329

removal of concretions, 331

stricture of the rectum, 328

ulceration of the bowel, 328

for anal fissure, 315

fistula, 317

for hemorrhoids, 211, 313

acute thrombotic, 314

external, 313

Local anesthesia—Cont'd.  
 for hypertrophied anal papillæ, 317  
   rectal valves, 317  
 for perianal abscess, 315  
 for removal of benign perianal  
   growths, 318  
   for sinus, 317  
   of foreign bodies, 318  
 in posterior internal proctotomy,  
   319  
 instruments for, 307  
 limitations of, 321  
 needle for, 308  
 quin and urea hydrochlorid for,  
   303-306  
 sterile water for, 306  
 technic of, 302-320  
   general, 308  
   in special cases, 313  
 Lubricants for digital examination, 45  
 Lymphatics of the rectum, 32

## M

Malformation of the anus or rectum,  
   examination for, 69  
 Marginal abscess, 147  
 Martin proctoscope, author's modifica-  
   tion of, 61  
 Massage bag, author's dilating, 95, 96,  
   97  
   in constipation, 96  
   rectal, author's method of, 96  
*Medio cannulata*, 357  
 Megacolon, 74, 76  
 Menstruation, crampy, painful, and  
   scanty, as symptom of rectal  
   disease, 39  
 Mesosigmoid, anatomy of the, 31  
 Microscopic elements in feces, 335  
   examination of feces, 335  
 Moresin, lesser sphincterian nerve of,  
   33  
 Morgagni, columns of, anatomy of, 26  
   crypts of, anatomy of, 23  
 Mucomembranous colitis, character of  
   feces in, 360  
 Mucus as symptom of rectal disease, 37  
   clinical significance of, in feces, 342  
 Muscle, bulbocavernosus, 22, 28  
   corrugator cutis ani, 21  
   gluteus maximus, 28  
   iliocecygeus, 27  
   levator ani, 27, 28  
   pubococygeus, 28  
   puborectalis, 22, 29

Muscle—Cont'd.  
 rectourethralis, 22, 27  
 sphincter recti, 29  
   external, 22, 23, 28  
   internal, 22, 26  
 transversus perenei, 28

## N

Nematodes, 349  
 Nerve supply of the rectum, 33  
 Nerves of the rectum, 33  
 Neuralgia of the rectum caused by hy-  
   pertrophied papillæ, 237  
 Nitrate of silver for anal fissure, 134  
   for pruritus ani, 118  
 Nitric acid cauterization for prolapse  
   of the rectum, 300  
 Nux vomica in treatment of constipa-  
   tion, 99

## O

Obstipation, 100-105  
   causes of, 73  
   definition of, 72  
   rectal valves in, 100  
 Odor of discharge as symptom of rec-  
   tal disease, 38  
   of feces, 334  
 Ointment for anal fissure, 134  
   for dysentery, 285  
   for pruritus ani, 116, 117  
 Operating-room, 40  
   -table, 42  
 Opium for dysentery, 282  
 Osgall in treatment of constipation, 99  
*Oxyuris vermicularis*, 350  
   as cause of pruritus ani, 111

## P

Pain as symptom of hemorrhoids, 192  
   of rectal disease, 34-39  
 Palpation of rectum, 52  
   rectoabdominal, 52  
 Pancreatin in treatment of constipa-  
   tion, 99  
 Papillæ, anal, anatomy of, 23  
   hypertrophy of, 228-239  
   differential diagnosis of, from  
   hemorrhoids, 202  
*Paramarcium coli*, 257, 265, 348  
 Parasites, animal, 347  
   *Amaba coli*, 347  
   *Anguillula intestinalis*, 356  
   *stercoralis*, 356  
   *Ankylostoma duodenale*, 351

## Parasites—Cont'd.

- Ascaris lumbricoides*, 349  
*Balantidium coli*, 348  
*Bothriocephalus latus*, 358  
cestode worms, 356  
*Dochmius duodenalis*, 351  
hookworm, 351, 352  
*Medio cannulata*, 357  
nematodes, 349  
*Oxyuris vermicularis*, 350  
pinworm, 350  
protozoa, 347  
round worms, 349  
seatworm, 350  
*Strongylus duodenalis*, 351  
*Tænia nana*, 358  
*saginata*, 357  
*solium*, 356  
tapeworms, 356-359  
threadworm, 350  
*Trichina spiralis*, 354  
*Trichina*, 355  
*Trichocephalus dispar*, 353-354  
*Uncinaria americana*, 352  
*duodenalis*, 351  
whip worm, 353  
worms, 349
- Pathology of dysentery, acute catarrhal, 257  
amebic, 267  
diphtheritic, 259  
sporadic bacillary, 257
- Patient, examination of the, 40-69  
*Pediculus pubis*, treatment of, 116  
Pellagra with amebic dysentery, 276
- Perianal abscess, local anesthesia for, 315
- Perineal abscess, 145
- Peristalsis intestinal, 73
- Peroxid of hydrogen in fecal impaction, 108  
injection of, for determining internal opening of fistula, 54
- Petrolatum liquid in treatment of constipation, 99  
in fecal impaction in hemorrhoids, 227
- Physiology of defecation, 73  
bile in, 78  
chemical reaction of stomach contents in, 75  
creation of gases in, 75  
liver in, 78  
movements of intestines in, 73  
of respiration in, 75  
peristaltic action in, 73  
stimulation by particles of food in, 75
- Pinworms, 350
- Polyposis multiple, 232, 233
- Polypus rectal, 228, 230  
differentiated from hemorrhoids, 202  
from hypertrophied papillæ, 235
- Position assumed by patients, in ano-rectal disease, 148  
exaggerated lithotomy, in sigmoidoscopy, 62  
inverted or Hanes, in sigmoidoscopy, 64, 65, 68  
knee-elbow, 56  
knee-shoulder, for anoscopy, 56, 59, 60  
for internal inspection, 56-59, 60  
for proctoscopic examination, 53, 56  
for spraying rectum, 243, 292  
lateral, for digital examination, 46, 47  
for surgery of pruritus ani, 119  
left lateral, for external inspection, 44  
lithotomy, for digital examination, 62  
for surgery of pruritus ani, 119  
of patient for introduction of colon tube, 289  
Sims', for digital examination, 46, 47  
for dilating rectum, 97  
for external inspection, 44
- Pouch, Douglas', 30  
rectovesical, 30
- Probe, silver, 58
- Proctitis and sigmoiditis, 240-252  
acute, 240  
catarrhal, 242  
diagnosis of, 241  
etiology of, 240  
symptoms of, 241  
treatment of, 242  
chronic, 247  
atrophic, 249  
symptoms of, 250  
treatment of, 251  
hypertrophic, 247  
diagnosis of, 248  
symptoms of, 248  
treatment of, 248
- Proctoscope, author's four-inch operating, 101  
author's modification of Martin, 61
- Proctoscopic view of cancer of the rectum, 323  
of hypertrophied anal papillæ, 236  
of submucous abscess, 151

- Proctoscopy, 59-66  
 in diagnosis of hemorrhoids, 198  
 technic of, 62  
 without instruments, 60
- Proctotomy, posterior, internal, for annular stricture, 319
- Prolapse as symptom of hemorrhoids, 193  
 differential diagnosis of hemorrhoids from, 303  
 of the rectum, 331  
 in children, 294-301  
 cauterization of, 300, 301  
 concealed, 295, 296, 299  
 diagnosis of, 296  
 etiology of, 295  
 symptoms of, 296  
 treatment of, 297
- Protozoa, 347
- Protrusions as symptom of rectal disease, 37  
 differential diagnosis of hemorrhoids from, 202
- Pruritus ani, 110-126  
 after-treatment of, 126  
 caused by hypertrophied papillæ, 237  
 causes of, 110  
 characteristic cracking of, 111  
 itching of, 115  
 diagnosis of, 113  
 idiopathic, 113  
 treatment of, 115  
 author's operation in, 122  
 Ball's operation in, 121  
 Krouse's modification of, 125  
 blackwash in, 117  
 carbolic acid in, 117  
 dusting powder in, 116  
 enemata in, 118  
 lotions in, 117  
 mechanical vibrator in, 118  
 nitrate of silver in, 118  
 ointment in, 116, 117  
 citrine, 118  
 scarlet-red, 118  
 prescriptions for, 116, 117  
 removal of kite-shaped flap of skin in, 120  
*streptococcus fecalis* in, 113, 115  
 surgical measures in, 119  
 with hemorrhoids, 114
- Ptosis of cecum, 82, 83
- Pubococcygeus muscle, anatomy of, 28
- Puborectalis muscle, anatomy of, 27-29
- Pus in feces, clinical significance of, 344
- Q
- Quadrants of anus, 311
- Quinin and urea hydrochlorid for local anesthesia, 303-307  
 for injection method, 210
- R
- Race in etiology of dysentery, 254
- Radiograph of bismuth meal, 80, 81
- Radiography, in diagnosis of constipation, 73
- Rectal abscesses, 329  
 dressing, 121  
 massage, author's method of, 96  
 polypus, 228, 230  
 diagnosis of, 228  
 fibroid, 228  
 granular, 228  
 symptoms of, 230  
 treatment of, 229  
 retractor, modified from Sims' speculum, 209  
 speculum, bivalve, 196  
 De Vilbiss, 152  
 spray tube, author's, 242  
 valves, 100  
 anatomy of the, 26, 100  
 valvotomy, author's operation, 104
- Rectoabdominal examination, 52, 53  
 palpation, 52
- Rectourethralis muscle, anatomy of the, 22, 27
- Rectovesical pouch, 30
- Rectum, anatomy of the, 22, 24, 25  
 arteries of the, 31  
 blood supply of the, 31  
 cancer of the, 323  
 proctoscopic view of, 323  
 congenital defect or malformation of, examination for, 69  
 inflation of the, in constipation, 96  
 lymphatics of the, 32  
 nerve supply of the, 33  
 nerves of the, 33  
 neuralgia of the, caused by hypertrophied papillæ, 237  
 palpation of the, 52  
 prolapse of the, 331  
 in children, 294-301  
 relations of the, 30  
 stricture of the, 319, 328  
 symptoms which should call attention to the, 34-39  
 tamponing the, in constipation, 96  
 ulcer of the, 244

Rectum—Cont'd.  
 veins of the, 32  
 venous supply of the, 32  
 Restlessness in children as symptom of  
 rectal disease, 39  
 Retractor, rectal, 209  
 Ringworm as cause of pruritus ani, 111  
 treatment of, 117  
 Rooms for examination of the patient,  
 40  
 Round worms, 349

## S

Sacral backache as symptom of rectal  
 disease, 38  
 Sacrum, anatomy of the, 30  
 Scabies, treatment of, 116  
 Scarlet-red ointment for anal fissure,  
 135, 138  
 for pruritus ani, 118  
 Scissors, author's angular rectal, 101  
 curved on the flat, sharp-pointed, 122  
 Season in etiology of dysentery, 254  
 Seatworms, 350  
 Sentinel pile, 130  
 with anal fissure, 129  
 Sex in etiology of dysentery, 254  
 Sigmoid colon, anatomy of the, 31  
 Sigmoiditis, 240-252  
 acute, 242  
 chronic atrophic, 247  
 hypertrophic, 247  
 Sigmoidoscope, Kelly, 63, 68  
 with author's tilting obturator, 63,  
 68  
 Sigmoidoscopy, 67-69  
 exaggerated lithotomy position in, 62,  
 69  
 in diagnosis of hemorrhoids, 199  
 inverted or Hanes position in, 64, 65,  
 68  
 Sims position for digital examination,  
 46, 47  
 for dilating rectum, 97  
 for external inspection, 44  
 for internal inspection of anal  
 canal, 58, 60  
 Soil in etiology of dysentery, 255  
 Spasm as symptom of rectal disease, 35  
 Speculum, bivalve rectal, 196  
 De Vilbiss rectal, 152  
 Sphincter recti muscle, anatomy of the,  
 29  
 tight contracted, 237  
 Spray tube, author's rectal, 242  
 De Vilbiss, 241  
 Squatting position for diagnosis, 52, 55

Staphylococcus cause of tegumentary  
 abscess, 147  
 Sterilizer, instrument and dressing, 41  
 Stomach contents, chemical reaction of,  
 75  
 Stools, altered, as symptom of rectal  
 disease, 38  
*Streptococcus faecalis* cause of pruritus  
 ani, 113, 115  
 Stricture of the rectum, 319, 328  
 posterior internal proctotomy for, 313  
*Strongylus duodenalis*, 351  
 Sublimate test in chemical examination  
 of feces, 339  
 Submucous abscess, 150  
 excision of hemorrhoids, 224  
 tract, 177  
 Subtegmentary abscess, 147  
 Suppository for anal fissure, 135  
 for dysentery, 283, 285  
 for hemorrhoids, 220  
 Surgical measures for pruritus ani, 119  
 treatment of anal fissure, 136  
 Symbiosis, bacteria of, 265  
 Symptoms which should call attention  
 to the rectum, 34-39  
 Syringe, all-glass hypodermic, 307  
 all-metal, 307  
 all-rubber bulb, 53, 55

## T

T-forceps, 122  
*Tenia nana*, 358  
*saginata*, 357  
*solium*, 356  
 Tamponing the rectum in constipation,  
 96  
 Tapeworms, 356-359  
 Tegumentary abscess, 145  
 Tenderness as symptom of rectal dis-  
 ease, 35  
 Test, fermentation, in examination of  
 feces, 340  
 for estimation of lost albumin resi-  
 due in feces, 341  
 for occult blood in feces, benzidin,  
 346  
 Holland's 346  
 Klunge's aloin, 346  
 Weber's, 345  
 sublimate, in examination of feces,  
 339  
 Test-diet in clinical examination of fe-  
 ces, 336  
 Treadworms, 350  
 as cause of pruritus ani, 111  
 treatment for, 117

Thymol for dysentery, 287  
 Toilet rooms, provision for, 83, 84  
 Tract, submucous, 177  
 Treatment of abscess, intermural, 152  
   marginal, 149  
   perineal, 145  
   rectal, 149  
   submucous, 152  
   subtegumentary, 149  
   tegumentary, 145  
 of amebic dysentery, 278  
 of anal fissure, 133  
   fistula, 163  
     simple complete, 163  
     tuberculous, 182  
 of constipation, 90  
 of cryptitis, 239  
 of erythema, 116  
 of fecal impaction, 108  
 of hemorrhoids, 205  
 of herpes, 116  
 of *Pediculus pubis*, 116  
 of proctitis and sigmoiditis, acute,  
   242  
   chronic atrophic, 251  
     hypertrophic, 248  
 of prolapse of the rectum, 297  
 of pruritus ani, 115  
 of rectal polypi, 230  
 of ringworm, 117  
 of scabies, 116  
 of threadworm, 117  
*Trichina*, 355  
   *spiralis*, 354  
*Trichocephalus dispar*, 353, 354  
*Trichomonas intestinalis*, 257  
*Trichophyton* as cause of pruritus ani,  
   111  
   treatment of, 117  
 Tuberculous anal fistula, 181

## U

Ulcer, anal, 142  
 differential diagnosis of hemorrhoids  
 from, 200

Ulcer—Cont'd.  
 intestinal edge of, 269  
 of the rectum, 244  
 Ulceration of the bowel, 328  
*Uncinaria americana*, 352  
   *duodenalis*, 351  
 Urinary disturbances as symptom of  
 rectal disease, 39

## V

Vaginorectal examination, 49  
 Valves of Houston, dysenteric ulcera-  
 tion on, 270  
   rectal, 100  
     anatomy of the, 26, 100  
 Valvotomy, 102  
   needle, 101  
   rectal, author's operation for, 104  
 Veins of the rectum, 31  
 Venous supply of the rectum, 32  
 Vibrator, mechanical, for constipation,  
   94  
   for dilatation of sphincter, 312,  
   314  
   for pruritus ani, 118

## W

Wales bougie, 96, 319, 329  
 Warts, differential diagnosis of hem-  
 orrhoids from, 203  
 Water, drinking, in etiology of dysen-  
 tery, 256  
 Weber test for occult blood in feces,  
   345  
 Whip worm, 353  
 White line of Hilton, 25  
 Whitehead operation for hemorrhoids,  
   225  
 Worms in feces, 349  
   cestode, 359  
   nematode, 349

[www.libtool.com.cn](http://www.libtool.com.cn)

[www.libtool.com.cn](http://www.libtool.com.cn)



[www.libtool.com.cn](http://www.libtool.com.cn)

[www.libtool.com.cn](http://www.libtool.com.cn)

[www.libtool.com.cn](http://www.libtool.com.cn)

[www.libtool.com.cn](http://www.libtool.com.cn)

[www.libtool.com.cn](http://www.libtool.com.cn)

[www.libtool.com.cn](http://www.libtool.com.cn)

COUNTWAY LIBRARY



HC 2CCN Z

[www.libtool.com.cn](http://www.libtool.com.cn)

7

